

Case Report

Down syndrome Associated with Epstein's Anomaly and Pulmonary Hypertension in a 2.5 Months Infant: a Case Report Study

Asadollah Tanasan¹, Farshad Rostampour^{2, 4}, Ahmad Jamei Khosroshahy³, Milad Sanginabadi⁴, Amin Falahi⁵

1. Department of Pediatric, School of Medicine, Hamadan University of Medical Sciences and Health Services, Hamadan, Iran.
2. General Practitioner, Sirvan Health Network, Ilam University of Medical Sciences and Health Services, Ilam, Iran
3. Department of Pediatric, School of Medicine, Tabriz University of Medical Sciences and Health Services, Tabriz, Iran
4. Student Research Committee (SRC), School of Medicine, Hamadan University of Medical Sciences and Health Services, Hamadan, Iran
5. Doctor of Dental Surgery, Sirvan Health Network, Ilam University of Medical Sciences and Health Services, Ilam, Iran

Correspondence to: Farshad Rostampour, General Practitioner, Sirvan Health Network, Ilam University of Medical Sciences and Health Services, Ilam, Iran. Tel: +989183403303. E-mail addresses: Farshad.rostampour@yahoo.com

Abstract

In children with Down syndrome (DS) there is higher chance for concomitant congenital heart defects and organic disorders. However Epstein's anomaly is a rare association of DS. We report a 2.5 months DS boy that referred to our hospital with tachypnea. In echocardiography the septal leaflet displaced downwardly toward the apex about 8.2 mm and displacement index was 27.3 mm/m², Tricuspid regurgitation (TR) was moderate (VC=5.5mm) with 70 mmHg gradient also an ASD with bidirectional shunt and a membranous VSD were seen. catheterisation and angiography was done, pulmonary arterial pressure was subsystemic and a 2.5 mm size PDA was seen, in the levophase a medium size VSD was seen. The patient is under follow up with lanoxin, captopril and lasix now. As mentioned earlier Epstein's anomaly is rare and its prevalence is about 0.5% of CHDs although 50% of patients with DS have CHD but its association with Epstein's anomaly is very rare.

Key words: Down syndrome, Epstein anomaly, Pulmonary Hypertension, Congenital Heart Defect, Tricuspid regurgitation

Introduction:

Down syndrome (DS) is one of the most chromosomal abnormalities in human [1]. There is an extremely high incidence of congenital anomalies such as important cardiac and gastrointestinal malformations in DS patients [1, 2]. Epstein's anomaly for the first time defined by Wilhelm Epstein at 1866 [3]. This anomaly is the most congenital tricuspid valve anomalies nevertheless its prevalence is about 0.5% of congenital heart defects (CHDs) that is very low [4]. The prevalence of this anomaly is about 5.2 cases per 100,000 live births. In the Epstein's anomaly the tricuspid valve morphology is greatly variable and the leaflets involved with various severity [5]. Superior area of the right ventricle (RV) functionally becomes a part of the RA that is termed atrialization of RV. Due to the structural changes that accrued this region (the part of RV that becomes RA) becomes thin and it's prone for aneurismal dilatation. However according to our literature reviews, we have no report of Down syndrome associated with Epstein's anomaly and pulmonary hypertension.

Case presentation

A 2.5 months old infant with Down syndrome, admitted to Be'sat hospital of Hamadan because of tachypnea (Respiratory rate=66/min). In the physical examination the respiratory rate was 67 breath/min, he wasn't cyanotic and the heart rate was 145 beat/min, S1 was normal and the P2 part of S2 was load and a holosystolic murmur with III/VI intensity in LLSB was detected that was associated with multiple click, also thrill was felt in LLSB. In the chest X-Ray (CXR) cardiomegaly especially in RV and the vascular marking pattern was obvious.

The ECG rhythm was normal and right ventricular hypertrophy was seen, and also there weren't any signs of WPW syndrome. In echocardiography the septal leaflet displaced downwardly toward the apex about 8.2 mm and displacement index was 27.3 mm/m², Tricuspid regurgitation (TR) was moderate (VC=5.5mm) with 70 mmHg gradient also an atrial septal defect (ASD) with bidirectional shunt and a membranous ventricular septal defect (VSD) were seen, The size of VSD was 7mm. because displacement index upper than 8 mm/m² is characteristic for ebstein's anomaly and most probable diagnosis for this patient was ebstein's anomaly (figure 1). For evaluation of pulmonary artery hypertension and possibility of patent ductus arteriosus (PDA) catheterization and angiography was done, pulmonary arterial pressure was subsystemic and a 2.5 mm size PDA was seen, in the levophase a medium size VSD was seen (figure 2). The patient is under follow up with lanoxin, captopril and Lasix now.

Discussion

As mentioned earlier epstein's anomaly was rare and its prevalence is about 0.5% of CHDs [4] although 40-50% of patients with down syndrome have CHD [6] but it's association with epstein's anomaly is very rare and best of our knowledge very few case reported previously [7-10]

RVH and RAH secondary to the pulmonary hypertension commonly is a late finding in the VSD and PDA and usually not happened in a 2.5 months old infant, it can be concluded that this signs is secondary to the patient's epstein's anomaly.

Association of epstein's anomaly, ASD, PFO, VSD and pulmonary atresia aren't an unusual finding but

Association of epstein's anomaly and pulmonary hypertension is a very rare finding and usually occurred in adult secondary to left ventricle disorders Association of epstein's anomaly, down syndrome, PDA, VSD, ASD and pulmonary artery hypertension in a 2.5 months infant is an extremely rare finding.

References:

1. De Rubens Figueroa J, Del Pozza M B, Pablos HJL. Heart malformations in children with down syndrome. *Rev Esp Cardiol*. 2003; 56(4):894-9.
2. Tanasan A, Rostampour F, Tanasn P. Massive Pericardial Effusion in Down syndrome with Supravalvar Pulmonary Stenosis Associated to Left Pulmonary Collapse. *GMJ* 2014; 3(1): 61-65.
3. Ebstein W. Uber einen sehr seltenen fall von insuffizienz der valvula tricuspidalis, bedingt durch eine angeborene hochgradige missbildung derselben. *Arch Anat Physiol* 1866; 33:238-254.
4. Epstein ML. Congenital stenosis and insufficiency of the tricuspid valve. In: Emmanuilides A, Riemens chneider G. Moss and Adams. Heart disease in infants children and Adolescents. Maryland: Williams & wilkins; 1995; 907-21.
5. Anderson KR, Zuberbuhler JR, Anderson RH, et al. Morphologic spectrum of Ebstein anomaly of the heart. *Mayo Clin Proc* 1979; 54:174-180.
6. Neill CA, Zuckerberg AL. Syndromes and congenital heart defects. In: Nichols DG. Critical heart disease in infants and children. St. Louis: Mosby-year book 1995; 987-1012.
7. Venturi E, Musiaio L, Strazzeri R, Baroni F. Ebstein's tricuspid anomaly and Down's syndrome. A clinical case report. *Recenti Prog Med* 1992; 83: 556-558.
8. Bauk L, Espinola-Zavaleta N, Munoz-Castellanos L. Ebstein's malformation in the setting of Down's syndrome. *Cardiol Young* 2003; 13:370-2.
9. Siehr SL, Punnett R, Priest JR, Lowenthal A. Ebstein anomaly and Trisomy 21: A rare association. *Ann Pediatr Card* 2014; 7:67-9.
10. Leite Mde F, Gianisella RB, Zielinsky P. Intrauterine detection of ebstein's anomaly and Down's syndrome. Prenatal diagnosis of a rare combination. *Arq Bras Cardiol* 2004; 82:390-5.

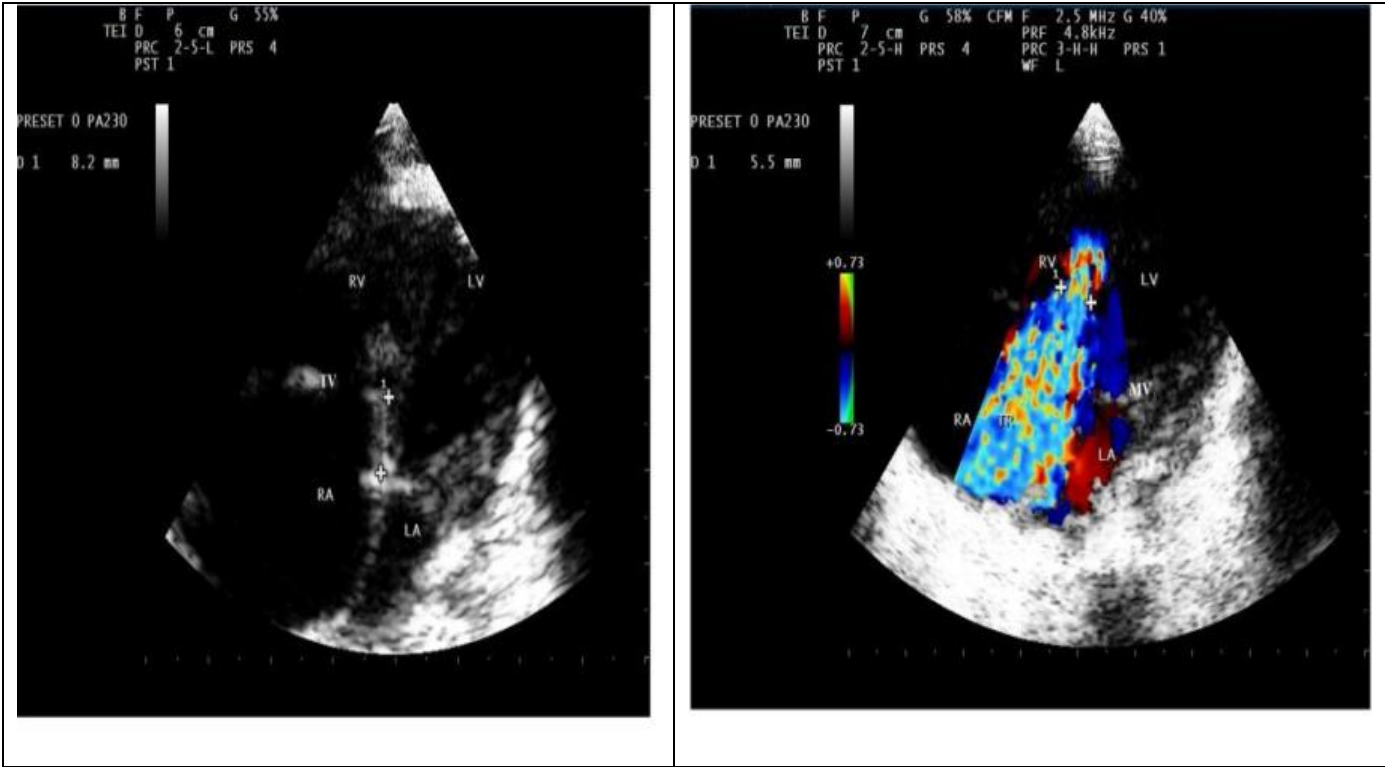

Figure 1: echocardiographic finding (ASD, VSD, TR)

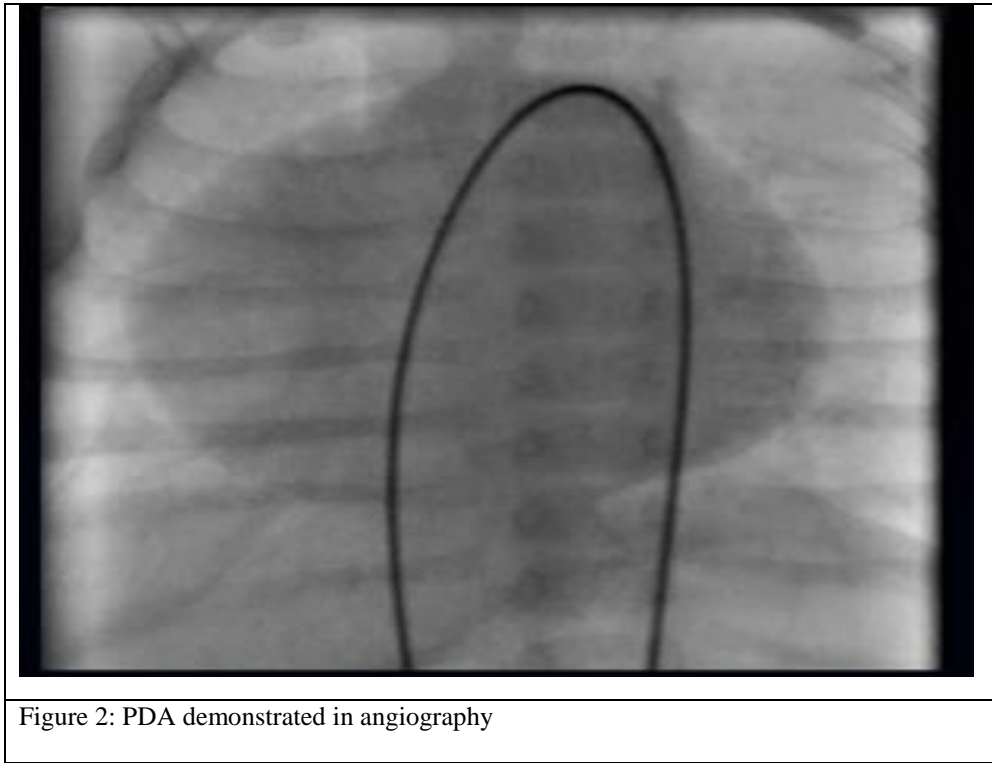


Figure 2: PDA demonstrated in angiophy