

Original article

The Effect of MMP9 in the Development of Colorectal Cancer Progression

Anahita Nosrati¹, Omid Emadian², Mahdi Jafarinejad³¹Department of pathology, Gastrointestinal cancer research center, Imam Khomeini hospital, Mazandaran university of medical sciences,Iran.²Department of pathology, Imam Khomeini hospital, Mazandaran university of medical sciences,Iran .³Department of pathology, Imam Khomeini hospital, Mazandaran university of medical sciences,Iran.

Corresponding author: Omid Emadian

Email: oemadian@yahoo.com

Abstract

Objective: Matrix metalloprotease 9 (MMP9) is a group of proteolytic enzymes that mediate breaking down the components of the fibrillar extracellular matrix during tissue rearrangement, physical, biological and pathological conditions such as growth, wound healing, inflammation and tumor progression. To investigate the association of these markers with clinicopathologic features and survival of colorectal cancers (CRC), we examined its expression in colorectal cancer tissues.

Methods: The expression of MMP9 in 91 paraffin embedded specimens of colorectal cancer and normal tissue adjacent to the tumor of patients referred to Imam Khomeini Hospital in Sari, Iran was studied immunohistochemically and the relationship between the clinical data and pathological features were considered, too.

Result: 91 samples (43 women and 48 men) were studied including 6 mucinous carcinoma and 88 adenocarcinoma. MMP9 expression was negative and positive in 31 and 66 cases respectively. Expression of MMP9 in normal tissue around the tumor was 5.5%. Our finding revealed that the MMP9 correlated significantly with tumor depth (p-value: 0.033) and metastasis to lymph node (p-value: 0.007). The association of MMP9 expression with the other clinicopathologic factors was not statistically significant (p-value > 0.05).

Conclusion: According to this study, the relationship between the expression of MMP9 with lymph node metastasis and depth of tumor was observed. To confirm the result, vast studies with more samples and also with the other matrix metalloproteinase proteases is recommended.

Keywords: Colorectal Cancer, MMP9, Clinicopathology, Immunohistochemistry, Metastasis.

Introduction

Impetigo is an infectious skin disease caused by *S. Coloretal cancer* is the third most common malignancy and the second leading cause of cancer death, with an incidence of approximately half a million deaths annually and five hundred thousand deaths annually in the world (1, 2). Colorectal cancer is the third most common cancer in men and the fourth most common cancer in women in Iran (with the exception of skin cancer) that its prevalence is rising nowadays (3). The pathogenesis of colorectal cancer is the result of complex steps and neoplastic changes in the normal cell, tissue invasion and finally metastasis. In all tissues, extracellular matrix creates structural and biochemical networks to support the cells, and so tumor cells react with the extracellular matrix. This structural rearrangement reaction is important for them to migrate from the original site. Extracellular

matrix proteins play an important role in cell proliferation and migration and protease inhibitors control the matrix rearrangement (4). In recent years, many studies have been done on the invasion ability of tumor cell using various markers including stem cells and lately cellular matrix components (5).

Matrix metalloproteinase is a family of extracellular matrix that is dependent to zinc to break endopeptidase and show similar activation mechanisms and performance (6). On the basis of substrate specificity and amino acid sequences, they are divided into four categories: Collagenase (MMP1,3,8), Gelatinase (MMP2,9), Stromelysin (MMP3,7,10,12), and membrane-type metalloprotease (MT-MMP1,5) (7-9). Among these, MMP9 (or gelatinase B) is an important member of Gelatinase, the gene of it is located on

chromosome 20q11.2-q13.1. MMP9 plays a role in several cancer progressions by degrading collagen type 4 in basement membrane and facilitating tumor progression in extracellular matrix(10). Although the main substrate of MMP9 is collagen 4 and gelatin, it has proteolytic activity against the other components of the extracellular matrix.

Several studies showed a correlation between increased expression of MMP9 and poor prognosis in CRC patients (11-14). In addition, others recognized high levels of MMP9 expression in cancer cells compared to normal epithelial cells (12, 13). Some studies showed correlation of MMP9 expression in CRC with depth of invasion, lymph node metastasis and low grade tumors (13,15). It has been claimed that MMP9 was significantly associated with histological grade and tumor location(16-18). The relationship between this marker and stage in addition to metastasis has also been reported (12, 16,19-22). It seemed that there is association of MMP9 with clinicopathologic characteristics including age(17) and survival(14).

5-year survival of patients with colorectal cancer has been stated 50% independent of the type of treatment(23) and this reaches below 10% in the case of metastases (24-26). Thus, regarding the high incidence of colorectal cancer in North Iran and the rising trend through the world besides a high occurrence in young people (27), this study aimed to identify the role of a new marker as MMP9 in colorectal cancer by immunohistochemical method and determine the relationship between MMP9 and clinicopathological parameters and also the survival rate.

Methods

Patients and samples:

In this study, paraffin blocks of 91 patients with colorectal cancer diagnosed between years 1382 to 1392 at Imam Khomeini hospital in Sari, Iran were used. The clinicopathologic data was gathered by using hematoxylin and eosin slides in archives, pathology and medical records and patients contact, too. Clinico-pathological parameters included age, gender, tumor type, depth of invasion, lymph node metastasis, distant metastasis (including liver), stage, grade, vascular and lymphatic invasions, type of treatment, recurrence, survival (based on month) and recurrence (alive/dead due to cancer or its complications). Patients who had received chemotherapy before surgery or had a history of familial polyposis or IBD had been removed. All samples were fixed in 10% formalin and blocked in paraffin. All sections including tumor and non-tumoral tissue were examined and selected for IHC stain.

IHC staining procedure:

First of all, paraffin was removed by immersing in xylene and secondly, the tissues were dehydrated by descending concentrations of ethanol, and were put in buffer TRIS-EDTA (PH=9). Then, they were transferred into microwave to boil buffer. After that, microwave power was reduced to 40% and after 15 minutes the tissues were removed and placed at room temperature for 15 minutes. After washing, murine monoclonal antibody kit with dilution of 1:100 was used and incubated overnight at room temperature (Abcam anti-MMP9 100 µg). Afterwards, the tissues were treated with peroxidase for 30 minutes and then chromogenic reaction was carried out. Breast cancer tissue (figure-1) and tumors were covered only by buffer (figure-2) were selected as MMP9 positive and negative control tissues respectively. The prepared slides were looked by two independent pathologists in blinded fashion under Nockon light microscopy at magnification of 40x.

Evaluation of MMP9 staining

Cancer cells showed diffuse cytoplasmic staining with no stromal expression. Accordingly, the intensity and percentage of cytoplasmic staining were determined by 4-grade system respectively(28) ;(0): negative (no detectable) (figure-1), (1): weak, (2): moderate, (3): strong, and zero: 0%, one: 1 to 5 %, 2: 6 to 75 %, 3: 76 to 100%. The sums of total scores of staining intensity and percentage were considered as final score so that scores equal or more than 3 were considered as positive results (Figure 3). Marker was positive in 60% of tumors.

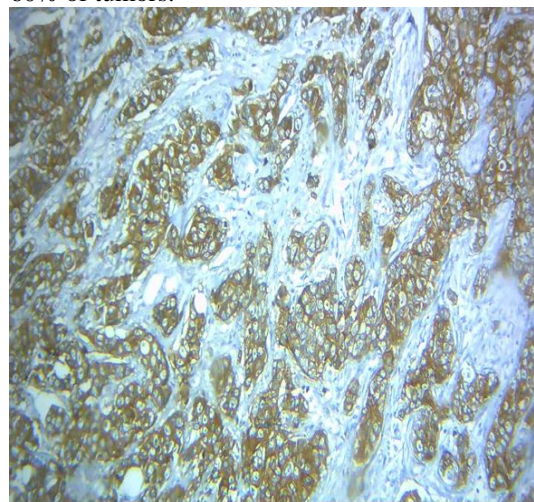


Figure 1. - Immunohistochemistry. Breast infiltrative carcinoma as positive control (power 10X)

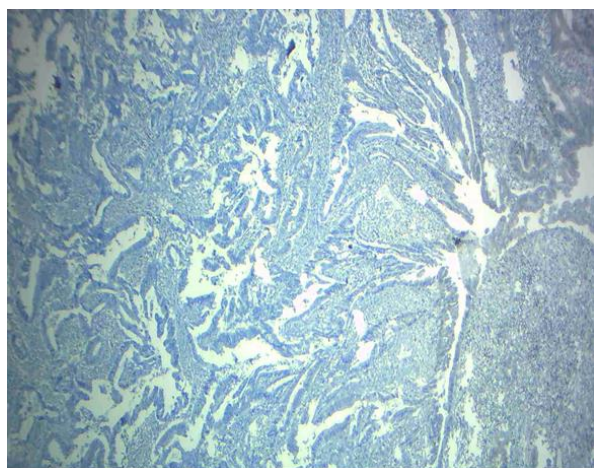


Figure 2. Immunohistochemistry. Colorectal cancer as negative control (power 10X)

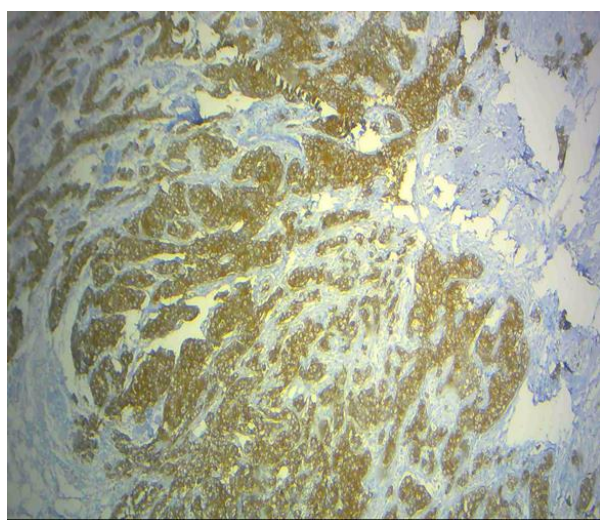


Figure 3 Immunohistochemistry. Colorectal cancer, positive in cytoplasm of tumoral cells(power 10x)

Statistical Analysis

The results of immunohistochemistry and patients' data were analyzed by SPSS software (IBM SPSS statistics 20.0.1). The relationship between staining and clinicopathological data were assessed by the χ^2 test or Fisher's exact test. The Mann-Whitney U-test was applied to determine the correlation between age and the immunoreactivity. Analysis of variance was only used for deriving the mean values of each individual stratum. Univariate survival analysis for the outcome measure was based on Kaplan-Meier method. To assess the value of MMP-9 as an independent predictor, a multivariate survival analysis was done using the Cox proportional hazards regression model controlling for the confounding of MMP- 9 by the following variables. P- value below 0.05 was considered significant.

Results

In 91 patients, mean age was 56.96 ± 12.65 years, range 37 to 86 years. The mean age of patients with adenocarcinoma and mucinous carcinoma was 65.37 ± 13.8 and 52.33 ± 10.7 years old respectively. MMP9 expression was positive in 60 cases and negative in 31. The mean age of negative and positive patients in terms of marker was 63.24 ± 12 and 63.24 ± 16.3 years respectively. 48 patients were male and 43 were female. The mean age of men and women was 63.48 ± 15.62 and 65.71 ± 12.11 years respectively. The type of tumor in 85 patients was adenocarcinomas (88% in men and 100% in woman) and in 6 patients was mucinous carcinoma (1 in men and 5 in women).

MMP9 expression in terms of male gender distribution was negative and positive in 34.9 % and 68.1% , of patients respectively and there was not a significant difference between the two groups. ($p = 0.87$). MMP9 expression in adjacent normal tissue was found in 5.5% of cases which was not associated with clinical factors.

In regard to tumor pathology, there was not a significant relationship between the nature of the tumor and MMP9 ($p = 0.35$) in a way 35.3 % and 64.7 % of MMP9 negative and positive groups were adenocarcinoma respectively. The mean tumor size of patients was $4/75 \pm 1/94$ cm with range of 1-10 cm. Statistically tumor size was not significantly correlated with this marker expression. 63 cases (69.2 %) were well, 23 cases (25.3 %) moderately, and 5 cases were (5.5 %) poorly differentiated.

MMP9 in 21 negative and 42 positive cases were well differentiated (33.3 % against 66.7 %), but according to Fisher's exact test, there was no significant difference between the two groups ($p = 0.06$). Of all 91 patients who studied 48 (49.5%) had lymph node metastasis in whom according to Chi-square and Fisher exact tests, lymph node metastasis was correlated significantly with marker expression ($P = 0.007$). As to distant metastases, 14 people (15.4%) had metastasis in various organs, but no significance association was found ($p > 0.05$). The mean survival time after diagnosis was $33/83 \pm 24/66$ month with the range of 1- 120 month. The mean survival time in patients was $40/56 \pm 30$ month and according to the T-test the difference between the two groups was not significant ($p = 0.13$). Based on our data, 11 patients had recurrence after initial treatment. Recurrence was occurred in 45/5 % of MMP9-negative and 65% of MMP9-positive patients, but there was not a significant difference between these two groups. ($P = 0.39$)

Table-1. Statistical results of immunohistochemical assay

	n	MMP9		P
		+	-	
Total	91	60	31	
Gender				0.87
Men	43	28	15	
Women	48	32	16	
Age				121
<55				
>55				
Tumor location				0.16
Right colon	41	24	17	
Left colon	31	19	12	
Rectum	19	17	2	
Histologic grade				0.06
Well differentiated	63	42	21	
Moderately differentiated	23	17	6	
Poorly diffiferentiated	5	1	4	
Depth of invasion				0.03
T1	1	1	0	
T2	16	6	10	
T3	27	17	10	
T4	47	3		
Lymph node status				0.007
N0	46			
N1	45			
Distant metastasis				0.9
M0	77			
M1	14			

Discussion

Colorectal cancer is one of the most malignant neoplasm. The tumor pathogenesis is multistep and multi-factorial which is along with abnormalities of tumor suppressor genes and oncogenes, DNA repair genes and cell-cell adhesion factors(29). Cell proliferation and metastasis in colorectal cancer are the most important prognostic features. Metastasis is an elaborated process involving the sequential steps behind the invasion, such as seeding, colonization, migration and proliferation of vascular bed in distant sites(30-33). MMP9 plays an essential role in metastasis of CRC by influencing ECM(34). That is the most complex

member in matrix metalloproteinase family which has the ability to break down elastin, laminin and collagen type 4 and 5(31, 32). The MMP9 expression and association with clinicopathological factors have been conducted by several studies in different countries in which some contradictory results have been obtained. Given the important role of proteases in the spread of cancer cells and metastasis, one of the most important matrix metalloproteinase as MMP9 was examined by immunohistochemistry. Abdelbaset et al. studied MMP9 by IHC on colorectal cancer and showed the relationship of MMP9 with the tumor grade and

its location but with no other factors (17), while Dake chu et al. showed that there was no relationship with MMP9 and tumor grade and location (12). Moreover, Nina et al. did not observe any correlation between MMP9 and tumor differentiation and location (18). Accordingly, in this study, no correlation with MMP9 and tumor grade and location was found. In this way, some researchers, such as BoYang, Dake chu and Abdelbaset et al. revealed no relationship with age, gender and type of tumor (12, 16, 17) which were similar to our results. Literally, this could be due to the limited number of studies of this marker, less evaluated colorectal cases in the studies; besides, being as a brand new marker in this context. Dake chu et al. displayed the association of MMP9 expression with lymph node metastasis and depth of invasion in colon cancer (12), similarly Bo Yang et al. found this association with lymph node involvement (16), while this association was not found in Abdelbaset (17) and this study (p -value < 0.05).

Conclusion

Colorectal cancer is the third most common malignancy worldwide and its incidence is rising. In this study by examining IHC on a metalloprotease, found that positive cytoplasmic expression of MMP9 and depth of tumor invasion is associated with lymph node involvement but there is no association with other clinicopathologic factors for colorectal cancer. This may indicate that further studies on matrix metalloproteinase inhibitors can help to improve the prognosis of patients with colorectal cancer and to obtain valuable information.

Acknowledgements

We thank Dr Kamyar Khodadadi for excellent technical assistance

References

1. Parkin DM, Bray F, Ferlay J, Pisani P. Global cancer statistics, 2002. *CA Cancer J Clin.* 2005;55(2):74-108.
2. Van Der Jagt MF, Wobbes T, Strobbe LJ, Sweep FC, Span PN. Metalloproteinases and their regulators in colorectal cancer. *J Surg Oncol.* 2010;106:259-269.
3. Radmard AR. Five common cancers in Iran. *Arch Iran Med.* 2010;13(2):143-6.
4. Hua H, Li M, Luo T, Yin Y, Jiang Y. Matrix metalloproteinases in tumorigenesis: an evolving paradigm. *Cell Mol Life Sci.* 2011;68(23):3853-68.
5. Nosrati A, Naghshvar F, Torabizadeh Z, Salehi F. Correlation of Colorectal cancer stem cell marker CD24 expression with clinicopathologic features

and survival of patients with colorectal cancer. *Govaresh.* 2014;19(2):86-94.

6. Vu TH, Werb Z. Matrix metalloproteinases: effectors of development and normal physiology. *Genes Dev.* 2000;14(17):2123-33.

7. Meijer MJ, Mieremet-Ooms MA, van der Zon AM, van Duijn W, van Hogezaand RA, Sier CF, et al. Increased mucosal matrix metalloproteinase-1, -2, -3 and -9 activity in patients with inflammatory bowel disease and the relation with Crohn's disease phenotype. *Dig Liver Dis.* 2007;39(8):733-9.

8. Sutnar A, Pesta M, Liska V, Treska V, Skalicky T, Kormunda S, et al. Clinical relevance of the expression of mRNA of MMP-7, MMP-9, TIMP-1, TIMP-2 and CEA tissue samples from colorectal liver metastases. *Tumour biology: the journal of the International Society for Oncodevelopmental Biology and Medicine.* 2006;28(5):247-52.

9. GUZIŃSKA-USTYMOWICZ K. MMP-9 and cathepsin B expression in tumor budding as an indicator of a more aggressive phenotype of colorectal cancer (CRC). *Anticancer Res.* 2006;26(2B):1589-94.

10. Groblewska M, Siewko M, Mroczko B, Szmitkowski M. The role of matrix metalloproteinases (MMPs) and their inhibitors (TIMPs) in the development of esophageal cancer. *Folia Histochem Cytobiol.* 2012;50(1):12-9.

11. Langenskiöld M, Holmdahl L, Falk P, Ivarsson M-L. Increased plasma MMP-2 protein expression in lymph node-positive patients with colorectal cancer. *Int J Colorectal Dis.* 2005;20(3):245-52.

12. Chu D, Zhao Z, Zhou Y, Li Y, Li J, Zheng J, et al. Matrix metalloproteinase-9 is associated with relapse and prognosis of patients with colorectal cancer. *Ann Surg Oncol.* 2012;19(1):318-25.

13. Koskensalo S, Hagström J, Linder N, Lundin M, Sorsa T, Louhimo J, et al. Lack of MMP-9 expression is a marker for poor prognosis in Dukes' B colorectal cancer. *BMC Clin Pathol.* 2012;12(1):24.

14. Li C-Y, Yuan P, Lin S-S, Song C-F, Guan W-Y, Yuan L, et al. Matrix metalloproteinase 9 expression and prognosis in colorectal cancer: a meta-analysis. *Tumor Biology.* 2013;34(2):735-41.

15. Jensen SA, Vainer B, Bartels A, Brünner N, Sørensen JB. Expression of matrix metalloproteinase 9 (MMP-9) and tissue inhibitor of metalloproteinases 1 (TIMP-1) by colorectal cancer cells and adjacent stroma cells—associations with histopathology and patients outcome. *Eur J Cancer.* 2010;46(18):3233-42.

16. Yang B, Tang F, Zhang B, Zhao Y, Feng J, Rao Z. Matrix metalloproteinase-9 overexpression is closely related to poor prognosis in patients with colon cancer. *World J Surg Oncol.* 2014;12(1):24.

17. Buhmeida A, Bendardaf R, Hilska M, Collan Y, Laato M, Syrjänen S, et al. Prognostic significance

of matrix metalloproteinase-9 (MMP-9) in stage II colorectal carcinoma. *J Gastrointest Cancer*. 2009;40(3-4):91-7.

18.Liabakk N-B, Talbot I, Smith RA, Wilkinson K, Balkwill F. Matrix metalloprotease 2 (MMP-2) and matrix metalloprotease 9 (MMP-9) type IV collagenases in colorectal cancer. *Cancer Res*. 1996;56(1):190-6.

19.Loesch M, Zhi HY, Hou SW, Qi XM, Li RS, Basir Z, et al. p38gamma MAPK cooperates with c-Jun in trans-activating matrix metalloproteinase 9. *J Biol Chem*. 2010;285(20):15149-58.

20.Papageorgis P, Cheng K, Ozturk S, Gong Y, Lambert AW, Abdolmaleky HM, et al. Smad4 inactivation promotes malignancy and drug resistance of colon cancer. *Cancer Res*. 2011;71(3):998-1008.

21.Zhang B, Halder SK, Kashikar ND, Cho YJ, Datta A, Gorden DL, et al. Antimetastatic role of Smad4 signaling in colorectal cancer. *Gastroenterology*. 2010;138(3):969-978.

22.Garg P, Sarma D, Jeppsson S, Patel NR, Gewirtz AT, Merlin D, et al. Matrix metalloproteinase-9 functions as a tumor suppressor in colitis-associated cancer. *Cancer Res*. 2010;70(2):792-801.

23.Choi D, Lee HW, Hur KY, Kim JJ, Park G-S, Jang S-H, et al. Cancer stem cell markers CD133 and CD24 correlate with invasiveness and differentiation in colorectal adenocarcinoma. *World journal of gastroenterology: WJG*. 2009;15(18):2258.

24.THIS I, editor *Surgical Pathology of Carcinoma of the Colon and Rectum*. Semin Oncol; 1991.

25.Mohiuddin M, Ahmed MM, editors. *Critical issues in the evolving management of rectal cancer*. Semin Oncol; 1997.

26.Oladipo O, Conlon S, O'Grady A, Purcell C, Wilson C, Maxwell P, et al. The expression and prognostic impact of CXC-chemokines in stage II and III colorectal cancer epithelial and stromal tissue. *Br J Cancer*. 2011;104(3):480-7.

27.Kemper K. *Molecular identification and targeting of colorectal cancer stem cells* 2012.

28.Curran S, Dundas SR, Buxton J, Leeman MF, Ramsay R, Murray GI. Matrix metalloproteinase/tissue inhibitors of matrix metalloproteinase phenotype identifies poor prognosis colorectal cancers. *Clin Cancer Res*. 2004;10(24):8229-34.

29.Jenab M, Bueno-de-Mesquita HB, Ferrari P, van Duynhoven FJ, Norat T, Pischon T, et al. Association between pre-diagnostic circulating vitamin D concentration and risk of colorectal cancer in European populations: a nested case-control study. *BMJ*. 2010;340.

30.Fidler IJ. The pathogenesis of cancer metastasis: the 'seed and soil' hypothesis revisited. *Nature Reviews Cancer*. 2003;3(6):453-8.

31.Westermarck J, KÄHÄRI V-M. Regulation of matrix metalloproteinase expression in tumor invasion. *The FASEB Journal*. 1999;13(8):781-92.

32.Murphy G, Docherty AJ. The matrix metalloproteinases and their inhibitors. *Am J Respir Cell Mol Biol*. 1992;7:120.-

33.Wilson PM, LaBonte MJ, Lenz H-J. Molecular markers in the treatment of metastatic colorectal cancer. *The Cancer Journal*. 2010;16(3):262-72.

34.Gorden DL, Fingleton B, Crawford HC, Jansen DE, Lepage M, Matrisian LM. Resident stromal cell-derived MMP-9 promotes the growth of colorectal metastases in the liver microenvironment. *Int J Cancer*. 2007;121(3):495-500.