

## Case Report

# Aggressive Ulcerating Squamous Cell Carcinoma Arising In Old Burn Scar: A Case Report

Masoud Shayesteh Azar 1, Fatemeh Montazer 2\*, Mohammad Hossein Karimi Nasab 3, Abolfazl Kazemi 4, Soroush Felezi 5, Hamed JafarPour 6

1. Associated Professor of orthopedic surgery, Orthopedic Research center, Mazandaran university of medical science, Sari, Iran
2. Assistant Professor, Dermatopathologist. Department of Pathology, Orthopedic Research center, Mazandaran University of Medical Science , Sari, Iran
3. Associated professor of orthopedic surgery, Orthopedic Research center, Mazandaran university of medical science, Sari, Iran
4. Orthopedic resident, Orthopedic Research center, Mazandaran university of medical science, Sari, Iran
5. Pathology Resident, department of pathology, Mazandaran university of medical science, sari, Iran
6. Medical student, Student research committee, Mazandaran university of medical science ,sari, Iran

\*corresponding author: Assistant Professor, Dermatopathologist. Department of Pathology, Orthopedic Research center, Mazandaran University of Medical Science , Sari, Iran

Email: [Saa\\_montazer@yahoo.com](mailto:Saa_montazer@yahoo.com)

## Abstract

Carcinoma arising in posttraumatic ulcers and chronic wounds was first described by Jean- Nicholas Marjolin in 1828. Marjolin's ulcers are malignant neoplasms that originate from chronic irritation such as burn wounds, venous stasis ulcers, traumatic wounds, osteomyelitis, fistulas, and lacerations, Burn wounds are the most frequent underlying etiology of Marjolin's ulcers. We reported Marjolin's ulcer that arising from very old burn scar in foot.

**Keywords:** Carcinoma, Marjolin's ulcer, scar

## Introduction

Carcinoma arising in posttraumatic ulcers and chronic wounds was first described by Jean- Nicholas marjolin in 1828.(1, 2)Marjolin's ulcers are malignant neoplasms that originate from chronic irritation such as burn wounds, venous stasis ulcers,(3) traumatic wounds(4), osteomyelitis(5) fistulas(6), and lacerations(2)Burn wounds are the most frequent underlying etiology of marjolin's ulcers.(1)Incidence of marjolin's ulcers ranges from 0.23 – 1.7 % . (7, 8) also neoplastic degeneration of burn-scar has

been reported at 0.77 – 2.0 %.(9)In different study; male to female ratio of 3:1 and 1.6:1 was reported .(10, 11)

Three important recurrence predictors is 1.diagnosis ages 2.nodal status 3.reconstruction with a flap or graft.(10) reducing the risk of malignancy by treatment with skin grafting. As a general rule, any ulcer persisting for >3 months should be biopsied.(12)

In this article, we reported Marjolin's ulcer that arising from very old burn scar in foot.

### Case report

52-year-old women who suffered a burn injury in so years prior to admission. This resulted in an extensive soft tissue injury to her right lower leg leading to amputation of all her right toes (Figure 1). Four months earlier she developed an ulceration mass on burn scar associated with discharge and pain. Over this period, the lesion had rapidly progressing increase in size and drainage (Figure 2, 3).

On physical examination, she was found to have a huge cream-brown cauliflower-like and ulcerative mass measuring 21\*21\*4 cm, with foul smell and involving almost the whole circumference of the leg. Evaluation of right inguinal lymph nodes showed an ulcerative focus as well. Another examination was normal.

Supplementary treatments including neoadjuvant chemoradiotherapy was not performed for the patient. A below knee amputation was done because of the size and location of the tumor as well as the need for rehabilitation.

History of the specimen revealed a moderate differentiated squamous cell carcinoma with invasion the beneath bony structure. There was no vascular, lymphatic and perineural invasion and surgical margins were clear (Figure 4). About one week after surgical process, biopsy from the inguinal lesion was taken in which tumoral involvement the same as previously described was confirmed. In biopsy free zone of tumor.

### Discussion

Scar burn that turned out to be squamous cell carcinoma, which is called Marjolin's ulcer. But many authors are the opinion that the remaining scar from any type of injury that malignant transformation is called Marjolin's ulcer.(10)However, it may also happen in normal skin.(12)Most commonly found in the lower extremity.(11)Most of these lesions features include foul smells, increased drainage, mass exophytic, increasing pain, unresponsiveness to therapy, lymphadenopathy, bleeding, bone destruction.(7) the age range of these malignancies, according to reports published so far is from 8 to 63 years.(9) Ghalambor et al, reported mean age of 45 years.(13) In Metwally et al study in 2016 the male: female ratio for MU was 1.6:1 .(10) .the first-line definitive treatment should include wide local excision with free margins of 2 to 4 cm, which, in the foot and ankle, could often necessitate a more proximal amputation. Amputation should be reserved for MU infiltrating bone or major vessels. Seeding of tumor cells into vessels and lymph nodes may result in metastasis, so electrocautery during excision may help prevention of metastatic spread.(10, 14-16)

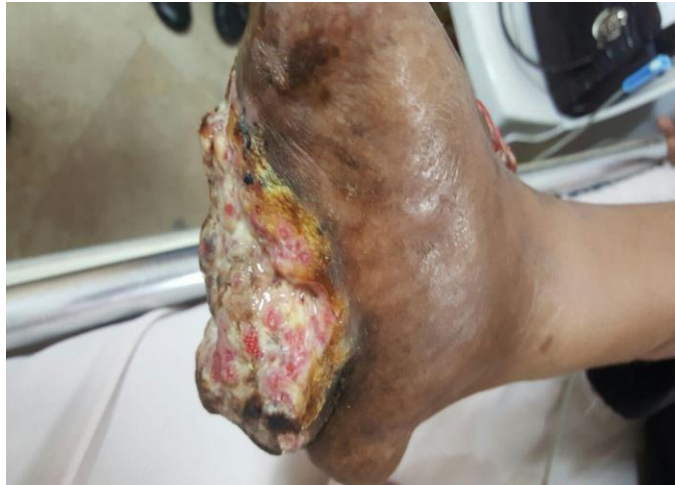### Conflicts of Interest

“The author(s) declare(s) that there is no conflict of interest regarding the publication of this paper.”

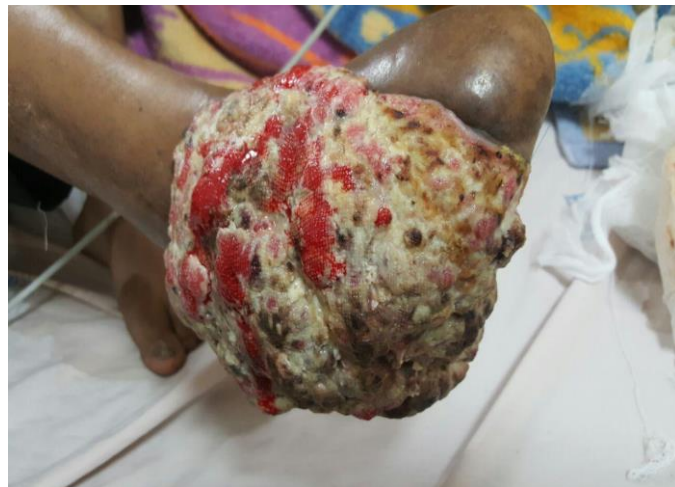### References

1. Kerr-Valentic MA, Samimi K, Rohlen BH, Agarwal JP, Rockwell WB. Marjolin's ulcer: modern analysis of an ancient problem. *Plastic and reconstructive surgery*. 2009;123(1):184-91.

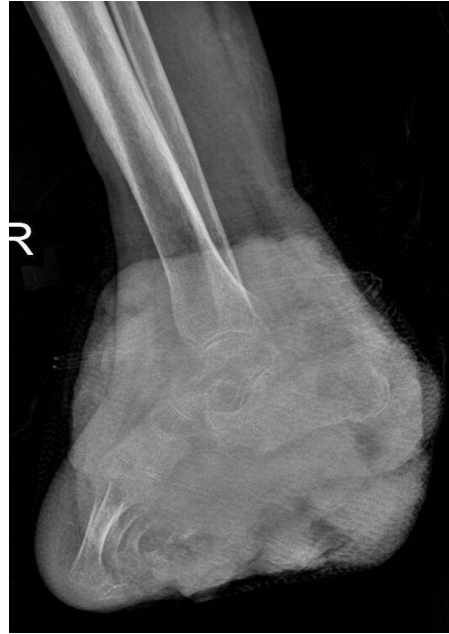2. Barr LH, Menard JW. Marjolin's ulcer The LSU experience. *Cancer*. 1983;52(1):173-5.
3. LFB M, NCN N, PINTO L, Pinto LW, JFN R, CE C. Malignancy in chronic ulcers and scars of the leg (Marjolin's ulcer): a study of 21 patients. 2001.
4. Ozek C, Celik N, Bilkay U, Akalin T, Erdem O, Cagdas A. Marjolin's ulcer of the scalp: report of 5 cases and review of the literature. *The Journal of burn care & rehabilitation*. 2001;22(1):65-9.
5. Bauer T, David T, Rimareix F, Lortat-Jacob A. Marjolin's ulcer in chronic osteomyelitis: seven cases and a review of the literature. 2008.
6. Bauk VOZ, Assunção AM, Domingues RF, Fernandes NC, Maya TC, Maceira JP. Marjolin's ulcer: a twelve-case report. *Anais Brasileiros de Dermatologia*. 2006;81(4):355-8.
7. Ogawa B, Chen M, Margolis J, Schiller F, Schnall S. Marjolin's ulcer arising at the elbow: a case report and literature review. *Hand*. 2006;1(2):89-93.
8. Patel NM, Weiner SD, Senior M. Squamous cell carcinoma arising from chronic osteomyelitis of the patella. *Orthopedics*. 2002;25(3):334-6.
9. Al-Zacko SM. Malignancy in chronic burn scar: A 20 year experience in Mosul-Iraq. *Burns : journal of the International Society for Burn Injuries*. 2013;39(7):1488-91.
10. Metwally IH, Roshdy A, Saleh SS, Ezzat M. Epidemiology and predictors of recurrence of Marjolin's ulcer: experience from Mansoura University. *Annals of the Royal College of Surgeons of England*. 2016:1-5.
11. Pekarek B, Buck S, Osher L. A comprehensive review on marjolin's ulcers: Diagnosis and treatment. *The Journal of the American College of Certified Wound Specialists*. 2011;3(3):60-4.
12. Aydoğdu E, Yildirim S, Aköz T. Is surgery an effective and adequate treatment in advanced Marjolin's ulcer? *Burns : journal of the International Society for Burn Injuries*. 2005;31(4):421-31.
13. Ghalambor A. Marjolin ulcer: How much of safety margin needs resection along marjolin ulcer squamous cell carcinoma in recurrence cases. *Pakistan Journal of Medical Sciences*. 2007;23(3):394.
14. Altunay I, Cerman AA, Sakiz D, Ates B. Marjolin's Ulcer Presenting with In-Transit Metastases: A Case Report and Literature Review. *Annals of dermatology*. 2015;27(4):442-5.
15. Asuquo M, Ugare G, Ebughe G, Jibril P. Marjolin's ulcer: the importance of surgical management of chronic cutaneous ulcers. *International journal of dermatology*. 2007;46(s2):29-32.
16. Sharma A, Schwartz RA, Swan KG. Marjolin's warty ulcer. *Journal of surgical oncology*. 2011;103(2):193-5.



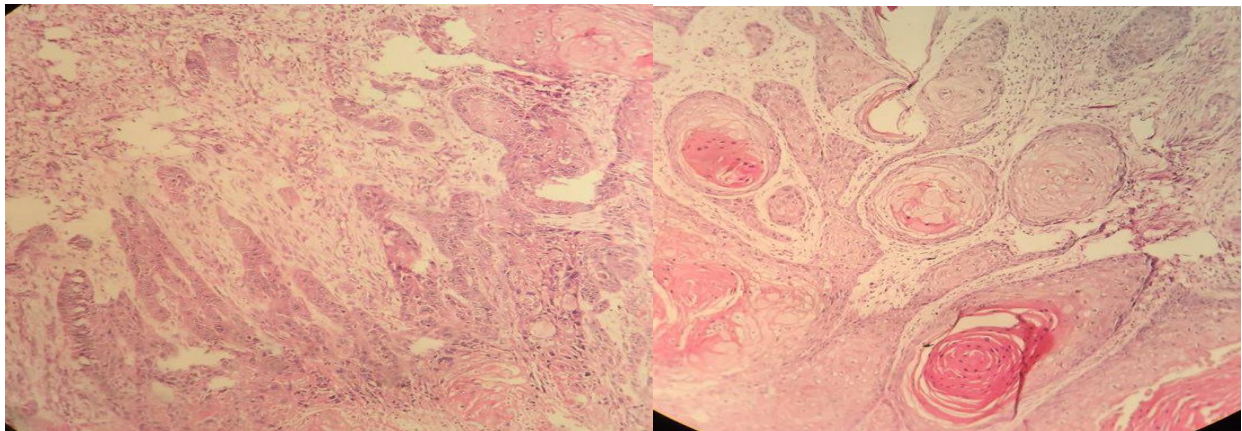
(Figure 1) : huge cream-brown cauliflower- like mass



(Figure 2) : huge cream-brown cauliflower- like and ulcerative mass



(Figure 3)



(Figure 4): Nest of atypical squamous cells with frequent keratinization x40