

Case Report

Prenatal Diagnosis of Tetralogy of Fallot in a Fetus with Maternal Gestational Diabetes Mellitus, a Case Report

Alireza Golbabaeei¹, Ehsan Aghaei Moghaddam², Mohammad Taghi Majnoun², Ali Mirabi^{3*}

1. Department of Pediatrics cardiology, Faculty of Medicine, Mazandaran University of Medical Sciences, Sari, Iran

2. Department of Pediatrics cardiology, Faculty of Medicine, Tehran University of Medical Sciences, Tehran, Iran

3. Medical Student, Student Research Committee, Mazandaran University of Medical Sciences, Sari, Iran.

*correspondence: **Ali Mirabi**, Medical Student, Student Research Committee, Mazandaran University of Medical Sciences, Sari, Iran. alimir7292@gmail.com

Abstract:

Gestational diabetes mellitus (GDM) is a teratogenic condition for the fetus. Congenital malformations among the newborns of diabetic mothers is 5-times greater than general population. Tetralogy of fallot is a common form of congenital heart defect. We would like to report a diagnosed case of fetal tetralogy of fallot based on findings including a ventricular septal defect (VSD), aortic valve overriding, bidirectional shunt via VSD in aortic long axis view, in addition to anomalies on the three-vessel view with small pulmonic annulus in a high risk mother with GDM with a gestational age of 19 weeks. It appears that although the risk of fetal cardiac malformations may be highest in women with GDM, all pregnancies of pre-gestational diabetes and GDM are at increased risk, given this, regular fetal echocardiographies should be consider in women with GDM.

Key words: Tetralogy of Fallot, prenatal diagnosis, fetal echocardiography, gestational diabetes mellitus

Introduction:

Prevalence of gestational diabetes mellitus (GDM) in Iranian pregnant women is approximately 4.5%. Given that DGM is a teratogenic condition for the fetus, the incidence rate of congenital malformations among the newborns of diabetic mothers is 5-times greater than general population (1, 2).

Cardiac heart defects are one of the most common types of fetal malformations. The incidence of congenital heart disease (CHD)

is about 6-12 per 1000 live births witch are associated with high mortality and morbidity (3, 4). Tetralogy of fallot (TOF) is the most common form of cyanotic CHD, accounting for approximately 10% of congenital cardiac anomalies with a combination of right ventricular outflow tract obstruction, a malalignment ventricular septal defect (VSD), an overriding aorta, and right ventricular hypertrophy (RVH). In utero, RVH usually does not develop because of patency of the foramen ovale and ductus

arteriosus, which release the pressure load in the right ventricle. However the clinical presentation varies depending on the degree of right ventricular outflow obstruction (5-8).

The etiology of CHDs seems to be multifactorial with both genetic and environmental factors. Increased risk of congenital heart defects is reported in offspring of women with GDM (9-11). We would like to report on a case of Tetralogy of fallot in a Fetus with maternal gestational diabetes mellitus.

Case Presentation:

A 30 year-old woman referred for routine echocardiography evaluations by gynecologist consult. The fetal echocardiography performed by pediatric cardiologist at 19 weeks' gestational age (second-trimester). The echocardiographic images were obtained in the four-chamber view, aortic long axis view and three-vessel view (3VV) to evaluate the size, position, alignment, axis of the fetal heart, atria, ventricles, atrioventricular (AV) valves, number of the main pulmonary artery, ascending aorta and superior vena cava. Normal right ventricle chamber (figure 1-a), ventricular septal defect and Aorta overriding (figure 1-b), bidirectional shunt via VSD (figure 1-c) and relatively small pulmonic annulus (figure 1-d) were detected in fetus echocardiography. According to the above abnormalities a diagnosis of TOF was suggested. The termination of pregnancy was considered.

Discussion:

Early detection of fetuses with congenital cardiac defects is important. The diagnosis of prenatally Tetralogy of Fallot is vital for obstetrical management of the disease (5, 12).

The occurrence of fetal CHD in pregnant women with GDM is less well documented. GDM is defined as any degree of glucose intolerance with onset or first diagnosis during pregnancy (13).

Diabetes mellitus (DM) is one of the most common maternal conditions. Approximately 1% of all pregnant woman are considered to have pre-gestational DM. Overall, there is nearly a 5-fold (3%–5%) increase in CHD compared with the general population in women with pre-gestational DM (14, 15). Diabetes is multifactorial in which physiological, environmental and genetic factors play roles to develop GDM, age higher than 25 years, previous GDM, family history of DM, maternal body mass index more than 30, previous infant with a birth weight more than 4kg and pregnancy-related hypertension are some risk factors in developing GDM (16).

Poorly controlled diabetic pregnancy is associated with the severity of cardiac malformation in fetuses of GDM. Studies have shown that maternal diabetes may cause abnormalities in the formation of fetal heart structures, including defects of the cardiac outflow and anomalies related to the heart valves (17, 18). Women who regularly have prenatal follow-up and monitoring and keep their blood glucose levels within normal range early in pregnancy would have much lower risk of having a baby with CHD.

The four-chamber view is a practical screening tool for examining the fetal heart, as it provides information about CHDs. Using the 3VV, it is possible to image the MPA, AA, and SVC and to determine the relationship between them (19, 20).

TOF consists of a ventricular septal defect, stenosis of the infundibulum of the pulmonary artery, aortic valve overriding the interventricular septum, and hypertrophy of the right ventricle. The severity of defects may vary widely (21). In our study, a diagnosed of TOF was suggested based on findings including a VSD, aortic valve overriding, bidirectional via VSD in aortic long axis view, in addition to anomalies on the three-vessel view with small pulmonic annulus.

Prenatal diagnosis of fetal congenital heart disease has been shown to have a significant effect on prenatal and postnatal management and outcomes (22). All patients with tetralogy of TOF should have preconception cardiology counseling and follow-up.

Conclusion:

It appears that although the risk of fetal cardiac malformations may be highest in women with GDM, all pregnancies of pre-gestational diabetes and GDM are at increased risk. Given this information, regular fetal echocardiographies should be consider in women with GDM.

Conflict of interest: Authors declare no conflict of interest.

References:

1. Esteghamati A, Gouya MM, Abbasi M, Delavari A, Alikhani S, Alaedini F, et al.

Prevalence of diabetes and impaired fasting glucose in the adult population of Iran: National Survey of Risk Factors for Non-Communicable Diseases of Iran. *Diabetes care.* 2008;31(1):96-8.

2. Wren C, Birrell G, Hawthorne G. Cardiovascular malformations in infants of diabetic mothers. *Heart.* 2003;89(10):1217-20.

3. Donofrio MT, Moon-Grady AJ, Hornberger LK, Copel JA, Sklansky MS, Abuhamad A, et al. Diagnosis and treatment of fetal cardiac disease. *Circulation.* 2014;129(21):2183-242.

4. Allan LD. Echocardiographic detection of congenital heart disease in the fetus: present and future. *British heart journal.* 1995;74(2):103.

5. Apitz C, Webb GD, Redington AN. Tetralogy of fallot. *The Lancet.* 2009;374(9699):1462-71.

6. Zhao Y, Abuhamad A, Fleenor J, Guo Y, Zhang W, Cao D, et al. Prenatal and Postnatal Survival of Fetal Tetralogy of Fallot. *Journal of Ultrasound in Medicine.* 2016;35(5):905-15.

7. Valente AM, Cook S, Festa P, Ko HH, Krishnamurthy R, Taylor AM, et al. Multimodality imaging guidelines for patients with repaired tetralogy of Fallot: a report from the American Society of Echocardiography: developed in collaboration with the Society for Cardiovascular Magnetic Resonance and the Society for Pediatric Radiology. *Journal of the American Society of Echocardiography.* 2014;27(2):111-41.

8. Chetboul V, Pitsch I, Tissier R, Gouni V, Misbach C, Trehiou-Sechi E, et al. Epidemiological, clinical, and echocardiographic features and survival times of dogs and cats with tetralogy of Fallot: 31 cases (2003–2014). *Journal of the American Veterinary Medical Association.* 2016;249(8):909-17.

9. Gelb BD, Chung WK. Complex genetics and the etiology of human congenital heart disease. *Cold Spring Harbor perspectives in medicine*. 2014;4(7):a013953.
10. Eidem I, Stene LC, Henriksen T, Hanssen KF, Vangen S, Vollset SE, et al. Congenital anomalies in newborns of women with type 1 diabetes: nationwide population-based study in Norway, 1999–2004. *Acta obstetrica et gynecologica Scandinavica*. 2010;89(11):1403-11.
11. Macintosh MC, Fleming KM, Bailey JA, Doyle P, Modder J, Acolet D, et al. Perinatal mortality and congenital anomalies in babies of women with type 1 or type 2 diabetes in England, Wales, and Northern Ireland: population based study. *Bmj*. 2006;333(7560):177.
12. Bronshtein M, Zimmer E, Gerlis L, Lorber A, Drugan A. Early ultrasound diagnosis of fetal congenital heart defects in high-risk and low-risk pregnancies. *Obstetrics & Gynecology*. 1993;82(2):225-9.
13. Association AD. Diagnosis and classification of diabetes mellitus. *Diabetes care*. 2010;33(Suppl 1):S62.
14. Rowland TW, Hubbell JP, Nadas AS. Congenital heart disease in infants of diabetic mothers. *The Journal of pediatrics*. 1973;83(5):815-20.
15. Øyen N, Diaz LJ, Leirgul E, Boyd HA, Priest J, Mathiesen ER, et al. Pre-pregnancy diabetes and offspring risk of congenital heart disease: A nation-wide cohort study. *Circulation*. 2016;CIRCULATIONAHA.115.017465.
16. Landon MB, Gabbe SG. Gestational diabetes mellitus. *Obstetrics & Gynecology*. 2011;118(6):1379-93.
17. Loffredo CA, Wilson PD, Ferencz C. Maternal diabetes: an independent risk factor for major cardiovascular malformations with increased mortality of affected infants. *Teratology*. 2001;64(2):98-106.
18. Franzese A, Valerio G, Ciccarelli N, De Filippo G. Severe hypertrophic cardiomyopathy in an infant of a diabetic mother. *Diabetes Care*. 1997;20(4):676.
19. Lai WW, Mertens LL, Cohen MS, Geva T. *Echocardiography in pediatric and congenital heart disease: from fetus to adult*: John Wiley & Sons; 2015.
20. Idilman IS, Ipek A, Balaban M, Keskin HL, Aypar E, Ozkutlu S. Fetal aorta larger than the main pulmonary artery on the three-vessel view: Correlation with postnatal echocardiographic findings. *Journal of Clinical Ultrasound*. 2016;44(7):423-8.
21. Bromley B, Estroff JA, Sanders SP, Parad R, Roberts D, Frigoletto FD, et al. Fetal echocardiography: accuracy and limitations in a population at high and low risk for heart defects. *American journal of obstetrics and gynecology*. 1992;166(5):1473-81.
22. Lee W, Smith RS, Comstock CH, Kirk JS, Riggs T, Weinhouse E. Tetralogy of Fallot: prenatal diagnosis and postnatal survival. *Obstetrics & Gynecology*. 1995;86(4):583-8.

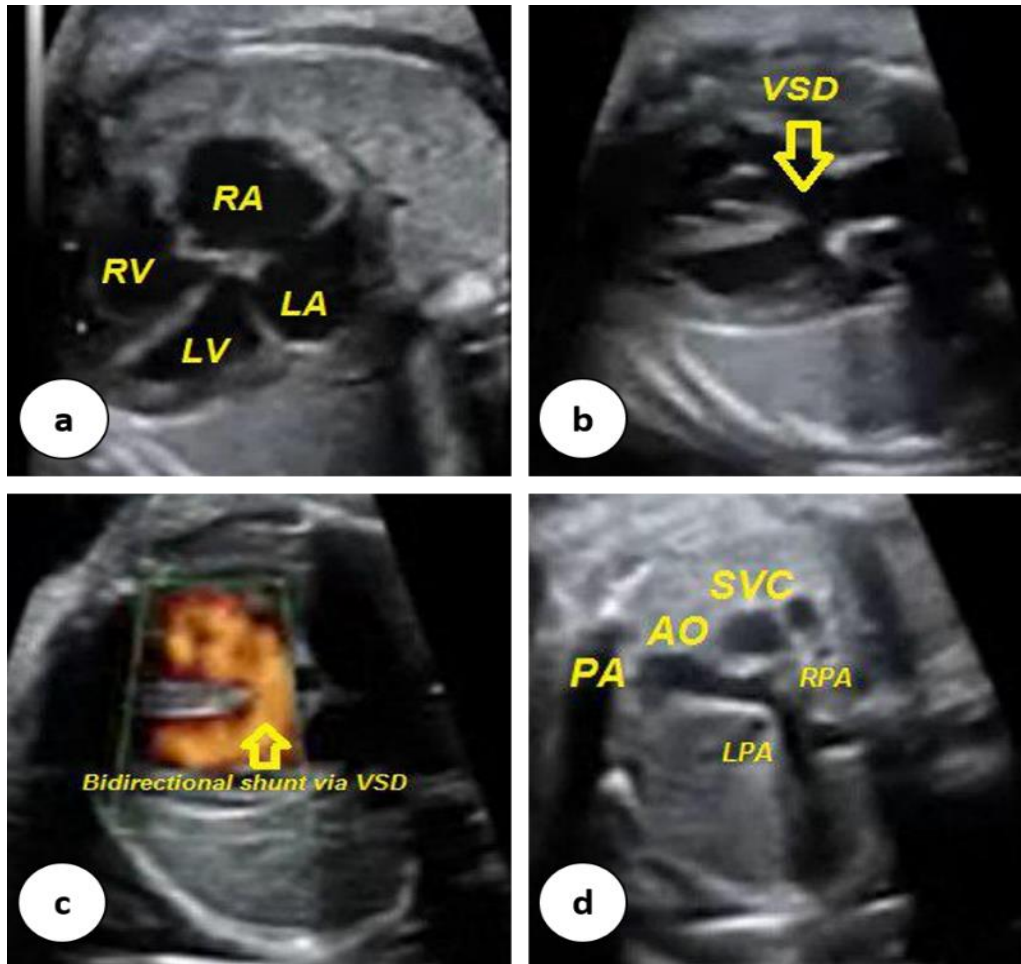


Figure 1: a) four-chamber view in fetus; showed relatively normal right ventricle chamber, b) aortic long axis view; showed ventricular septal defect (VSD) and Aorta overriding, c) aortic long axis view; showed bidirectional shunt via VSD, d) three-vessel view in fetus; showed relatively small pulmonic annulus and Pulmonary Artery (PA) branches