

## Case Report

### Fracture-Dislocation of the Thoracic Spine without Any Neurological Deficit: A Case Report and Review of the Literature

Naveed Nabizadeh 1, Alireza Yousof Gomrokchi\*2, Sam Bemani Lirgeshasi 2, Milad Bahari2

1. Assistant professor, Department of Orthopedic Surgery ,Firouzgar Hospital , Iran University of medical sciences, Tehran, IR Iran;
2. Bone and Joint Reconstruction Research Center , Shafa Orthopedic Hospital ,Iran University of Medical Sciences ,Tehran ,IR Iran.
3. Bone and Joint Reconstruction Research Center , Shafa Orthopedic Hospital, Iran University of Medical Sciences ,Tehran ,IR Iran

\*correspondence: **Alireza Yousof Gomrokchi**, Bone and Joint Reconstruction Research Center , Shafa Orthopedic Hospital ,Iran University of Medical Sciences ,Tehran ,IR Iran. E-mail:Arugomrokchi@gmail.com

#### Abstract:

**Introduction:** Thoracic spinal fracture dislocation injury usually is caused by a high-energy trauma. Therefore, this kind of injury should always be suspected in the patients who have sustained a multiple trauma. The thoracic spinal fracture-dislocation is commonly accompanied by neurological symptoms. In the literature, only few cases are reported who did not present neurological symptoms.

**Case presentation:** A 25-year-old man was brought to our emergency department following a vigorous motor-vehicle accident, complaining from excruciating pain in his right shoulder. The promptly obtained radiographs revealed right shoulder fracture dislocation that was reduced through intervenus sedation, in the emergency department. The overt shoulder injury distracted the ER physician's attention from the vertebral translation, visualized in the initial chest radiographs. Secondary survey, obtained on the next day, revealed a serious T5-T6 fracture-dislocation and absence of neurological deficit. The computed tomography and magnetic resonance imaging provided the details of the spinal injury. Open reduction and stabilization was performed by application of the rods and pedicle screws. The neurologic condition remained intact postoperatively. A CTLSO brace was administrated to wear whenever he was walking or sitting. The brace was weaned off at the 24th week when he started physical exercises.

**Conclusions:** In a small number of patients who suffered spinal fracture-dislocation, the radiographic feature or severity does not correlate with the clinical manifestation. The treatment strategy is tailored individually, i.e., open reduction and internal fixation is advised whenever surgical intervention is indicated.

**Keywords:** Dislocation, Fracture, Thoracic vertebrae, Neurological deficit

#### Introduction:

Fracture-dislocation of the thoracic spine, often accompanied with spinal cord injury, is usually caused by a high-velocity impact or a high-energy trauma [1-3]. In terms of biomechanical stability, thoracic spine

segments potentially withstand against axial translation due to unique orientation of facet joints and costotransverse articulations [ 2]. In this region, however, the spinal canal is narrow, with the least free space between the

cord and the osseous ring. Furthermore, the thoracic spinal cord, located in the watershed area, has a relatively scarce blood supply [3]. Therefore, a complete cord injury associated with an excessive neurological dysfunction may occur in the circumstances with thoracic spine fracture-dislocation. Accordingly, few numbers of patients who sustained fracture-dislocation of the thoracic spine without paraplegia are reported in the existing literature [4]. Here, we present a case of T5-T6 fracture-dislocation, lacking any neurological deficit.

### **Case presentation:**

A 25-year-old man was transferred to the emergency department following a motor-vehicle accident. He complained of right shoulder pain and denied any significant past medical history. Upon examination, his vital signs was measured: blood pressure 120/95 mmHg, pulse rate 60 per minute, respiratory rate 14 per minute, and body temperature 37 °C. The patient sustained a standard ATLS protocol in the emergency room. He denied any numbness or weakness in his extremities. Careful physical examination revealed normal sensory and motor assessment associated with sacral sparing signs including normal anal contractility and perianal sensation. Anal sphincter reflexes consisted of bulbocavernous and anal wink were entirely normal. Neither of urinary or bowel incontinence was reported. Glasgow Coma Scale score was evaluated and demonstrated 15/15 results. The patient was able to sit or stand up comfortably and did not complain from a significant back pain.

The prompt radiographs revealed right shoulder fracture dislocation that was reduced through an intravenous sedation in the emergency department (Figure 1 and 2). There was also a tiny right pleural collection which was attributed to hemothorax and treated by a chest drain, inserted under ultrasonography guidance.

On the next day, during secondary survey, the patient was complaining of a mild pain mostly located in the mid-thoracic area. Spot views of the thoracic spine demonstrated an obvious lateral translation and slight anterior displacement of T5 on T6 accompanied with the compression fracture in the superior endplate of T6 vertebrae (Figure 3). In this scenario, presence of major injury in the right shoulder combined with lacking a serious back pain and his ability to walk independently, had distracted the ER physician' attention from spinal trauma. Consequently, the spinal injury, visualized in the chest radiographs obtained during initial survey, was overlooked.

Immediate CT scan revealed T5-T6 facet subluxation and "double lumen sign" in addition to bilateral T5 transverse process fracture, T6 right pedicle and spinous process fracture associated with a mild right hemothorax. There was not any retropulsion of bony fragments into the spinal canal (Figure 4). Magnetic resonance imaging demonstrated spinal cord involvement at the injured levels as myelographic defect in addition to an abnormal high signal intensity changes, observed in T2 weighted images (Figure.5).

The neurologic status was constantly stable, however, the biomechanic instability reflected a necessity of surgical intervention.

Prior to administer a deep sedation, the patient was intubated and intra-operative somatosensory monitoring was applied. Then, the patient was carefully log-rolled and placed in a prone position under an awake general anesthesia. Subsequently, neurologic monitoring and fluoroscopic control of the injured area was performed. After preparation, drape and infusion of prophylactic antibiotic, a long midline thoracic incision was made. Dissection of subcutaneous tissues and fascia, in addition to subperiosteal elevation of muscles was carried by electrocautery from T2 to T9. The alignment of spinous processes was disturbed apparently, combined with disruption of posterior ligamentous complex (PLC) and posterior elements fracture consistent with imaging findings.

Lacking any evidence of dural tear or entrapped nerve root precluded the need for laminectomy procedure. The upper and lower level of instrumentation was identified by image intensifier. Using an awl, free-hand probing, ball-tipped probe and subsequent tapping, the pedicles of T2, T3, T4, T5, T7, T8 and T9 vertebrae were prepared to insert the polyaxial reduction screws. Because of pedicle fracture, the T6 vertebra was excluded from screw placement. Then, two bended rods were cut slightly longer than needed to accommodate distraction. The rods introduced in the proximal screws and secured by the nuts. Using cantilever forces, both rods were seated in the distal part of dislocation and fixed. Realignment of the spine was achieved easily in coronal and sagittal plane, needless to apply vigorous distraction force.

Intra-operative imaging confirmed the perfect reduction while the neurologic status remained stable and was confirmed by wake-up test. Two cross-linked rods were applied at the top and bottom of fusion levels. Finally, posterior elements decortication was performed and allografts were placed on the prepared bed from T2 through T9 vertebrae.

Postoperatively, the patient stayed in the intensive care unit for five days and thereafter he was ambulated by wearing a CTLSO. His neurologic status remained stable and he was discharged from hospital within ten days after admission. Radiographic evaluation was performed at the weeks 6, 12 and 24, postoperatively. Dynamic flexion-extension view taken after 6 month illustrated a solid and stable fusion. Therefore, the brace was discontinued and physical rehabilitation was suggested.

### **Discussion:**

Occasionally, spinal column fracture-dislocation can be overlooked inadvertently through clinical examination or radiographic evaluations. Sometimes, the clinical inspection fails to discover any defect, step-off or gibbus deformity because the posterior elements have still remained aligned. Furthermore, the concurrent internal organs or extremities damages may distract the attention of physician from spinal column injuries, particularly those associated with a mild spinal tenderness. In addition, a chest radiograph obtained initially for the soft tissues purposes is not able to illustrate clearly the spinal injuries, especially the upper thoracic spinal fractures.

Dorr, Harvey and Nickel reported a 36% incidence of hemothorax in patients who sustained thoracic spine rotational and shear injuries. Thus, the presence of a hemothorax is an aware of probable serious spinal injury [5].

Fracture-dislocation of the thoracic spine is usually secondary to high-velocity injuries, leading to failure of all three columns [1]. This biomechanic instability is frequently associated with spinal cord injury, particularly in the thoracic watershed area [2]. Furthermore, fracture-dislocation of the upper thoracic spine can readily lead to transection of the cord in the narrow spinal canal.

Bohlman in 1985 and Holdsworth in 1970 stated that shearing fractures of the thoracic region are always associated with complete paraplegia [3]. Dural tear and paraplegia often accompany such injuries. Neurologic deficit can be caused by the retro-pulsed bony fragments and/or encroachment of the spinal canal due to translational displacement.

Classification of the thoracic spine fracture-dislocations has been accomplished based on the primary trauma mechanisms [1]. Magerl believed that slide dislocation due to a sagittally directed shear force can potentially compromise the spinal cord more seriously than rotational oblique shear forces. Thus, the case report of thoracic spine fracture-dislocation in the sagittal plane lacking any neurologic deficit is extremely rare in the existing literatures.

The most crucial element, leading to an intact neurological function in the patients with thoracic spine fracture-dislocation, consists of spontaneous

decompression secondary to lamina, pedicle or facet fractures at the involved levels. These simultaneous fractures can widen the spinal canal to a significant extent and result in sparing of spinal cord [4].

Consequently, the clinical practitioner should be cautious to distinguish the subtle spinal fracture or dislocation particularly whenever there is not any apparent neurologic deficit. Therefore, inappropriate maneuver of the injured spine, leading to a disastrous damage of spinal cord, can be avoided [6].

Furthermore, an appropriate immobilization at the scene and before any medical investigation should be provided for the multiple trauma patients. CT scan of the spine with a high quality of reconstruction is the best diagnostic method for evaluation of the spinal column integrity and assessment of the bony stability [4,6,7]. MRI and myelographic images can also offer further information about the spinal cord injury or posterior tension band disruption.

Because of potential biomechanic and neurologic instability associated with spinal fracture-dislocations, surgical intervention is usually recommended to decompress the neurologic elements, to prevent secondary injury to the spinal cord [8], to realign the spine, and to stabilize the spinal column with spinal fusion [9,10].

Occasionally, conservative treatment has been recommended in older patients or those with severe underlying co-morbidities [11].

There is still controversy regarding the appropriate time for surgical intervention. [12]. Some authors believe that early surgery can potentially preserve neurologic function, provide early

mobilization, shorten the rehabilitation time, reduce the hospital stay and associated complications.

Different surgical techniques have been reported to reduce and stabilize these injuries, with or without fusion [15-18, 10]. Simpson AH etc. reported two cases of thoracic dislocation without neurological deficit. One of them received surgical reduction with Harrington instruments [13]. The single posterior approach was carried out to avoid iatrogenic injury of the spinal cord as well as the intractable complications of anterior approaches [14, 15]. Weber SC etc. performed reduction through anterior approach with Harrington rods in addition to fixation with anterior AO/ASIF plate and posterior rods and wires [16]. Reduction and fixation by means of pedicle screws and rods through a single posterior approach was reported by Jiang B etc. [4]. Conservative management was also applied to such rare thoracic-dislocation patients according to some literatures [11, 13, 17, 18]. Continuous halo-femoral traction was an optional treatment to reduce the dislocation [17, 18].

### **Conclusion:**

Fracture-dislocation of the thoracic spine without paraplegia is a rare and treatable entity. Clinical practitioners should be vigilance to distinguish spinal injury in the multiple trauma circumstances with normal neurologic examination in order to avoid inappropriate maneuvers. An overlooked spinal column instability may lead to dangerous impairment of the spinal cord.

### **Conflicts of interest:**

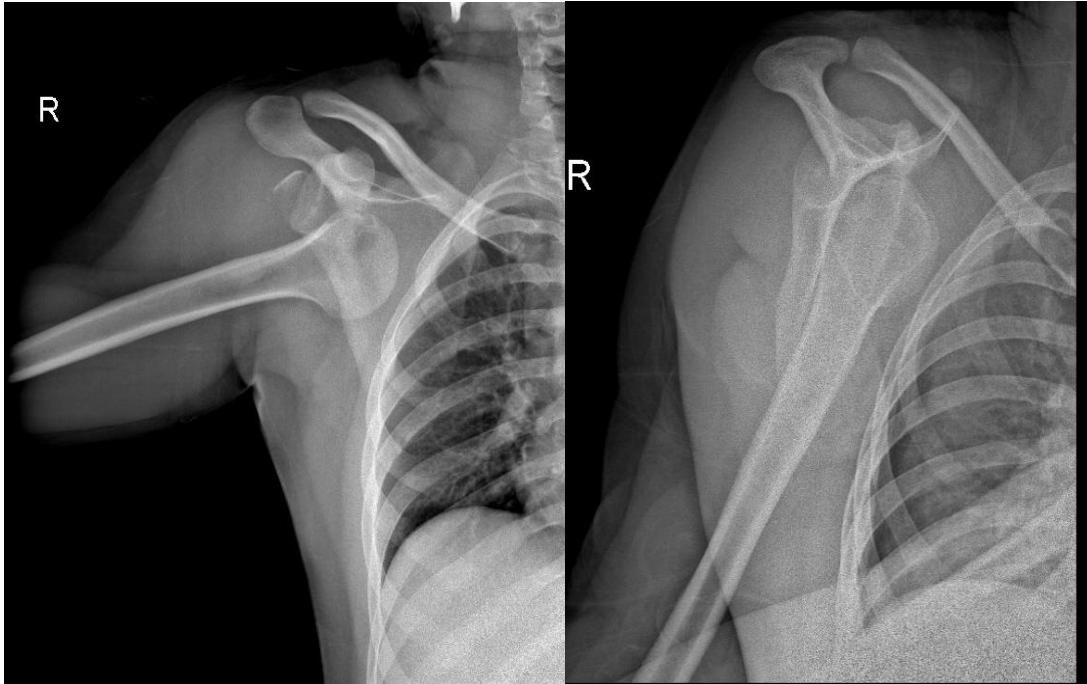
The authors declare that there are no conflicts of interest in relation to the article.

### **References:**

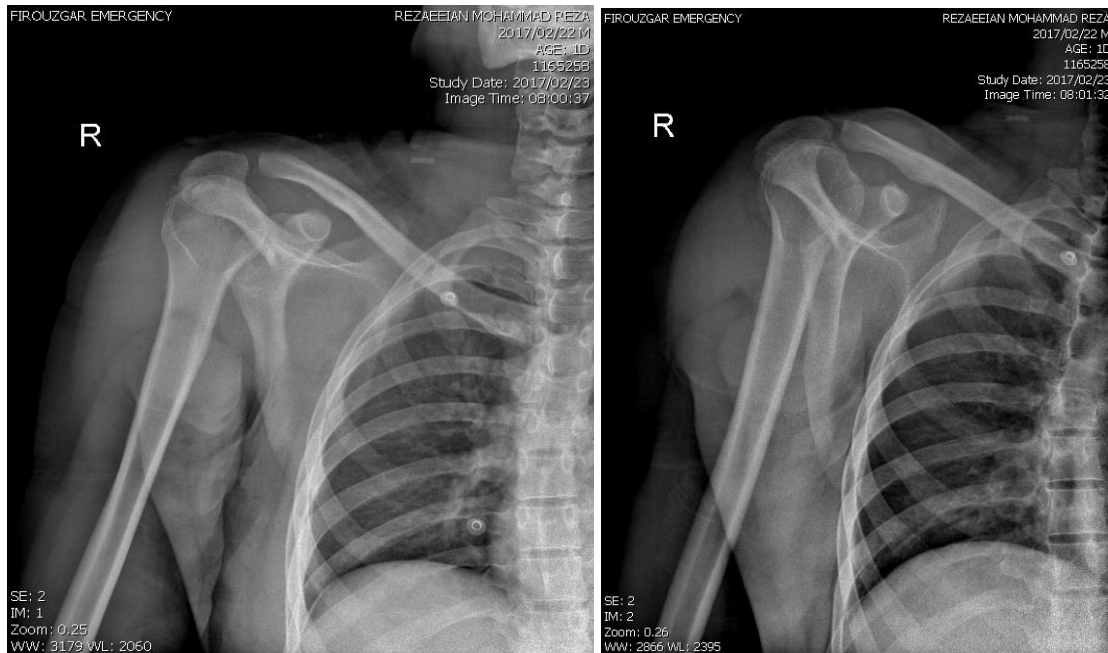
1. Korovessis P, Sidiropoulos P, Dimas A. Complete fracture-dislocation of the thoracic spine without neurologic deficit: case report. *The Journal of trauma*. 1994 Jan;36(1):122-4.
2. Denis F. The three column spine and its significance in the classification of acute thoracolumbar spinal injuries. *Spine*. 1983;8(8):817-31.
3. Bohlman HH. Treatment of fractures and dislocations of the thoracic and lumbar spine. *JBJS*. 1985 Jan 1;67(1):165-9.
4. Jiang B, Zhu R, Cao Q, Pan H. Severe thoracic spinal fracture-dislocation without neurological symptoms and costal fractures: a case report and review of the literature. *Journal of medical case reports*. 2014 Dec;8(1):343.
5. Dorr LD, Harvey JJ, Nickel VL. Clinical review of the early stability of spine injuries. *Spine*. 1982;7(6):545-50.
6. AKAY KM, BAYSEFER A, KAYALI H, BEDUK A, TIMURKAYNAK E. Fracture and lateral dislocation of the T12-L1 vertebrae without neurological deficit. *Neurologia medico-chirurgica*. 2003;43(5):267-70.
7. Sasson A, Mozes G. Complete Fracture-Dislocation of the Thoracic Spine Without Neurologic Deficit: A Case Report. *Spine*. 1987 Jan 1;12(1):67-70.
8. Vialle LR, Vialle E. Thoracic spine fractures. *Injury*. 2005 Jul;36:B65-72.
9. Holdsworth FW. Fractures, dislocations, and fracture-dislocations of the spine. *The Journal of Bone and Joint Surgery. British Volume*. 1963 Feb;45(1):6-20.

10. Abdel-Fattah HU, Rizk AH. Complete fracture-dislocation of the lower lumbar spine with spontaneous neurologic decompression. *Clinical orthopaedics and related research*. 1990 Feb(251):140-3.
11. Miyasaka Y, Satomi K, Sugihara S, Tahara Y, Hayashi T, Ishii Y. Posterior fracture-dislocation of the thoracic spine without neurologic deficit. A case report and short literature review. *Spine*. 1993 Nov;18(15):2351-4.
12. Bohlman HH, Freehafer A, Dejak J. The results of treatment of acute injuries of the upper thoracic spine with paralysis. *The Journal of bone and joint surgery. American volume*. 1985 Mar;67(3):360-9.
13. Simpson AH, Williamson DM, Golding SJ, Houghton GR. Thoracic spine translocation without cord injury. *Bone & Joint Journal*. 1990 Jan 1;72(1):80-3.
14. Fehlings MG, Cadotte DW, Fehlings LN. A series of systematic reviews on the treatment of acute spinal cord injury: a foundation for best medical practice. *Journal of neurotrauma*. 2011 Aug 1;28(8):1329-33.
15. Wiggins GC, Mirza S, Bellabarba C, West GA, Chapman JR, Shaffrey CI. Perioperative complications with costotransversectomy and anterior approaches to thoracic and thoracolumbar tumors. *Neurosurgical focus*. 2001 Dec;11(6):1-9.
16. Weber SC, Sutherland GH. An unusual rotational fracture-dislocation of the thoracic spine without neurologic sequelae internally fixed with a combined anterior and posterior approach. *The Journal of trauma*. 1986 May;26(5):474-9.
17. Gertzbein SD, Offierski C. Complete fracture-dislocation of the thoracic spine without spinal cord injury. A case report. *JBJS*. 1979 Apr 1;61(3):449-51.
18. Uriarte EN, Elguezabal B, Tovio RA. Fracture-dislocation of the thoracic spine without neurologic lesion. *Clinical orthopaedics and related research*. 1987 Apr(217):261-5.

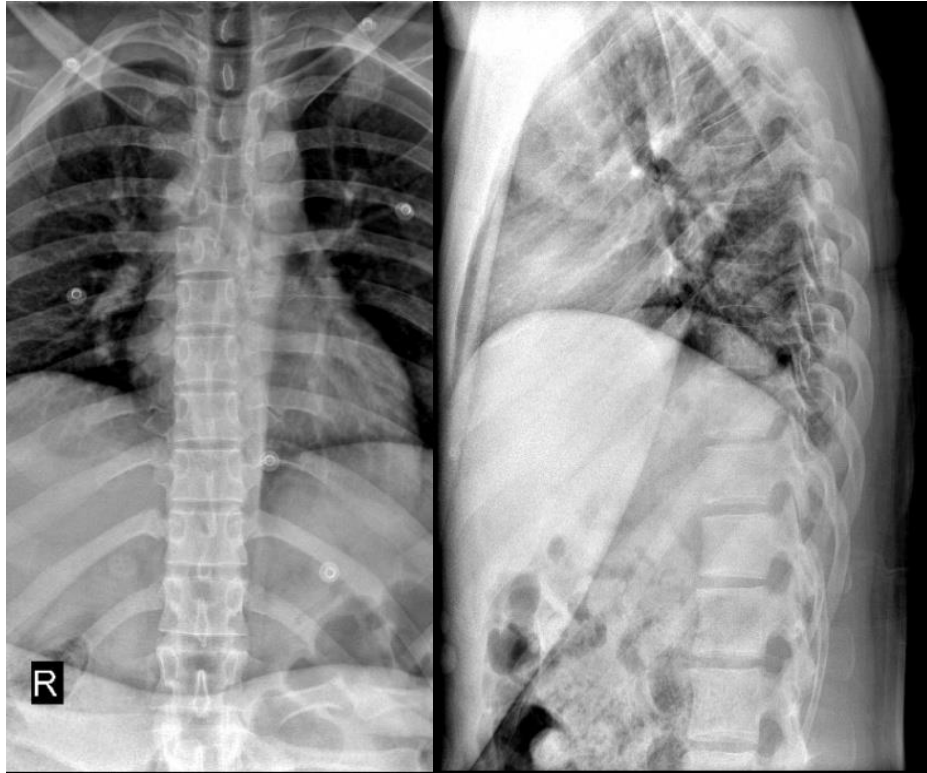




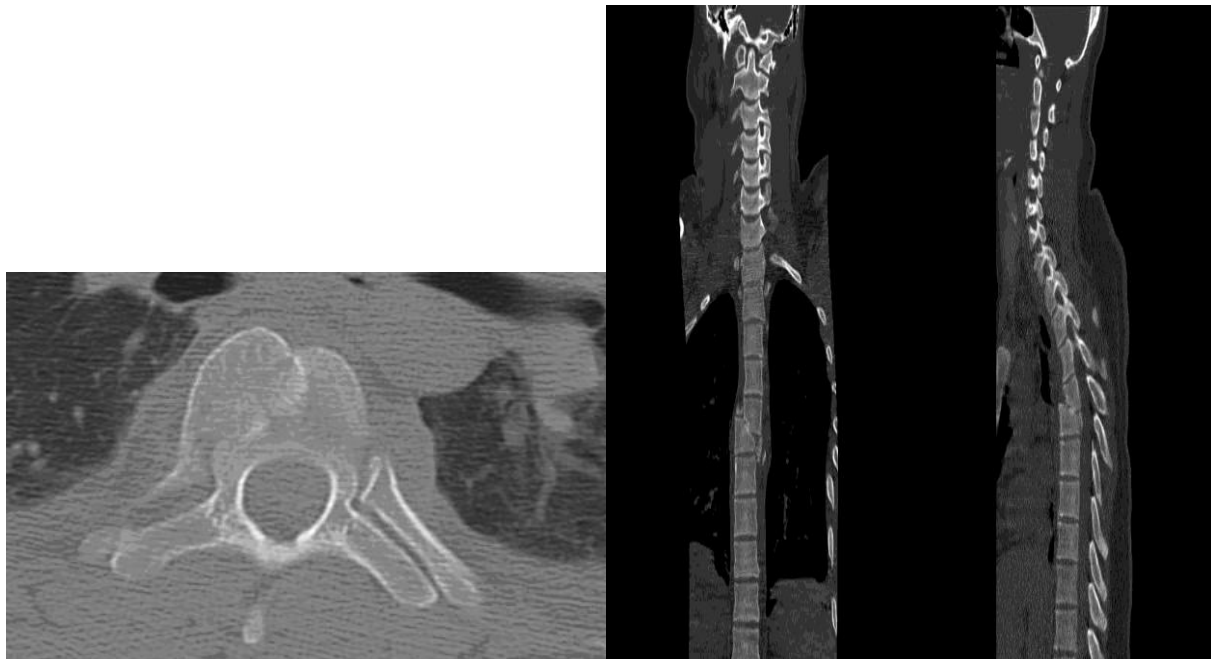
**Figure 1:** Anteroposterior and Y-view radiography of the right shoulder illustrated anterior glenohumeral fracture dislocation.



**Figure 2:** Anteroposterior and Y-view radiographs of the right shoulder after closed reduction

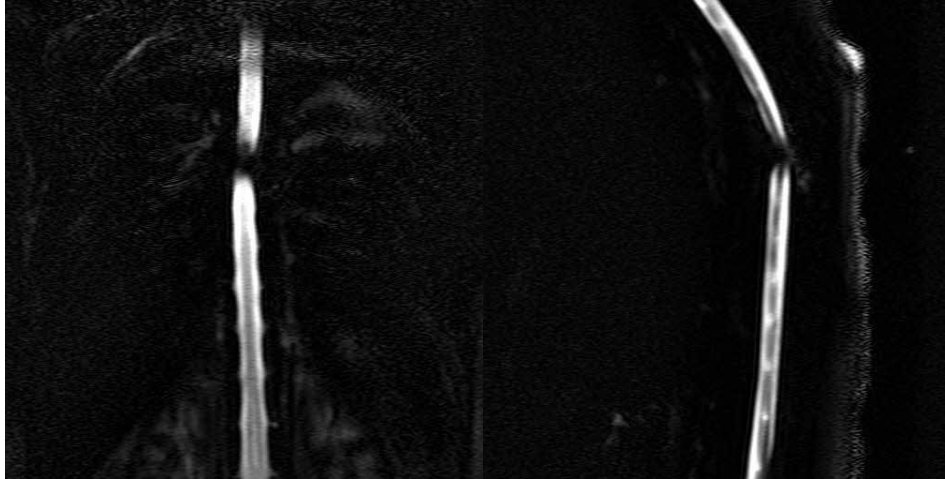

**Figure 3:** Preoperative posteroanterior and lateral radiographs of the thoracic spine revealed fracture and lateral dislocation of the T5 on the T6 vertebrae

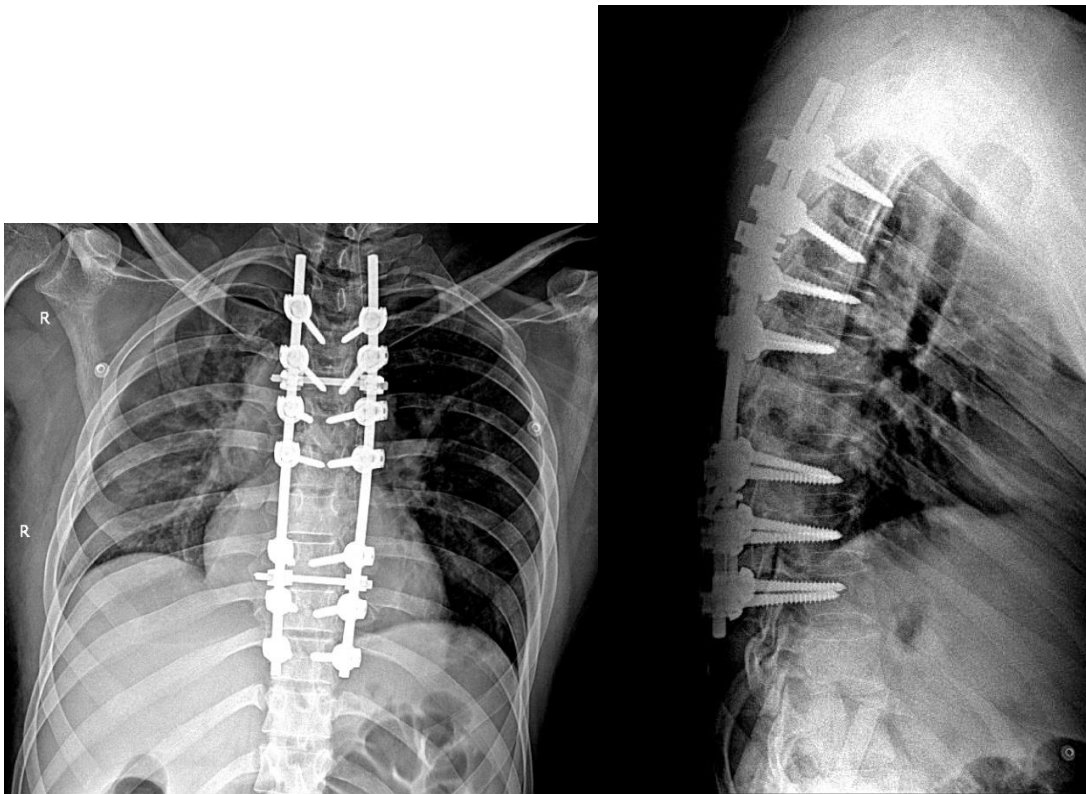


**Figure 4:** CT scan showed T5-T6 fracture-dislocation.





**Figure 5:** MRI myelogram illustrated the absence of continuity in the spinal cord at the involved level.



**Figure 6:** Postoperative posteroanterior (A) and lateral (B) radiographs revealed sagittal and coronal realignment of the spine.