

Case Report

Mineral Trioxide Aggregate (MTA) As a Pulpotomy Agent in Developing Permanent Teeth: A Case Report

Ali Malekzadeh Shafaroudi ¹, Haleh Hali ^{2*}

1. Student research committee, Faculty of Dentistry, Mazandaran University of Medical Sciences, Sari, Iran.
2. Assistant Professor, Department of pedodontics, Dental Faculty, Mazandaran University of Medical Sciences, Sari, Iran.

*correspondence: **Haleh Hali**, Mazandaran University of Medical Sciences, Sari, Iran. Email: h.hali.md@gmail.com

Abstract

Introduction: Traumatic injuries or caries to developing permanent teeth may prevent the integrity of root maturation and finally result in pulp necrosis, vital pulp therapy (VPT) is a suitable treatment for these teeth. This article describes a successful apexogenesis report of a nine year old boy with impact trauma to the mandibular left first molar which caused complicated crown fracture, pulp exposure and thereupon spontaneous pain.

Methods: Cervical pulpotomy was performed and the remaining pulp was capped with mineral trioxide aggregate (MTA). Afterwards the crown was restored using a stainless steel crown, the patient was followed up using radiographic images and clinical examinations 6 and 12 months after the treatment.

Findings: The follow up documents indicated that the tooth maturation was completed, the apex was developed and a calcified barrier was formed right above the remaining vital pulp and no other endodontic treatments were needed.

Conclusion: Regarding to the excellent healing potential of the immature vital pulp and using MTA as medicated filling matter, clinical and radiographic documents represent MTA as a successful pulpotomy agent in immature permanent teeth.

Keywords: Apexogenesis, Mineral Trioxide Aggregate, Open apex, Pulpotomy, Trauma

Introduction:

Traumatic injuries to teeth with vital pulps and open apices could result in pulpal and periapical diseases. One of the greatest challenges in these cases is to maintain the vitality of the pulp and allow root formation and apical closure to be completed (1,

2). Vital pulp therapy (VPT) is the treatment choice for a traumatized immature tooth with an open apex on pulp exposures. Due to their several advantages such as shorter appointments and less technical sensitivity, vital pulp therapies such as apexogenesis are used more frequently than other methods such as apexification. (2-4). Apexogenesis

promotes continuation of root development which results in apical closure and strengthens the structure of the root (4, 5). In this method the coronal pulp is totally or partially removed usually to the level of canal orifices, afterwards the remaining pulp is capped using a biocompatible and bactericidal material in order to induce a hard tissue formation and provide a probable seal (4). Calcium hydroxide (CH) has been used as the main capping agent for many years, although disadvantages such as defects in the dentine bridge formed under the CH layer have been reported which increase the risk of failure (6). Recently the application of regenerative endodontic materials are rapidly spreading. Mineral Trioxide Aggregate (MTA) has been introduced as a more effective capping agent which is more biocompatible and forms a thick bridge in order to seal and preserve the pulp tissue under it, MTA also shows less deficiency compared to CH (7, 8). This case report presents regenerative treatment of a traumatized immature mandibular first molar by using MTA as a capping agent.

Case Presentation:

A nine year old boy was referred to the department of pediatric dentistry with a history of prior impact trauma four weeks before the initial appointment. The patient's chief complaint was spontaneous pain and sensitivity to hot and cold drinks. He had no considerable medical history. In prior dental history, the patient reported a traumatic accident which involved the left Mandibular first Molar. Clinical examination indicated a complicated crown fracture with a large pulpal exposure on the left mandibular first

molar. The tooth was sensitive to both palpation and precession tests. Cold thermal test also irritated the pulp and caused sharp pain. Radiographic examinations showed that the traumatized tooth was immature and had an open apex (Figure 1A.)

Considering these conditions the treatment plan was to perform a partial pulpotomy and place a suitable material on the remaining pulp in order to permit apexogenesis. Under local anesthesia with 2% Lidocaine and 1:80000 epinephrine (Daroupakhsh, Tehran, Iran) and rubber dam isolation, an access cavity was prepared using a diamond fissure bur (Diatech, Heerbrugg, Switzerland) with copious water spray in order to prevent heat damage to the pulp. Afterwards the access cavity was rinsed with normal saline and the coronal pulp tissue was removed to a level at which adequate hemostasis was achieved by placing a moistened sterile cotton pellet for 5 minutes over the remaining pulp.

White Mineral Trioxide Aggregates (ProRoot MTA, Dentsply, Tulsa, OK, USA) powder was mixed with distilled water according to manufacturer's instructions and placed without pressure over the exposed pulp. In order to set the capping material, a moistened cotton pellet was gently placed over the MTA and the tooth was temporarily filled with Cavit (Asia Chemi Teb Co., Tehran, Iran). One day later, the temporary restoration was removed to ensure the setting of MTA, eventually tooth was covered with a stainless steel crown restoration (Figure 1B). The referral sessions were performed 6 and 12 months after the treatment. In clinical examination, the tooth was asymptomatic. In radiographic

examinations, the tooth showed increased root lengths, apical closure and complete root growth. Root wall thickness had also increased and a calcified bridge was formed above the vital pulp, normal thickness of PDL space and continuity of lamina dura was also notable (Figure 1C & 1D).

Discussion:

Preserving the pulp vitality of traumatized teeth requires a healthy pulp (2). Traumatic exposures are capable of causing pulp contamination by saliva and oral bacteria, as the period of time between the initial exposure and treatment increases, pulp removal must be extended apically to make sure that the remaining pulp is completely uncontaminated (9). The goal of vital pulp therapy in immature permanent teeth is to treat reversible pulpal injuries and preserve the remaining pulp in order to lead to apical closure (4). In the present case, however, considering the long period of pulpal exposure, cervical pulpotomy was performed for the left Mandibular first Molar (10). The pulp cap material used in vital pulp therapy can be extremely effective in the success of the treatment (11). In this study due to the absence of apical constriction in the root canal, MTA was used as a pulp capping agent because its desirable sealing ability and biocompatibility (12, 13). The mentioned tooth in this report showed successful outcome with no need for further endodontic intervention. The usual treatment for traumatized open apex teeth has been apexification with calcium hydroxide which has many disadvantages including increased risk of fracture, long and numerous

treatment sessions and coronal microleakage (14, 15). Also apexification prevents further development of the root and results in an increased risk of fracture due to a short and weakened root (16). On the other hand, MTA forms an impenetrable barrier above the remaining pulp, therefore protects the vital pulp from bacterial invasion and facilitates complete root formation and apical closure, MTA can be used in the presence of moisture in the root canal which is important in treating necrotic pulps and teeth with periapical lesions due to the presence of exudates at the root apex (17). MTA is capable of simulating human gingival fibroblasts (HGF) to produce bone morphogenetic protein (BMP)-2 and transforming growth factor (TGF) β -1 which are two important contributors that lead to favorable biologic responses of MTA (18). Cell culture studies have indicated the effects of MTA on cementoblast growth and osteocalcin production which shows that MTA can induce cementoconductivity and osteoconductivity (19). In the following case, apexogenesis treatment with MTA is completed after 12 months and formation of a calcified barrier is evident in follow up radiographic images and since no further endodontic treatments were required, it is concluded that MTA has enough desirable properties to be used as a pulp capping material, however further clinical studies with longer follow up periods are recommended.

References:

1. Bastone EB, Freer TJ, McNamara JR. Epidemiology of dental trauma: a review

of the literature. Australian dental journal. 2000;45(1):2-9.

2. Witherspoon DE. Vital pulp therapy with new materials: new directions and treatment perspectives—permanent teeth. Pediatric dentistry. 2008;30(3):220-4.

3. Rafter M. Apexification: a review. Dental Traumatology. 2005;21(1):1-8.

4. Barrington C, Barnett F. Apexogenesis in an incompletely developed permanent tooth with pulpal exposure. Oral Health. 2003;93(2):49-56.

5. Katebzadeh N, Dalton BC, Trope M. Strengthening immature teeth during and after apexification. Journal of Endodontics. 1998;24(4):256-9.

6. Asgary S, Eghbal MJ, Parirokh M, Ghanavati F, Rahimi H. A comparative study of histologic response to different pulp capping materials and a novel endodontic cement. Oral Surgery, Oral Medicine, Oral Pathology, Oral Radiology, and Endodontology. 2008;106(4):609-14.

7. FORD TRP, Torabinejad M, ABEDI HR, BAKLAND LK, KARIYAWASAM SP. Using mineral trioxide aggregate as a pulp-capping material. The Journal of the American Dental Association. 1996;127(10):1491-4.

8. Torabinejad M, Watson T, Ford TP. Sealing ability of a mineral trioxide aggregate when used as a root end filling material. Journal of endodontics. 1993;19(12):591-5.

9. Swift EJ, Trope M. Treatment options for the exposed vital pulp. Practical periodontics and aesthetic dentistry. 1999;11:735-9.

10. Kontham UR, Tiku AM, Damle SG, Kalaskar RR. Apexogenesis of a symptomatic mandibular first permanent molar with calcium hydroxide pulpotomy. Quintessence international (Berlin, Germany: 1985). 2005;36(8):653-7.

11. Qudeimat M, Barrieshi-Nusair K, Owais A. Calcium hydroxide vs. mineral trioxide aggregates for partial pulpotomy of permanent molars with deep caries. European Archives of Paediatric Dentistry. 2007;8(2):99-104.

12. Karabucak B, Li D, Lim J, Iqbal M. Vital pulp therapy with mineral trioxide aggregate. Dental Traumatology. 2005;21(4):240-3.

13. Tomson PL, Grover LM, Lumley PJ, Sloan AJ, Smith AJ, Cooper PR. Dissolution of bio-active dentine matrix components by mineral trioxide aggregate. Journal of Dentistry. 2007;35(8):636-42.

14. Andreasen JO, Farik B, Munksgaard EC. Long-term calcium hydroxide as a root canal dressing may increase risk of root fracture. Dental Traumatology. 2002;18(3):134-7.

15. Holden DT, Schwartz SA, Kirkpatrick TC, Schindler WG. Clinical outcomes of artificial root-end barriers with mineral trioxide aggregate in teeth with immature apices. Journal of endodontics. 2008;34(7):812-7.

16. Cvek M. Prognosis of luxated non-vital maxillary incisors treated with calcium hydroxide and filled with gutta-percha. A retrospective clinical study. *Dental Traumatology*. 1992;8(2):45-55.
17. Parirokh M, Torabinejad M. Mineral trioxide aggregate: a comprehensive literature review—part I: chemical, physical, and antibacterial properties. *Journal of endodontics*. 2010;36(1):16-27.
18. Guven G, Cehreli ZC, Ural A, Serdar MA, Basak F. Effect of mineral trioxide aggregate cements on transforming growth factor β 1 and bone morphogenetic protein production by human fibroblasts in vitro. *Journal of endodontics*. 2007;33(4):447-50.
19. Thomson TS, Berry JE, Somerman MJ, Kirkwood KL. Cementoblasts maintain expression of osteocalcin in the presence of mineral trioxide aggregate. *Journal of Endodontics*. 2003;29(6):407-12.

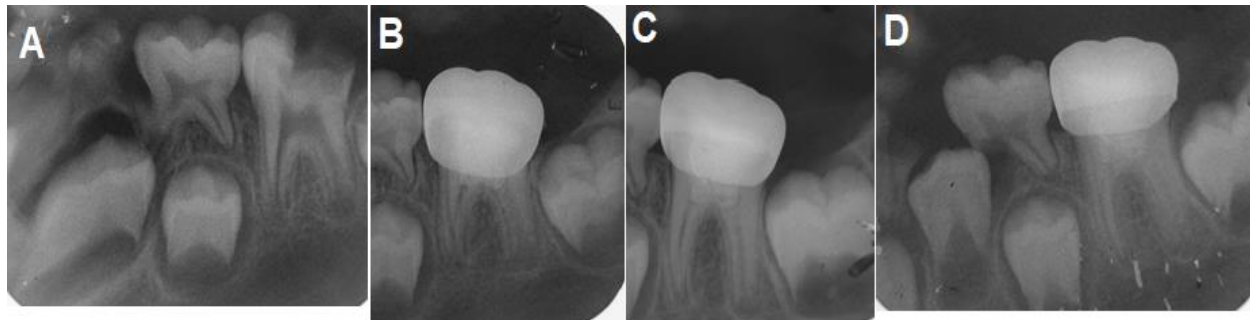


Figure 1: (A) perioperative radiograph (B) after pulp capping with MTA a restoring the tooth with a stainless steel crown (C) follow up radiograph after 6 months (D) follow up radiograph after 12 months