

Case Report

Interstitial Incisional Hernia Following Appendectomy: a Case Report

Nasrin Rahmani¹, Mohammad Chavoshinejad¹, Morteza Behnamfar², Ali Mirabi³, Keyvan Karimifar⁴, Amir Shamshirian⁵, Amirhossein Hessami³, Seyyed Abbas Hashemi^{6*}, Sina Nazemi⁷, Ashkan Piranvisheh⁷

1. Department of General Surgery, Faculty of Medicine, Mazandaran University of Medical Sciences, Sari, Iran.
2. Student research committee, School of Medicine, North Khorasan University of Medical Sciences, Bojnurd, Iran.
3. Medical Student, Student Research committee, Mazandaran university of Medical Sciences, Sari, Iran.
4. Medical Student, Student Research committee, Mashhad University of Medical Sciences, Mashhad, Iran.
5. Department of Laboratory Sciences, Student Research Committee, School of Allied Medical Science, Mazandaran University of Medical Sciences, Sari, Iran.
6. Department of Internal Medicine, Faculty of Medicine, Student Research Committee, Mazandaran University of Medical Sciences, Sari, Iran.
7. Faculty of Medicine, Mazandaran University of Medical Sciences, Sari, Iran.

*correspondence: **Seyyed Abbas Hashemi**, Department of Internal Medicine, Faculty of Medicine, Student Research Committee, Mazandaran University of Medical Sciences, Sari, Iran. Email: abbas.hashemi30@gmail.com

Abstract:

Incisional herniation after appendectomy is a rare condition, occurring in less than 0.12% of operations for appendicitis. A 46-year-old woman referred with a hernia at the site of a McBurney incision with the history of Appendectomy for acute appendicitis 6 years ago. There was evidence of a long segment of the colon (possibly cecum), a significant increase in colon thickness and inflammatory changes in the abdominal wall, as well as in the mesenteric fat with possible adhesion as a fixed bowel loop in the place of the previous laparotomy. The diagnosis of interstitial incisional hernia was made and the patient was scheduled for the surgery. The patient had no complaints of pain after the operation, and in follow up courses, there was no recurrence of a hernia.

Keywords: Hernia, Appendectomy, Interstitial Incisional, Iran

Introduction:

Appendectomy for acute appendicitis is a very common surgical procedure in a surgical emergency and it is one of the most commonly performed procedures done by a general surgeon (1). An incisional hernia is a potential complication of any laparotomy or laparoscopic procedure (2). Among complications associated with the surgery, the occurrence of an interstitial hernia is

quite unusual with an incidence of less than 0.12% of patients (3). Interstitial incisional hernia after appendectomy is an extremely rare condition. Here we reported a case of a 46-year-old woman presented with a painful bulge in the previous McBurney incision site with the history of appendectomy 6 years ago. This is an interesting case of an incisional hernia, which may be a diagnostic challenge to the surgeon with an unusual presentation, which may cause unnecessary

delay in treatment as well as unnecessary operations.

Case presentation:

A 46-year-old woman referred due to cutaneous bulging and pain in the right lower quadrant of the abdomen in the appendectomy surgery site. The abdominal pain started 4 days ago and exacerbated with activities and spontaneously disappeared itself on resting and lying down. The patient's abdominal pain first had a colic nature then it is gradually sustained. The patient had underlying symptoms of nausea, vomiting (for several times) and without defecation for about 5 days. She had no fever, chills or constipation. She had undergone an appendectomy for acute appendicitis 6 years ago. Drug history was negative and she did not have any history of allergy to foods or drugs. The social history of smoking, opium addiction or alcohol consumption were all-negative. There was no family history of underlying diseases.

At the time of addition, the patient was not ill or toxic. Vital signs were in stable condition. Over abdominal examination, bulge increased in size with Valsalva maneuvers such as coughing and bowel movements. The bulged mass measuring approximately 7*8 cm in the upper part of the McBurney incision was palpated which was tender and had a firm consistency. There were no rebound tenderness or involuntary guarding. Other physical examinations were normal.

Laboratory tests were all in the normal range. In ultrasound imaging, there was

evidence of a long segment of the colon (possibly cecum), a significant increase in colon thickness and inflammatory changes in the abdominal wall, as well as in the mesenteric fat. Significant free fluid volume was also observed around the segment. The following findings suggested possible adhesion as a fixed bowel loop into the abdominal wall in the place of the previous laparotomy (Figure 1).

The diagnosis of interstitial incisional hernia was suggested and the patient was scheduled for the surgery (Figure 2). After the operation, the patient had no complaints of pain in follow up courses without recurrence of a hernia and at present is in good condition.

Discussion:

An interstitial hernia is the less common type of abdominal herniation in which a hernia passes through a defect in the transversus abdominis and internal oblique muscles, but not through the intact aponeurosis of the external oblique (4). The incidence rate of incisional hernia occurrence was shown to be in 80% of cases during the first 24 months and 13% in the first 5 years (5). In our case, the incisional hernia developed after 6 years appendectomy.

However, considerable advances have been made in the surgical techniques and operative materials; an interstitial incisional hernia is still a major complication of abdominal surgery (6). Obesity, older age, male gender, diabetes mellitus, smoking, and those who use steroids for medical

conditions are some patient-related factors associated with the tendency to develop incisional hernias. Additionally, emergency and bowel surgery, abdominal distention, poor tissue selection, poor surgical technique and wound infection are some surgical associated factors, which play a role on the incidence rate of hernias occurrence (7, 8). In our case, there was only post-operative appendectomy history, which may contribute to hernia reoccurrence.

Conclusion:

This vague hernia is a diagnostic problem for the surgeon and requires visual examination in the form of ultrasound imaging and computed tomography scan. Interstitial incisional hernias can be misdiagnosed easily. The risk of recurrence of interstitial incisional hernias should be considered as the complication of the appendectomy surgery.

Conflict of interest:

All authors declared no conflicts of interest

References:

1. Pittman-Waller VA, Myers JG, Stewart RM, Dent DL. Appendicitis: why so complicated? Analysis of 5755 consecutive appendectomies. *The American surgeon*. 2000;66(6):548.

2. Cassar K, Munro A. Surgical treatment of an incisional hernia. *British journal of surgery*. 2002;89(5):534-45.
3. Konstantakos AK, Zollinger RM. Repair of McBurney incisional hernias after open appendectomy. *Current surgery*. 2000;57(1):79-80.
4. Ellis H. Appendix and appendectomy. *Maingot's abdominal operations*. 1997;2:1191-227.
5. Regnard J, Hay J, Rea S, Fingerhut A, Flamant Y, Maillard J. Ventral incisional hernias: incidence, date of recurrence, localization and risk factors. *The Italian journal of surgical sciences*. 1988;18(3):259-65.
6. Abrahamson J. Mechanisms of hernia formation. *Abdominal Wall Hernias*: Springer; 2001. p. 133-8.
7. Bosanquet DC, Ansell J, Abdelrahman T, Cornish J, Harries R, Stimpson A, et al. Systematic review and meta-regression of factors affecting midline incisional hernia rates: analysis of 14 618 patients. *PLoS One*. 2015;10(9):e0138745.
8. Kumar A, Saidha N, Ramakrishnan T, Sahu S. Interstitial incisional hernia following appendectomy. *Medical journal, Armed Forces India*. 2009;65(2):176.

Figures:

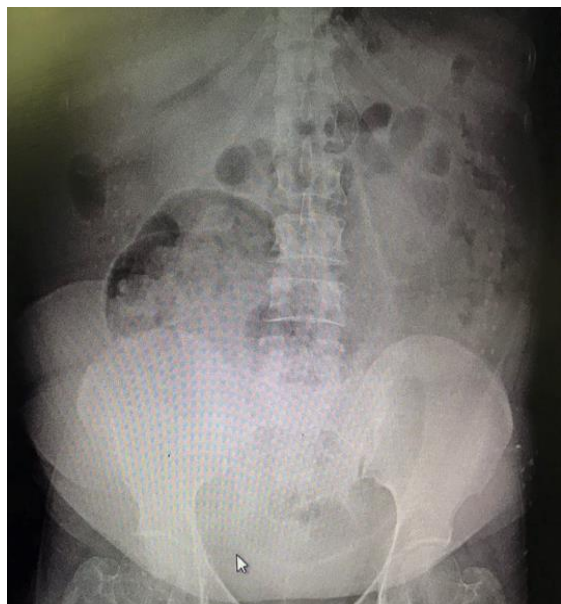


Figure 1: Abdominal X-ray imaging

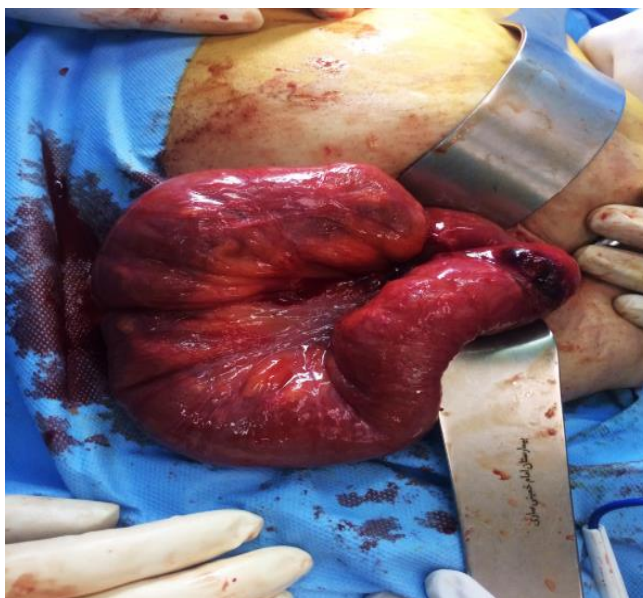


Figure 2: Interstitial incisional hernia