

## Original article

# Prevalence and Pattern of Torus Mandibularis and Torus Palatinus among Iranian Population

Mehran Ebrahimzadeh Hassanabadi<sup>1</sup>, Zohreh Eizadi<sup>1</sup>, Maedeh Yousefnezhad<sup>1</sup>, Amirhossein Moaddabi<sup>2</sup>

1. Dental Student, Faculty of Dentistry, Student Research Committee, Mazandaran University of Medical Sciences, Sari, Iran
2. Assistant Professor, Department of Oral and Maxillofacial Surgery, Faculty of Dentistry, Mazandaran University of Medical Sciences, Sari, Iran

\*correspondence: **Amirhossein Moaddabi**, Assistant Professor, Department of Oral and Maxillofacial Surgery, Faculty of Dentistry, Mazandaran University of Medical Sciences, Sari, Iran, Email: [meeehran@gmail.com](mailto:meeehran@gmail.com)

## Abstract

**Introduction:** Torus palatinus (TP) and torus mandibularis (TM) are slow growing anatomical bony protuberances with unknown etiology seen on the alveolar surfaces of the maxilla and mandible. The aim of this study was to determine the prevalence, and shape of TP and TM in relation to age and sex in Iranian population.

**Methods:** The present study included 613 subjects (458 men and 389 women) with mean age of  $43.31 \pm 16.87$  years. The subjects were examined for the existence of tori by clinical inspection and palpation. Statistical analysis was performed using SPSS 22.0 software program.

**Findings:** Among the 106 subjects with tori, 8 (7.55%) had either TP or TM. 41 (38.68%) subjects had TP, whereas 57 (53.77%) had TM. The maximum percentage of TP, TM, and either tori was observed in the age-group of 49–59 years, the oldest group (59 and older years age range), and the age-group 49-59 years. The percentage of females with tori was higher when compared to males, which is however not significant. According to shape, the occurrence of flat-shaped TP (41.46%) and bilateral solitary TM (42.11%) was more common.

**Conclusion:** This study indicated that the prevalence of TP in Iranian population was 17.29%. No significant difference in the presence of tori with respect to sex and age was observed. According to the literature, flat TP and bilateral solitary TM were the most common type in our population.

**Keywords:** Torus palatinus, Torus mandibularis, Prevalence, Iranian population

## Introduction:

Torus palatinus (TP) and torus mandibularis (TM) are non-pathological bony protuberances with unknown etiology seen on the alveolar surfaces of the maxilla and mandible. (1, 2) TP and TM are slow growing osseous outgrowths (exophytic) in the midline of the hard palate (torus palatinus) and in the lingual cortical bones of mandible (torus mandibularis). (2) It is generally accepted as an anatomical variation rather than a pathological condition. (3)

According to the shape, TP can be classified as flat, spindle-shaped, nodular, and lobular, whereas TM can be classified as unilateral and bilateral solitary (US, BS), unilateral and bilateral multiple (UM, BM), and bilateral combined (BC). (4) Based on their size, TP classified as small (less than 3 mm), medium (3–6 mm), and large (more than 6 mm) tori. (5)

The etiology of the development of tori is still unknown and several factors have been proposed such as: Genetic, masticatory stress, developmental anomalies, infection, malnutrition, and discontinued growth. (6-10). The aim of this study was to determine the prevalence, and shape of TP and TM and to investigate the relationship between the findings in relation to age and sex in Iranian population.

## Methods:

Sample size was calculated wherein minimum of 232 subjects were required to get estimate of prevalence of tori and exostosis. In order to determine the sample size we use the AlZarea BK study results

(12). In the mentioned study, the frequency of TM or TP was 17.6% and the sample size was 232 with the 95% confidence level and significance level of 0.05. In the present study, we selected 613 patients to increase efficiency of study results. Patients who attended private dental office were examined between September, 2017 and February, 2018 for the presence of TP and TM.

The study comprised of 235 male and 378 female subjects. The subjects were stratified into six age groups: 12–19, 20–29, 30–39, 40–49, 50–59 and 60 years and older. The existence of tori was determined by clinical examination and palpation, and result of the test was recorded as present or absent.

The shape of TP was classified as flat, nodular, spindle and lobular according to Jainkittivong et al (5, 11), whereas TM was classified as unilateral and bilateral solitary, unilateral and bilateral multiple, and bilateral combined. (4)

Patients with questionable tori were excluded from the study. The data were collected and entered into SPSS 22 Software program. The statistical analysis was performed using Chi-square test at  $P < 0.05$  considered as statistically significant. Ethical approval was obtained from the Dental Research Center, Mazandaran University of Medical Sciences. Written informed consent was taken from all the participants included in the study.

## Findings:

In total, 106 participant were included in this study had tori, consisting of 42 men (39.62%) and 64 women (60.38%) with a

mean age of  $43.31 \pm 16.87$  years. The mean age was  $42.79 \pm 15.94$  years for males and  $43.66 \pm 17.66$  years for females, which was not statistically different ( $P=0.796$ ). Out of a total of 106 subjects, 8 (7.55%) had prevalence of either tori. 41 (38.68%) had TP and 57(53.77%) had TM. Table 1 presents the distribution of TP and TM in relation to age and gender. TM was significantly more prevalent in both genders (54.69% and 52.38% in females and males, respectively).

Patients were divided to six groups with respect to age. Groups were as follows: 12-19 years, 19-29 years, 29-39 years, 39-49 years, 49-59 years, and older than 59 years. Table 2 represents the distribution of TP and TM with respect to age. The highest TM prevalence (24.56%) were in the oldest group (59 and older years age range), the highest TP prevalence (34.15%) were in the age-group 49-59 years, and the highest prevalence of either tori (37.50%) were in the age-group 49-59 years (Figure 1).

Table 3 presents the distribution of 41TP subjects according to shape. The most common shape was flat (41.46%), also out of 57 subjects of TM, the highest prevalence was related to BS (42.11%). Among 8 subjects of simultaneously occurrence of TP and TM, the highest prevalence of TM shapes was related to BS and US (each of them 37.50%) and that of TP was related to spindle shape (62.50%) (Table 3).

Chi-square test showed that there is no statistically significant relationship between anatomical variation and age. Because one cell had less than 5 counts, and sample size was higher than 40, Fisher's Exact Test was

used to interpret the results (Fisher's Exact Test =12.585, P-value=0.182) (Table 4).

Chi-square test showed that there is no statistically significant relationship between anatomical variation and gender. Because one cell had less than 5 counts, and sample size was higher than 40, Fisher's Exact Test was used to interpret the results (Fisher's Exact Test =0.168, P-value=0.952) (Table5).

## Discussion:

Tori are nodular protuberances that are composed of mature bone, these are usually considered an anatomical variation rather than a pathological condition. The size of the tori can change throughout life, and may range from a few millimeters to centimeters. An increase in size may be observed in the early adulthood, but it may show a decrease in size in the older age-group due to bone resorption. (13) The prevalence rates of TP and TM diversify in populations with contrasting ethnic origins from 0% to 66% and from 0% to 85.7%, respectively. (14, 15) The prevalence of tori is currently unknown in the Arab ethnic group. However, Salem et al reported a 1.4% prevalence of TP in 6–12-year-old Saudi school children, and Yildiz et al reported a 30.9% prevalence rate of TP in 5–15-year-old Turkish school children. (16, 17) Kumar Singh A et al. reported a 73.5% prevalence rate in Malaysia. (18)

The prevalence of TP and TM was reported 5.17% in Saudi Arabia in 2016. (1) In this study reported a 17.29% frequency of tori. Mean age of subjects was  $43.31 \pm 16.87$  years. The mean age was  $42.79 \pm 15.94$  years for males and  $43.66 \pm 17.66$  years for females,

which was not statistically different ( $P=0.796$ ). TP is observed to be most prevalent in females in comparison to males, and this was attributed to a dominant type, X chromosome. (19) Hiremath et al. (20) and Sathyaetal et al. (21) found that TP and TM are more prevalent in females than males. In study performed by Kumar singh (18) also the prevalence of TP alone was higher in females. Similar results were observed in our study however there was no significant relationship between gender and tori prevalence ( $P\text{-value}=0.952$ ). However, according to the findings of Patil et al and Sonnier et al. (32, 33) TM was reported to be more prevalent in males. Some authors have also reported no significant differences in the prevalence of TM between genders. (22) The researches in the past have suggested that the incidence of tori is related to the age difference. Kerdpon (23), Jankittivong (24), and Yildiray (25), have revealed higher prevalence rates of TP during the second and third decades of life (17, 23, 24), and few suggest that highest prevalence rate is observed during the fifth decade. (26, 27) On the other hand, in our study similar to studies performed by AlZarea, Chohayed, and Volpes (13, 28) there is no significant relationship between incidence of tori and age difference. According to the shape, TP can be classified as at, spindle-shaped, nodular, and lobular, whereas TM can be classified as unilateral and bilateral solitary, unilateral and bilateral multiple, and bilateral combined. The flat-shaped tori were reported to be more commonly seen in the present study (41.46%), followed by spindle-shaped tori. (16, 29, 34) However, Simunković et al,

Jankittivong et al, and Reichart et al showed a higher prevalence of spindle-shaped tori (24, 30, 31), Haugen found that nodular TP was core common. (27) Bilateral solitary type of TM was most commonly observed in this study, which was similar to the observations by Reichart et al, Patil et al, and Sonnier et al. (31, 32, 33) In this study there was no significant relationship between anatomical variation, age difference and gender ( $P=0.182$ ,  $P=0.952$ ). Dietary factors may have a role for the tori prevalence. Eggen and Natvig (35) investigated the influences of nutrients in the etiology of tori. It was suggested that saltwater fish consumption in Norway possibly supplies higher levels of polyunsaturated fatty acids and Vitamin D which is involved in bone growth and this may increase the prevalence of tori.

### **Conclusion:**

The results of study show that the prevalence of tori in Iranian population is 17.29% and the incidence of tori is higher in females when compared to males, which is however not significant. TM was significantly more prevalent in both genders. There is no significant relationship between incidence of tori and age difference. Most TP were found in flat shape (41.46%), and the highest prevalence of TM was related to BS (42.11%).

### **Acknowledgement:**

Student research proposal with the code 48 adopted on June 25, 2018. The authors would like to thank and appreciate the Deputy of Research and Technology of Mazandaran University of medical sciences

for financial support, and also Mazandaran student research committee.

## References:

1. Smitha K, Smitha GP. Alveolar exostosis revisited: a narrative review of the literature. *Saudi J Dent Res.* 2015;6(1):67–72.
2. Nogueira AS, Gonçalves ES, da Silva Santos PS, Damante JH, Alencar PN, Sampaio FA, Garcia AS. Clinical, tomographic aspects and relevance of torus palatinus: case report of two sisters. *Surgical and Radiologic Anatomy.* 2013 Nov 1;35(9):867-71.
3. Woo JK. Torus palatinus. *American journal of physical anthropology.* 1950 Mar 1;8(1):81-112.
4. Simunkovi? SK, Bozi? M, Alajbeg IZ, Dulci? N, Boras VV. Prevalence of torus palatinus and torus mandibularis in the Split-Dalmatian County, Croatia. *Coll Antropol.* 2011;35:637–641.
5. Reichart PA, Neuhaus F, Sookasem M. Prevalence of torus palatinus and torus mandibularis in Germans and Thais. *Commun Dent Oral Epidemiol.* 1988;16:61–64.
6. Simunkovi? SK, Bozi? M, Alajbeg IZ, Dulci? N, Boras VV. Prevalence of torus palatinus and torus mandibularis in the Split-Dalmatian County, Croatia. *Coll Antropol* 2011;35:637-41.
7. Haugen LK. Palatine and mandibular tori. A morphologic study in the current Norwegian population. *Acta Odontol Scand* 1992;50:65-77.
8. Reichart PA, Neuhaus F, Sookasem M. Prevalence of torus palatinus and torus mandibularis in Germans and Thai. *Community Dent Oral Epidemiol* 1988;16:61-64.
9. Gorsky M, Bukai A, Shohat M. Genetic influence on the prevalence of torus palatinus. *Am J Med Genet* 1998;75:138–140.
10. King DR, Moore GE. The prevalence of torus palatinus. *J Oral Med* 1971;26:113-115.
11. Jankittivong A, Apinhasmit W, Swadison S. Prevalence and clinical characteristics of oral tori in 1,520 Chulalongkorn University Dental School patients. *Surg Radiol Anat* 2007;29:125-131.
12. AlZarea BK. Prevalence and pattern of torus palatinus and torus mandibularis among edentulous patients of Saudi Arabia. *Clinical interventions in aging.* 2016;11:209.
13. AlZarea BK. Prevalence and pattern of torus palatinus and torus mandibularis among edentulous patients of Saudi Arabia. *Clinical interventions in aging.* 2016;11:209.
14. Sawair FA, Shayyab MH, Al-Rababah MA, Saku T. Prevalence and clinical characteristics of tori and jaw exostoses in a teaching hospital in Jordan. *Saudi medical journal.* 2009;30(12):1557-62.
15. Pechenkina EA, Benfer Jr RA. The role of occlusal stress and gingival infection in the formation of exostoses on mandible and maxilla from Neolithic China. *HOMO-Journal of Comparative Human Biology.* 2002;53(2):112-30.

16. Yildiz E, Deniz M, Ceyhan O. Prevalence of torus palatinus in Turkish schoolchildren. *Surgical and Radiologic Anatomy*. 2005;27(5):368-71.
17. Salem G, Holm S, Fattah R, Basset S, Nasser C. Developmental oral anomalies among schoolchildren in Gizan region, Saudi Arabia. *Community dentistry and oral epidemiology*. 1987;15(3):150-1.
18. Singh AK, Ramachandra SS, Arora S, Dicksit DD, Kalyan C, Singh P. Prevalence of oral tori and exostosis in Malaysian population—A cross-sectional study. *Journal of oral biology and craniofacial research*. 2017;7(3):158-60.
19. García-García AS, Martínez-González J-M, Gómez-Font R, Soto-Rivadeneira Á, Oviedo-Roldán L. Current status of the torus palatinus and torus mandibularis. *Med Oral Patol Oral Cir Bucal*. 2010;15(2):e353-60.
20. Hiremath V, Husein A, Mishra N. Prevalence of torus palatinus and torus mandibularis among Malay population. *Journal of International Society of Preventive & Community Dentistry*. 2011;1(2):60.
21. Sathya K, Kanneppady SK, Arishiya T. Prevalence and clinical characteristics of oral tori among outpatients in Northern Malaysia. *Journal of oral biology and craniofacial research*. 2012;2(1):15-9.
22. Martínez-González J. Benign tumors of the maxilla. *Cirugía Bucal Patología y Técnica* 2nd edn Barcelona: Masson. 1998:627-39.
23. Kerdpon D, Sirirungrojying S. A clinical study of oral tori in southern Thailand, prevalence and the relation to parafunctional activity. *European Journal of Oral Sciences*. 1999;107(1):9-13.
24. Jankittivong A, Apinhasmit W, Swasdison S. Prevalence and clinical characteristics of oral tori in 1,520 Chulalongkorn University Dental School patients. *Surgical and Radiologic Anatomy*. 2007;29(2):125-31.
25. Sisman Y, Ertas ET, Gokce C, Akgunlu F. Prevalence of torus palatinus in cappadocia region population of Turkey. *European journal of dentistry*. 2008;2:269.
26. Al-Bayaty H, Murti P, Matthews R, Gupta P. An epidemiological study of tori among 667 dental outpatients in Trinidad & Tobago, West Indies. *International dental journal*. 2001;51(4):300-4.
27. Haugen LK. Palatine and mandibular tori: a morphologic study in the current Norwegian population. *Acta Odontologica Scandinavica*. 1992;50(2):65-77.
28. Chohayeb A, Volpe A. Occurrence of torus palatinus and mandibularis among women of different ethnic groups. *American journal of dentistry*. 2001;14(5):278-80.
29. King D. Incidence of tori in three population groups. *Journal of oral medicine*. 1981;36:21-3.
30. Kraljević Šimunković S, Božić M, Z Alajbeg I, Dulčić N, Vučićević Boras V. Prevalence of torus palatinus and torus mandibularis in the Split-Dalmatian County, Croatia. *Collegium antropologicum*. 2011;35(3):637-41.

31. Reichart PA, Neuhaus F, Sookasem M. Prevalence of torus palatinus and torus mandibularis in Germans and Thai. *Community Dentistry and Oral Epidemiology*. 1988;16(1):61-4.

32. Patil S, Maheshwari S, Khandelwal SK. Prevalence of torus palatinus and torus mandibularis in an Indian population. *Saudi Journal of Oral Sciences*. 2014;1(2):94.

33. Sonnier KE, Horning GM, Cohen ME. Palatal tubercles, palatal tori, and mandibular tori: prevalence and anatomical

features in a US population. *Journal of periodontology*. 1999;70(3):329-36.

34. Chao P-J, Yang H-Y, Huang W-H, Weng C-H, Wang I, Tsai AI, et al. Oral tori in chronic hemodialysis patients. *BioMed research international*. 2015;2015.

35. Eggen S, Natvig B. Variation in torus mandibularis prevalence in Norway A statistical analysis using logistic regression. *Community dentistry and oral epidemiology*. 1991;19(1):32-5.

## Tables and Figures:

**Table 1:** Distribution of torus palatinus and torus mandibularis according to gender

		Gender					
		Female		Male		Total	
		Frequency	Percent	Frequency	Percent	Frequency	Percent
	<b>TP</b>	24	37.50%	17	40.48%	41	38.68%
	<b>TM</b>	35	54.69%	22	52.38%	57	53.77%
	<b>TP and TM</b>	5	7.81%	3	7.14%	8	7.55%

TP: torus palatinus, TM: torus mandibularis

**Table 2:** Distribution of torus palatinus and torus mandibularis according to age

		TP_TM					
		TP		TM		TP and TM	
		Frequency	Percent	Frequency	Percent	Frequency	Percent
Age	<b>12-19</b>	5	12.20%	6	10.53%	1	12.50%
	<b>19-29</b>	6	14.63%	7	12.28%	1	12.50%
	<b>29-39</b>	4	9.76%	13	22.81%	2	25.00%
	<b>39-49</b>	7	17.07%	10	17.54%	1	12.50%
	<b>49-59</b>	14	34.15%	7	12.28%	3	37.50%
	<b>59&lt;</b>	5	12.20%	14	24.56%	0	0.00%

**Table 3:** Distribution of torus palatinus and torus mandibularis according to shape

		TP		TM		TP and TM	
		Frequency	Percent	Frequency	Percent	Frequency	Percent
<b>TP_Shape</b>	<b>Spindle</b>	12	29.27%	0	0.00%	5	62.50%
	<b>Flat</b>	17	41.46%	0	0.00%	2	25.00%
	<b>Lobular</b>	6	14.63%	0	0.00%	1	12.50%
	<b>Nodular</b>	6	14.63%	0	0.00%	0	0.00%
<b>TM_Kind</b>	<b>US</b>	0	0.00%	18	31.58%	3	37.50%
	<b>BS</b>	0	0.00%	24	42.11%	3	37.50%
	<b>BM</b>	0	0.00%	8	14.04%	1	12.50%
	<b>UM</b>	0	0.00%	5	8.77%	1	12.50%
	<b>BC</b>	0	0.00%	2	3.51%	0	0.00%

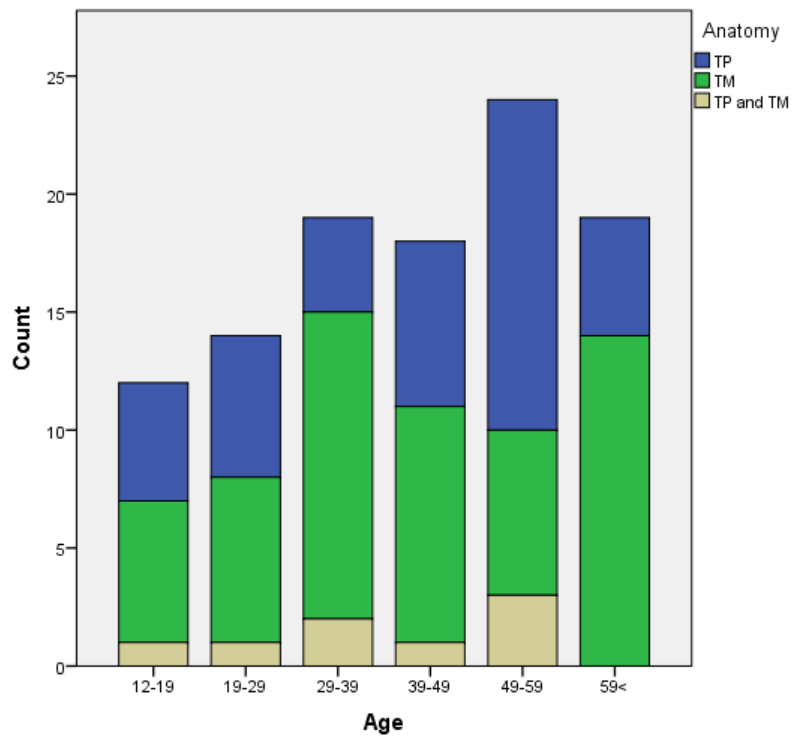
**Table 4:** Chi-square table of anatomical variation and age

			TP_TM			Total
			TP	TM	TP and TM	
<b>Age</b>	<b>12-19</b>	Count	5	6	1	12
		Expected Count	4.6	6.5	0.9	12.0
		% within Age	41.7%	50.0%	8.3%	100.0%
	<b>19-29</b>	Count	6	7	1	14
		Expected Count	5.4	7.5	1.1	14.0
		% within Age	42.9%	50.0%	7.1%	100.0%
	<b>29-39</b>	Count	4	13	2	19
		Expected Count	7.3	10.2	1.4	19.0
		% within Age	21.1%	68.4%	10.5%	100.0%
	<b>39-49</b>	Count	7	10	1	18
		Expected Count	7.0	9.7	1.4	18.0
		% within Age	38.9%	55.6%	5.6%	100.0%
	<b>49-59</b>	Count	14	7	3	24
		Expected Count	9.3	12.9	1.8	24.0
		% within Age	58.3%	29.2%	12.5%	100.0%
<b>59&lt;</b>	Count	5	14	0	19	
	Expected Count	7.3	10.2	1.4	19.0	
	% within Age	26.3%	73.7%	0.0%	100.0%	
<b>Total</b>	Count	41	57	8	106	
	Expected Count	41.0	57.0	8.0	106.0	
	% within Age	38.7%	53.8%	7.5%	100.0%	



**Table 5:** Chi-square table of anatomical variation and gender

			TP_TM			Total
			TP	TM	TP and TM	
Gender	Female	Count	24	35	5	64
		Expected Count	24.8	34.4	4.8	64.0
		% within Gender	37.5%	54.7%	7.8%	100.0%
	Male	Count	17	22	3	42
		Expected Count	16.2	22.6	3.2	42.0
		% within Gender	40.5%	52.4%	7.1%	100.0%
Total		Count	41	57	8	106
		Expected Count	41.0	57.0	8.0	106.0
		% within Gender	38.7%	53.8%	7.5%	100.0%



**Figure 1:** Bar chart of anatomical variation by age