

Original Article

Korean Red Ginseng Root Aqueous Extract with an Effective Impact on Wound Healing in Rats

Mohammad Reza Sabahi¹, Mehdi Nouredini², Mehrdad Taghipour^{3*}, Hamid Reza Banafsheh⁴, Seyed Mohammad Sajad Sajadian⁵.

1. Department of General Surgery, Qom University of Medical Sciences, Qom, Iran

2. Physiology Research Center, Kashan University of Medical Science, Kashan, Iran.

3. Department of General Surgery, Hamadan University of Medical Sciences, Hamadan, Iran

4. Addiction studies group, Kashan University of Medical Science, Kashan, Iran

5. Student Research committee, Kashan University of Medical Science, Kashan, Iran.

*correspondence: **Mehrdad Taghipour**, Department of General Surgery, Besat Hospital, Hamadan University of Medical Sciences, Hamadan, Iran. Email: mehrdadtaghipour@gmail.com

Abstract:

Introduction: There were some reports about the positive effects of some Korean red ginseng root extract ingredients on wound healing. The present study was designed to examine the effect of whole Korean red ginseng root extract ingredients on incisional wound healing and tissue tension in rats.

Methods: In this experimental study, 80 rats (Sprague Dawley, 200-250 gr) randomly divided into four groups. In day 0 a full thickness circular wound was made on the backs of these rats. They were divided into these receiver groups: Eucerin (control) and Korean red ginseng root extract (1, 10, 100 µg/ml) in Eucerin base were administrated daily. For tissue tension measurement 5 rats in each group were selected in days of 6, 12 and 18 after anesthesia skin incision 2 cm × 1 cm was done and tissue tensile was measured with tensiometer and data was compared by SPSS with one-way ANOVA and Tukey (P<0.05).

Findings: In this study, we had better wound healing in extract treated groups (depending on the dose) in comparison with the control group and the receiver of 100 micrograms of the extract was significantly the best.

Conclusion: Korean red ginseng root extract can be used as a medication for wound healing; probably its mechanism is increasing fibroid tissue.

Keywords: Ginseng, Wound Healing, Tissue tension, Incisional wound.

Introduction:

Wound is a physical injury result in skin opening or breaking (1). There are several types of wounds such as traumatic, surgical and chronic. Two categories of wounds exist, partial and full thickness. Full-thickness wounds involve a loss of deeper

layers of skin and fat that vessels disrupt and scar produce when healed (2). Wound healing or regeneration is a recovery process emerging after the skin and other tissues lesion (3). This process is a dynamic phenomenon depending upon the biochemical, physiological and morphological changes and interactions. The

wound healing includes three phases of inflammation, proliferation and maturity. Inflammation phase is the body's response to limit damage and prevent further damage. Proliferation phase includes epithelial reconstruction and neovascularization to relieve trauma-induced ischemia. At this stage, granulation tissue is formed. The proliferation phase occurs approximately on four to twelve days. During this period, tissue continuity is established (4). Maturity phase is associated with scar formation, production of collagen cross networks, the resulting shrinkage and edema loss (5).

The prolongation of wound healing is one of the main and common problems of the patients admitted in hospitals (6-5). Recently, many efforts have been done to speed up wound healing process. Reduced infection and angiogenesis and increased cell growth are useful in wound healing (7-9). A variety of medicines and ointments are used for healing the open wound each of which has many constraints and deficiencies (10). A simple model is a basic requirement for the effects of different external factors analysis on skin-wound healing.(11) In clinical trials, the most commonly reported in wounds property is wound area. For providing a highly accurate wound area measurement many studies have compared different modalities of measuring this parameter (12). Photographic studies planimetry and tracing the wound onto a paper block and then counting blocks (12-17). Mechanical strength and integrity of a wound is determined by the amount and quality of as-precipitated collagen. The formation of microfilaments and their cross junctions result in reduced solubility of

collagen and increased the strength of the underlying collagen compared to enzymatic degradation. Scar rearrangement eventually causes a mature scar devoid of vessels and cells. The mechanical strength of scar will not reach that of a healthy tissue. The restoration of the strength of a tissue is an important aspect of wound healing. This process requires the deposition of appropriate amounts of extracellular matrix components, particularly collagen fibers in the wound area. It is likely that both structural changes in the collagen and its lower concentration measured by morphometric analysis could explain changes in the breaking strength measurement (5,18).

Red Ginseng root (*Panax ginseng* CA Meyer) is a slow-growing perennial plant with fleshy roots, belonging to the genus *Panax* of the family Araliaceae (19). Red Ginseng root extracts have been used as a topical medication for skin wound, atopic dermatitis and skin inflammation. Ginseng physiological action on the skin is not yet well understood. It has been reported that ginsenoside Rb1 in burning wound causes healing probably because of increasing collagen synthesis and inhibiting metalloproteinase expression. Ginsenoside Rb1 and Rb2 causes inhibiting angiogenesis (20,21). Ginsenoside Rg1 promoted functional neovascularization proliferation (22-23).

As mentioned before there was reported paradoxical effects of some ginsenosides on neovascularization of proliferation phase (20-23). Thus, we examined the effects of total ginseng saponins on wound healing and

tissue tension using a full-thickness incisional wound in rats.

Methods:

Study protocol:

This is an experimental study in which 80 healthy male rats of Sprague Dawley type weighing 250 ± 50 gr were randomly selected. The rats were anesthetized with an intraperitoneal injection of ketamine/xylazine. Then hair between the neck and thorax was first cut by shaving machine. Thereafter, the area was cleaned by a shaving razor. The rats were fixed with adhesive tape on the surgical table. The area was marked using a circular template with a diameter of 2 cm. To create a skin lesion, first a small incision was created on marked lines using a scalpel, then the skin was separated from the fascia by small surgical straight scissors. After that, the skin was exactly incised from the marked area by surgical tweezers. Finally, the wound was disinfected with betadine.

The rats were divided into four groups of 20 subjects. The wound was dressed up daily for 19 days by 1 ml of ointments containing 1, 10 or 100 $\mu\text{g/ml}$ of aqueous extract of Korean red ginseng root (experimental groups 1, 2, 3) or Eucerin ointment (negative control). On days 1, 3, 5, 7, 9, 11, 13, 15, 17 and 19; rats were anesthetized by ether and the wound was photographed by a digital camera; to have a fixed similar distance between the place of wound and camera, the camera was located on a fixed base which was designed. The wound area was calculated using a software (Digimizer 4.2 free trial Ostend, Belgium) upon taking

the photos (24,25). To evaluate the tissue tension and histological study of skin, 5 rats from each group were selected on 6, 12 and 18 days. After anesthetizing with ether, the rats' heads were cut with a guillotine. Then, a strip of wounded skin with two-centimeter-long and one centimeter wide (0.5 cm width of normal tissue and 0.5 cm wide of newly resorted scar tissue) was cut. The tissue tension was measured using a Tensiometer device (Boal, England (25,26).

To evaluate histological changes, the tissue samples fixed in 10% formalin phosphate-buffered, processed and then were paraffin embedded. By using a microtome (Olympus, USA) the specimens were cut at 5 μm intervals to the wound surface long. Hematoxylin and eosin staining was used to visualize the gross microscopic cellular architecture. Light microscopy (Olympus-DP25 and Olympus-BX51BX51, USA) was used for pathological change evaluations such as tissue formation and reepithelization.

Preparation of plant extracts:

After collecting and identifying the plant by Kashan Botanical Garden (HN), the roots powdered and dried at room temperature. Soxhlet apparatus was used for extraction. The extracts from the seed powder were five percent. A certain amount of extract was dissolved in water, and then it was mixed with Eucerin to prepare ointments with a concentration of 1, 10 and 100 $\mu\text{g/ml}$.

Drugs and solutions:

The following drugs were used: ketamine, rompun (Sigma-Aldrich, USA), Eucerin

(Iran), Normal saline (Iran). Stock solutions of the Korean red ginseng root aqueous extract in different concentrations (1, 10, 100, $\mu\text{g/ml}$) were prepared with mixed water and Eucerin.

Ethical considerations:

All the experiments were performed in accordance with the guidelines for the Care and Use of Laboratory Animals prepared by the Institute of Laboratory Animal Resources and published by the National Institutes of Health (NIH Publication No. 86-23, Revised 1985), and was approved by the Animal Research Committee in our university.

Statistical analysis:

All data are expressed as Mean \pm SEM and N is represented as the number of rats in each group. Comparisons were made using one way and repeated measures ANOVA followed by Tukey post hoc test and Least Significant Difference (LSD) test at the significance level of $p < 0.05$ for all experiments.

Findings:

The effect of Korean red ginseng root extracts on wound area:

In all groups had no statistically significant difference regarding the wound area on day one. On day three, the wound area significantly increased as compared to day one in control group. ($P < 0.01$) but in the extracts group, the wound area decreased as compared to day one. The wound area in the group treated extract of Korean red ginseng root (1 $\mu\text{g/ml}$) ointment was significantly smaller as compared to the control group on

days three ($P < 0.01$), 5 ($P < 0.05$) and 7 ($P < 0.01$). The wound area in the group treated using the aquatic extract of Korean red ginseng root (10 $\mu\text{g/ml}$) ointment was significantly smaller as compared to the control group on day 15 ($P < 0.05$). The wound area in the group of Korean red ginseng root (100 $\mu\text{g/ml}$) ointment was significantly smaller as compared to the control group on days three ($P < 0.05$) and 11 to 17 ($P < 0.01$, $P < 0.001$). No significant difference was observed between 10 $\mu\text{g/ml}$ extract group as compared to 1 $\mu\text{g/ml}$ Korean red ginseng root extract in the wound area. On days 15 and 17, the wound area was significantly further in the group treated using 1 $\mu\text{g/ml}$ extract ointment as compared to the group treated with 100 $\mu\text{g/ml}$ extract ($P < 0.05$, $P < 0.001$). The wound area was larger in the group treated with the ointment containing 10 $\mu\text{g/ml}$ extract as compared to 100 $\mu\text{g/ml}$ extract but it was significant only on day 15 ($P < 0.01$) (Figure 1&2).

In control group the wound area on day 19 reached $< 0.2\text{cm}^2$. In one and ten microgram per milliliter extract groups wound area reached $< 0.2\text{cm}^2$ on day 17. On day 15, the wound area using the aquatic extract of Korean red ginseng root (100 $\mu\text{g/ml}$) ointment reached $< 0.2\text{cm}^2$ (Figure 3).

Histological study:

Histological studies results showed an improvement in wound healing by the time. This improvement was quicker with the Korean red ginseng root ointment. On the 6th day of treatment with Korean red ginseng, in most samples reconstruction of the epidermis was initiated), whereas in control group, foci of necrosis were still observable. In all groups, fibrinoid tissue was increased by the time but in Korean red

ginseng root extracts the fibrinoid tissue accumulation were more (dose-dependently) (Figure 4).

The effect of Korean red ginseng root extracts on tissue tension:

The results showed that the tissue tension increased significantly from day 6 to day 12 in control group ($P < 0.001$). On day 18, the tissue tension decreased significantly compared to day 12 ($P < 0.001$) (Figure 5). The topical ointment containing aqueous extract of Korean red ginseng root with a dose of 1 $\mu\text{g/ml}$ resulted in increased tissue tension over the time and reached its maximum value on day 18 (2.46 kg). The tissue tension in the group treated with an ointment containing aqueous extract of Korean red ginseng root (1 $\mu\text{g/ml}$) was significantly higher than the control group on days 6 and 18 ($P < 0.01$). The ointment containing 10 $\mu\text{g/ml}$ of the aqueous extract of Korean red ginseng root increased the tissue tension of wound on days of experiment. The maximum tissue tension was recorded on day 18 (2.98 kg). The tissue tension in the group treated with the ointment containing 10 $\mu\text{g/ml}$ of aqueous extract of Korean red ginseng root was significantly higher than the control group on all days ($P < 0.001$). The topical ointment containing 100 $\mu\text{g/ml}$ of aqueous extract of Korean red ginseng root significantly increased the tissue tension in days 6 to 18. The tissue tension reached its maximum value (2.74 kg) on day 12. The tissue tension was significantly higher than the control group in topical ointment containing 100 $\mu\text{g/ml}$ of aqueous extract in all days ($P < 0.01$, $P < 0.001$). Despite the loss of tissue tension in Eucerin group on day 18, the aqueous extract of Korean red ginseng root in the dose of 100 $\mu\text{g/ml}$ prevented loss of

tissue tension like the groups treated with a dose of 1 and 10 $\mu\text{g/ml}$. The tissue tension increased over time in all three groups treated with an ointment containing 1, 10 and 100 $\mu\text{g/ml}$ of Korean red ginseng root extract. The tissue tension in 10 $\mu\text{g/ml}$ extract group was significantly higher than the 1 $\mu\text{g/ml}$ extract group on days 6 and 12 ($P < 0.001$, $P < 0.01$). The tissue tension in 100 $\mu\text{g/ml}$ of extract was significantly higher than 1 $\mu\text{g/ml}$ extract group on days 6 and 12 ($P < 0.01$). The tissue tension in 100 $\mu\text{g/ml}$ extract group was the same in 6 and 18 day and significantly lower than the 10 $\mu\text{g/ml}$ extract group only on day 12 ($P < 0.001$) 10 $\mu\text{g/ml}$ of Korean red ginseng root extract was the best dose of tissue tension (Figure 5).

Discussion:

In the present study, it was indicated that the 19-day application of the aquatic extract of Korean red ginseng root extract (100 $\mu\text{g/ml}$) ointment on the wound was better in healing the wound and reducing the wound area as compared to the other doses (1&100 $\mu\text{g/ml}$) of the same extract and Eucerin. Wound healing process includes different steps; each consists of several other steps with some of them overlap and cannot be distinguished easily (27,28). Hence, the quantitative and qualitative progress of each step can lead to the acceleration of wound healing and the reduction of its conditions. Control ointment cannot lead to the wound healing on the first days as done extract ointments.

Angiogenesis is a complicated process and depends on wound forming matrix, growth stimulating factors, and endothelial cells migration. Among these factors, Vascular

endothelial growth factor (VEGF) and Transforming growth factor beta (TGF- β) are the most important (29,30). In one study aqueous extract of Korean red ginseng root stimulated angiogenesis with VEGF increased (31). It is noteworthy that, unlike the extract-receiving groups, wound area in the Eucerin group was increased at the third day in our study. In other studies, previously performed on incision wound, increased wound area was also seen in all control and experimental groups at first few days of wound formation; this can be justified by the natural procedure of wound healing, i.e. temporal matching with the inflammatory phase of wound healing. In addition to inflammation, skin and muscles tension are effective on increasing wound area. Furthermore, the wound is more susceptible to infection in early days which in turn may increase wound area (32,33).

In our study, increased wound area was seen only in control group, while wound area was decreased in the extract-containing groups; this can be attributed to the reduced inflammation due to steroid property of all Ginsengoids except for R0 (34,35).

One of the factors contributing to wound healing is tensile strength of skin after healing; closer the tension to the normal amount, better healing and higher density of collagen tissue. Various studies have been carried out on the effects of medicinal herbs on the tensile strength index of wound healing so far; in one study showed that a 5% extract of goosefoot had a better tensile stretch impact than control after healing and this difference was significant (28). In another study, they investigated the impact

of the mummy on healing of incision wound in rats and found that the amount of tensile stretch in the experiment group (1271 g) was significantly higher than the control group on the seventh day (25). In another study, the tensile strength was significantly higher in the fundermol group than the physiologic serum group (35). Tensile strength was not measured in studies performed on red ginseng so far. Our study showed that the highest amount of tensile strength was seen in the treatment groups as well as in negative control group relating to the extract 10 of ginseng root, with an amount of 2.8 kg; in this regard, it had a significant difference with other groups. Wound tension was increased from the day six to the day eighteen and the maximum tensile stretch was seen in the groups 1 and 10 at the 18th day.

The maximum tension was in the extract group 100 at the day 12 and from then, wound tension decreased. In a study, red ginseng root was effective in the synthesis of collagen type one which is the main compound in strengthening of the dermis and the main collagen involved in wound healing (36). It seems that the doses 10 $\mu\text{g/ml}$ and 100 $\mu\text{g/ml}$ increase collagen synthesis more than the dose 1 $\mu\text{g/ml}$, however, the dose 100 $\mu\text{g/ml}$ reduced tensile strength from the day 12 possibly due to toxic effect or irregular accumulation of collagen fibers. On the other side, given the better effect of dose 100 $\mu\text{g/ml}$ in the first days in decreasing wound area, this effect may be attributed to both increased collagen synthesis and angiogenesis. In the control group, it increased tensile strength until the 12th day, so that the tensile strength was

approximately equal to the extract 1 µg/ml and lower than the extracts 10 µg/ml and 100 µg/ml at the day 12; this difference was significant. At the 18th day, the extract group 1 µg/ml had a significantly higher tension than the control group. Since the wound area in the extract group 1 µg/ml was similar to the control group until the day 12 and significantly lower at the days 13 and 15, it can conclude that collagen had possibly an increased role in tension after the day 12. At the 18th day, the tensile stretch decreased in comparison with previous days in all groups except for the groups 1 and 10 µg/ml. At this day, reduction of tensile strength is noteworthy in the Eucerin group and its abrupt increase at the 12th day may arise from an irregular accumulation of collagen fibers. Interestingly the cause of lower tension may be attributed to the existence of colloid tissue during the first few days.

Conclusion:

Based on the present study, it was indicated that the aquatic extract of Korean red ginseng root ointment improves wound healing process. We can suggest two possible mechanisms for this improvement: stimulating the growth and activity of fibroblast and the enhancement of wound strength. Further studies are needed to clarify the exact mechanisms.

References:

1. Baranoski S, Ayello E. Wound Care Essentials: Practice Principles. 2nd ed. Philadelphia: Lippincott Williams & Wilkins; 2007.
2. Sussman C, Bates-Jensen B. Wound Care: A Collaborative Practice

Manual for Health Professionals (Sussman, Wound Care). 4th ed. Philadelphia: Lippincott Williams & Wilkins; 2011.

3. Ferguson MW, Leigh IM. Wound healing textbook of dermatolog. Blackwell Science 1998;1:337-43.

4. Mescher, Anthony L., Luiz Carlos Uchôa Junqueira. Junqueira's Basic Histology: Text and Atlas. Thirteenth edition. New York: McGraw Hill Medical., 2010:404-25.

5. Townsend, Courtney M., and David C. Sabiston. Sabiston Textbook of Surgery: 2001:85-91.

6. Brunicaudi, F Charles; Andersen, Dana K; Billiar, Timothy R; Dunn, Schwartz's principles of surgery Tenth edition. New York : McGraw-Hill Education: 345-69

7. W.Way L. Current surgical diagnosis & treatment.Lange Ed.4. New YorkL Lange Medical Books/McGraw-Hill, 2010:458-62.

8. Ning Xu Landén, Dongqing Li, Mona Ståhle. Transition from inflammation to proliferation: a critical step during wound healing. Cell Mol Life Sci 2016;73:3861-3885.

9. Sørensen LT. Wound healing and infection in surgery: the pathophysiological impact of smoking, smoking cessation, and nicotine replacement therapy: a systematic review. Ann Surg 2012;255:1069-79.

10. Sewall G, Robertson K, Connor N, Heisey D, Hartig G. Effect of topical mitomycin on skin wound contraction. Arch Facial Plast Surg 2003;5:59-62

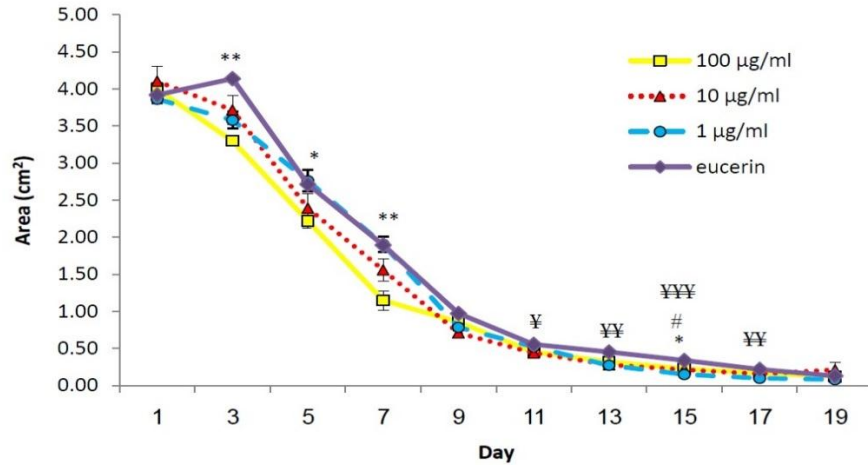
11. Charles H. Wound assessment: measuring the area of a leg ulcer. Br J Nurs 1998;7:765e768, 770, 772.

12. Bulstrode CJ, Goode AW, Scott PJ. Stereophotogrammetry for measuring rates of cutaneous healing: a comparison with conventional techniques. *Clin Sci (Lond)*. 1986;71:437e443
13. Cutler NR, George R, Seifert RD, Brunelle R, Sramek JJ, McNeill K, et al. Comparison of quantitative methodologies to define chronic pressure ulcer measurements. *Decubitus* 1993;6:22e30.
14. Etris MB, Pribble J, LaBrecque J. Evaluation of two wound measurement methods in a multi-center, controlled study. *Ostomy Wound Manage* 1994;40:44e48.
15. Griffin JW, Tolley EA, Tooms RE, Reyes RA, Clift JK. A comparison of photographic and transparency-based methods for measuring wound surface area. *Phys Ther* 1993;73:117e122
16. Liskay AM, Mion LC, Davis BR. Comparison of two devices for wound measurement. *Dermatol Nurs* 1993;5:437e441, 434.
17. Bohannon RW, Pfaller BA. Documentation of wound surface area from tracings of wound perimeters. Clinical report on three techniques. *Phys Ther* 1983;63:1622e1624.
18. Minossi J, Lima Fde O, aramori C, Hasimoto C, rtolan E, Rodrigues P. Alloxan diabetes alters the tensile strength, morphological and morphometric parameters of abdominal wall healing in rats. *Acta Cir Bras* 2014;29:118-24
19. Ha, H., Yamamoto, M., Joo, C.N. & Kuo, S.-C. Current status of Ginseng research in Japan. In: *Proceedings of the International Symposium on Ginseng Research*, ROC, ed pp. 12–26. Taichuu: Life Medical Research Institute, China Medical College.
20. Kimura Y, Sumiyoshi M, Kawahira K, Sakanaka M. Effects of ginseng saponins isolated from Red Ginseng roots on burn wound healing in mice. *Br J Pharmacol* 2006;148:860-70. Epub 2006 .
21. Choi,s. Epidermis proliferative effect of the Panax ginseng ginsenoside Rb2. *Arch. Pharm. Res* 2002;25:71-77.
22. Kenarova B, Neychev H, Hadjiivanova C, Petkov V. Immunomodulating activity of ginsenoside Rg1 from Panax ginseng. *Jpn J Pharmacol* 1990:447-54.
23. Sengupta, S., Toh, S.-A., Sellers, L.A., Skepper, J.N., Kollwijk, P., Leung, H.W., et al. Modulating angiogenesis The Yin and the Yang in Ginseng. *Circulation* 2004;110:219- 1225.
24. Shoohani B, Hemati AA, Taheri Moghadam M. Effects of Scrophularia striata Extract on Wound Healing in Rabbit. *Ilam Uni Med Sci J* 2009;17:9-16.
25. Rezvanipour M, Pourzadehhosseini F, Malekpour R, Zarabi A. Mummy effects on some parameters involved in wound healing in mice. *Kerman University of Medical Sciences Journal* 2007;14:267-77
26. Pravinkumar B, Yogita M, Kuldee B. Reversal by quercetin of corticotrophin releasing factor induced anxiety and depression like effect in rat. *Prog Neuro-Psychopharmacol Biolog Psychiatry* 2010;34:955-60.
27. Champion RH, Burton JL, Burns DA, Breathnach SM. *Textbook of dermatology*. 1998:337-9.

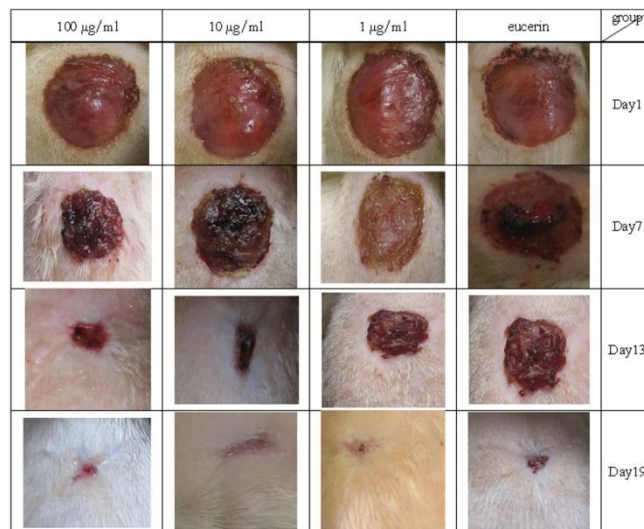28. AllahTavakoli M, Arab Bani Assad F, Mahmoudi M, Jafari H, Tavakolian v, et al. Effect of Artemisia extract on cutaneous wound healing in rats. Mazandaran University of Medical Sciences 2010;20:7076
29. Heldin C-H WB. The molecular and cellular biology of wound repair. 2ed ed. : Plenum Press; 1996.
30. Madri J, Sankar S, Romanic A. The molecular and cellular biology of wound repair. 2nd ed. New York:
31. Young-Mi K, Seung N, Young-Gab Y, Hee-Do H, Young-Chul L, Kwon-Soo H, etc. Water Extract of Korean Red Ginseng Stimulates Angiogenesis by Activating the PI3K/Akt-Dependent ERK1/2 and eNOS Pathways in Human Umbilical Vein Endothelial Cells. Biol Pharm Bull 2007;30:1674-1679.
32. Jarrahi M, Vafaei AA. Effect of topical phenytoin cream on linear incisional wound healing in albino rats. DARU Journal of Pharmaceutical Sciences 2004;12:156.
33. Rezaei A, Delazar A, Mohajeri D, Taghizadeh JM, Mohammadnezhad S, Ashrafi A. Effects of Echinacea purpurea herbal extract versus zinc oxide in rat skin wound healing model, histometric and histopathologic study. Pharmaceutical Sciences 2008;1:43-52.
34. Ota T, Fujikawa-Yamamoto K, Zong Z, Yamazaki M, Odashima S, Kitagawa I. Plant-glycosidomodulation of cell surface related to control of differentiation in cultured B16 melanoma cells Cancer Res 1987;47:3863-7.
35. Mehrvarz S, Izadyar B, Nazari F. Effect of Fundermol ointment on wound healing in comparison with Normal Saline. Kowsar Medical Journal 1997;2:95-100.
36. Le eJ, Jung E, Lee J, Huh S, Kim J, Park M. Panax ginseng induces human Type I collagen synthesis through activation of Smad signaling J Ethnopharmacol 2007;109:29-34.

Tables and Charts:

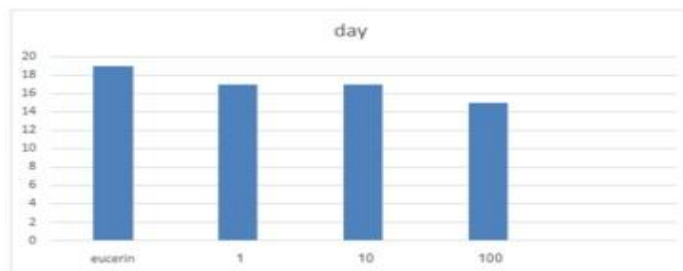
Figures 1: The effect of ointment containing Korean red ginseng root extract with a dose of 1,10,100 µg/ml on wound area, each point represents the Mean ± SEM .in 1 µg/ml extract group P <0.05* and P <0.01** as compared with the eucerin group and in 10 µg/ml extract P <0.05# as compared with the eucerin group, extract P <0.05¥, P <0.01¥¥ and P<0.001 ¥¥¥ compared with eucerin group.



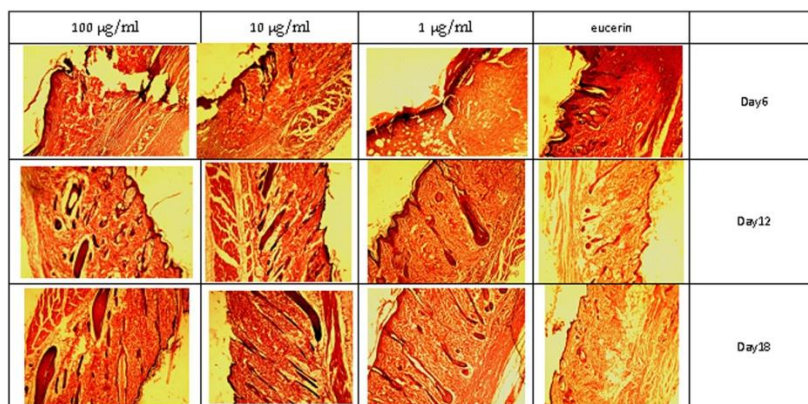
Figures 2: Wound area was shown in experimental and control groups (photos were taken by using a digital camera).



Figures 3: This figure shows the day the wound area reached <0.16 cm² in different doses of Korean red ginseng. 1,10,100 means 1, 10,100 µg/ml of Korean red ginseng extract.



Figures 4: Histological evaluation of wound healing in different groups on days 6, 12, 18 and 23: 1, 10, 100 means ointment containing 1, 10 and 100 $\mu\text{g/ml}$ Korean red ginseng extract. (H&E used for coloring).



Figures 5: The effect of an ointment containing Korean red ginseng root extract on tissue tension on days 6, 12, 18, each point represents the Mean \pm SEM. $P < 0.1^*$, $P < 0.01^{**}$ and $P < 0.001^{***}$ extract group as compared with the control group.

