

Original Article

Skeletal Maturity Prediction Using Radiographs of the Medial Phalanx of the Third Finger and Cervical Vertebrae

Yelda Kasimoglu^{1*}, Gulnaz Marsan², Koray Gencay³.

1. DDS, PhD, Istanbul University, Faculty of Dentistry, Department of Pedodontics, Istanbul, Turkey.
2. DDS, Prof, Istanbul University, Faculty of Dentistry, Department of Orthodontics, Istanbul, Turkey.
3. DDS, Prof, Istanbul University, Faculty of Dentistry, Department of Pedodontics, Istanbul, Turkey.

*correspondence: **Yelda Kasimoglu**, DDS, PhD, Istanbul University, Faculty of Dentistry, Department of Pedodontics, Istanbul, Turkey. Email: yelda.kasimoglu@istanbul.edu.tr

Abstract:

Introduction: Chronological age alone is not sufficient for assessing the developmental stage of a growing child; hence, many skeletal maturity indicators have been proposed. Periapical radiography is the preferred imaging technique in dental clinics and can be used as an alternative diagnostic tool for maturity prediction. The purpose of this study was to assess the correlation between modified periapical and cephalometric methods for predicting skeletal maturation in children.

Methods: Children who required a maturity analysis for orthodontic treatment planning were included in this study. Cephalometric radiographies were obtained from the clinics of orthodontics. The medial phalanges of the third finger (MP3) regions of 150 children (70 males, 80 females) between the ages of 8 and 18 years (mean = 13.47±3.08) were imaged in pediatric dentistry clinics. For cephalometric and periapical images, maturity was assessed using Baccetti et al.'s, and Rajagopal and Kansal's analyses, respectively. Spearman correlation coefficients were used to evaluate associations between skeletal stages with significance levels set at $p < 0.01$ and < 0.05 .

Findings: There was a significant correlation between cervical vertebrae and MP3 analyses for all groups ($p < 0.001$) with the exception of 10-year-old children ($r = 0.523$, $p > 0.05$).

Conclusion: The MP3 method is a useful tool for the assessment of maturity in children as there is no need for special equipment and because of its relatively easy system for determining stages.

Keywords: cervical radiography, growth and development, skeletal maturity, pediatric dentistry, puberty, x-ray.

Introduction:

Monitoring growth and development in children is important for determining treatment regimes, the right time to start treatments, and treatment prognoses. Childrens' levels of mental maturity, physical growth, health, and number of erupted teeth are estimated based on chronological age. However, physiological

differences exist between individuals of the same race, gender, and age. Therefore, chronological age does not match developmental stage for every individual.(1,2).

Hand-wrist radiography is routinely used to evaluate skeletal development. Researchers have described different skeletal maturation indicators on hand-wrist sites, which cover

the entire period of adolescent growth(3). However, one of the main disadvantages of hand-wrist radiography is the need for additional x-rays in addition to routine radiographic examinations (e.g. lateral cephalograms and orthopantomograms). Hence, to avoid additional radiation doses, the cervical vertebra, which are imaged in routine lateral cephalograms, are also used to determine skeletal maturity for orthodontic patients. Baccetti et al. proposed a new method for predicting skeletal maturation by using lateral cephalograms to describe 6 different stages(4). Predicting pubertal growth spurts in children using hand-wrist x-rays is therefore no longer included in guidelines for orthodontic treatment planning (5,6).

A 5-step method method for assessing pubertal growth spurts was proposed by Hagg and Taranger,¹ and utilized in periapical radiography for the first time by Abdel-Kader et al. The first stage, MP3-F, corresponds to the stage in which “the epiphysis is as wide as the metaphysis”. The second stage, MP3-FG, corresponds to the stage in which “the epiphysis is as wide as the metaphysis, and there is a distinct medial and/or lateral border of the epiphysis forming a line of demarcation at right angle to the distal border”. The third stage, MP3-G, “the sides of epiphysis have thickened and also cap its metaphysis forming a sharp edge distally at one or both sides”. MP3-H, corresponds to the stage which “fusion of epiphysis and metaphysis has begun”. The fifth stage, MP3-I, corresponds to the stage in which “fusion of epiphysis and metaphysis is completed”(7). Rajagopal and Kansal further developed this method to

include 6 stages (8). The most significant advantage of this improved method is that it requires only one x-ray to evaluate growth and development instead of a complete hand-wrist x-ray (9).

In previous studies, the modified MP3 method of Rajagopal and Kansal was compared with different cervical vertebrae methods such as CVMI (10,11). and CVM (12,13) and a high correlation was found between them. However, there is no study comparing the cervical vertebra method, improved by Bacetti et al. in 2005⁴ and the modified MP3 method of Rajagopal and Kansal (8).

The aim of this study was to investigate the correlation between Baccetti et al.’s improved version of CVM method⁴ and Rajagopal and Kansal’s modified MP3 method⁸ for predicting skeletal maturity and to assess the application of an MP3 method, which only requires a dental x-ray unit and is therefore widely accessible by dentists.

Methods:

One-hundred-and-fifty healthy children (80 females, 70 males) between 8-18 years of age who were undergoing orthodontic treatment within the Department of Orthodontics, Istanbul University, Faculty of Dentistry, Istanbul, Turkey were randomly selected for participation in this study.

All participants met the following criteria: (1) Turkish children; (2) free of any systemic disorders or congenital/acquired abnormalities of the hand/cervical vertebrae; (3) no previous injury of the head and neck region; and (4) required a maturity

assessment as a part of his/her orthodontic treatment. Ethics clearance was obtained from the institutional ethics committee of Istanbul University Faculty of Dentistry (Ref. 2014/791).

After providing written informed consent, all participants underwent digital cephalometric radiography (Sirona Orthophos XG Plus; Sirona Dental Systems, GmbH, Bensheim, Germany) and a digital radiograph of the medial phalanx of the third finger (MP3) using an intraoral x-ray unit (Kodak 2100; Kodak, Atlanta, GA, USA) with a CCD sensor (Kodak RVG 5100; Kodak, Rochester, NY, USA). All radiographs were obtained on the same day. Standard radiation safety protocols were followed prior to and during radiographic imaging. The genders and ages of the study population was distributed as in Table 1.

For imaging the MP3, the participant sat comfortably on a chair with their left hand on a table top and was instructed to place spread their fingers. A sensor was placed along the MP3 region's long axis. The central x-ray beam was positioned perpendicular to the area of interest and in light contact with the middle finger (Fig. 1). Only good quality radiographs were included for further staging and scoring.

Skeletal maturation was evaluated using 2 methods. Radiographs of the cervical vertebrae and MP3 were assessed for skeletal maturation according to the parameters set by Baccetti et al.'s (cervical vertebrae; CS) method, (4) and the method described by Rajagopal and Kansal (modified MP3 method; Fig. 2),(8) respectively. Both CS and MP3 methods

identify 6 stages of skeletal maturation (Table 2). To compare the 2 methods, we correlated stages 1-6 of the CS method with their numeric counterpart in the MP3 method similar to Pasciuti et al.'s study (14).

10 random samples of cephalometric and MP3 x-rays were scored twice by one examiner at 2-week intervals, to check the reliability of the values obtained. Each radiograph was numbered to blind the examiner to the participant's identity. Reliability was calculated with using the Spearman-Brown formula (98.2 and 99.3% for CS and MP3 methods, respectively).

Data was analyzed using the Number Cruncher Statistical System statistics software package 2007 version (NCSS, Kaysville, UT, USA). Spearman correlation coefficients were used to identify associations between skeletal stages determined using the 2 methods. Significance levels were set at $p < 0.01$ and < 0.05 .

Findings:

The sample population of 80 girls and 70 boys (total: 150, aged between 8 and 18 years old, mean age: 13.47 ± 3.08 years) (Table 1) was divided into different skeletal maturation groups based on CS and MP3 stages and correlated with each other (Table 3).

For both males and females, there was a significant overall positive correlation between skeletal maturation scores obtained using each technique ($p < 0.01$) (Table 4). However, there were no significant associations between CS and MP3 scores for participants of 10-11 years ($r = 0.523$,

$p > 0.05$) (Table 3). Girls were more skeletally advanced than boys.

Discussion and Conclusion:

In dentistry, prediction of pubertal growth spurts is mostly required for treatments related to skeletal disorders (15). Treatment planning for growing children requires assessment of maturation status of the children to determine optimal intervention times, treatment approaches, and prognoses (16).

Several methods of evaluating bone maturation have been introduced. Radiographic assessment consists of staging based on changes in the size and shape of bones (17). Assessment of maturation using hand-wrist radiographs is still an extremely popular method for growth prediction, but requires both time and specialist expertise and involves additional radiation exposure (18). The British Orthodontic Society Radiography Guidelines do not support the take hand-wrist x-rays as they unnecessarily expose patients to additional radiation for orthodontic treatment planning (5).

Alternatively, cervical vertebrae methods aim to reduce radiation exposure in growing patients by utilizing routine lateral cephalograms for skeletal maturity assessments (19–22). Previous studies evaluating these methods often included participants across a wide age range (21). However, classifying the shape of the third and fourth vertebra using routine radiographs is often difficult (23).

A simplified method for skeletal maturity assessment using hand-wrist radiography and intra-oral x-ray film has been proposed

(8,24). We compared this approach to the cervical vertebrae method described by Baccetti et al (4). and found a positive correlation between scores obtained using these methods, which was consistent with previous findings (14). Studies comparing this MP3 method with other cervical vertebrae methods have also reported strong positive correlations (10,24). Furthermore, a good correlation between Baccetti et al.'s cervical vertebrae method and a different hand-wrist method has been reported previously (25). However, there was no statistically significant association between scores for participants within the 10-11 year age group in this study ($r = 0.523$, $p > 0.05$).

Our results clearly show that girls scored higher than in boys using both methods. This is in agreement with the findings of previous studies (26–28).

Baccetti et al.'s cervical vertebrae⁴ and Rajagopal and Kansal's MP3 stages (8,10,24). of development have been reported as both reliable and valid methods for the assessment of skeletal maturity. However, the low correlations between MP3 and CS scores for 10-year-old children demonstrated that measuring skeletal maturity using only MP3 method. The MP3 method is a useful tool for the assessment of maturity in children as there is no need for special equipment and because of its relatively easy system for determining stages, we therefore recommended the use of MP3 analysis for evaluating growth peaks when orthodontic treatment planning is being considered.

Acknowledgement:

The present work was supported by the Research Fund of Istanbul University (Project No. 44287).

References:

1. Hägg U, Taranger J. Skeletal stages of the hand and wrist as indicators of the pubertal growth spurt. *Acta Odontol. Scand* 1980; 38:187–200.
2. Saini P. Master dentistry. Volume 2: restorative dentistry, paediatric dentistry and orthodontics. Nature Publishing Group; 2013.
3. Joshi VV, Iyengar AR, Nagesh KS, Gupta J. Comparative study between cervical vertebrae and hand-wrist maturation for the assessment of skeletal age. *Arch. Oral Res* 2010; 6: 207-13.
4. Abdelkarim A. Orthodontic radiographs: Guidelines for the use of radiographs in clinical orthodontics. *Am. J. Orthod. Dentofac. Orthop* 2016; 149: 141–142.
5. Patcas R, Signorelli L, Peltomäki T, Schätzle M. Is the use of the cervical vertebrae maturation method justified to determine skeletal age? A comparison of radiation dose of two strategies for skeletal age estimation. *Eur. J. Ortho* 2012; 35: 604–609.
6. Baccetti T, Franchi L, McNamara Jr JA. The cervical vertebral maturation (CVM) method for the assessment of optimal treatment timing in dentofacial orthopedics. *Seminars in Orthodontics* 2005; 11: 119–129.
7. Abdel-Kader HM. The reliability of dental x-ray film in assessment of MP3 stages of the pubertal growth spurt. *Am. J. Orthod. Dentofac. Ortho* 1998; 114: 427–429.
8. Rajagopal R, Kansal S. A comparison of modified MP3 stages and the cervical vertebrae as growth indicators. *J. Clin. Orthod JCO* 2002; 36: 398-406.
9. Asha ML, Chatterjee I, Patil P, Naveen S. Dosimetry in dentistry. *Indian J Dent Res* 2015; 26: 118-125.
10. Pasciuti E, Franchi L, Baccetti T, Milani S, Farronato G. Comparison of three methods to assess individual skeletal maturity. *J. Orofac. Orthop. der Kieferorthopädie* 2013; 74: 397–408.
11. Soegiharto BM, Cunningham SJ, Moles DR. Skeletal maturation in Indonesian and white children assessed with hand-wrist and cervical vertebrae methods. *Am. J. Orthod. Dentofac. Ortho* 2008; 134: 217–226.
12. Cunha AC, Cevidanes LH, Sant’Anna EF, Guedes FR, Luiz RR, McNamara JA, et al. Staging hand-wrist and cervical vertebrae images: a comparison of reproducibility. *Dentomaxillofacial Radiol* 2018; 47: 20170301.
13. Fishman LS. Maturation patterns and prediction during adolescence. *Angle Orthod* 1987; 57: 178–193.
14. Silveira AM, Fishman LS, Subtelny JD, Kassebaum DK. Facial growth during adolescence in early, average and late maturers. *Angle Orthod* 1992; 62: 185–190.
15. Lamparski DG, Nanda SK. Skeletal age assessment utilizing cervical vertebrae. *Craniofacial growth Ser* 2002; 39: 171–184.
16. Hassel B, Farman AG. Skeletal maturation evaluation using cervical vertebrae. *Am. J. Orthod. Dentofac. Orthop* 1995; 107: 58–66.
17. Garcia-Fernandez P, Torre H, Flores L, Rea J. The cervical vertebrae as

maturational indicators. *J Clin Orthod* 1998; 32: 221–226.

18. Franchi L, Baccetti T, McNamara Jr JA. Mandibular growth as related to cervical vertebral maturation and body height. *Am J Orthod Dentofac Orthop* 2000; 118: 335–340.

19. Abdulla Alkhal H, Wong RWK, Bakr Rabie AM. Correlation between Chronological Age, Cervical Vertebral Maturation and Fishman's Skeletal Maturity Indicators in Southern Chinese. *Angle Orthod* 2008; 78: 591–6.

20. Özer T, Kama JD, Özer SY. A practical method for determining pubertal growth spurt. *Am. J. Orthod. Dentofac. Orthop* 2006; 130: 131-e1.

21. Fishman LS. Radiographic evaluation of skeletal maturation: a

clinically oriented method based on hand-wrist film. *Angle Orthod* 1982; 52: 88–112.

22. Koshy S, Tandon S. Dental age assessment: the applicability of Demirjian's method in south Indian children. *Forensic Sci Int* 1998; 94: 73–85.

23. Hägg U, Taranger J. Maturation indicators and the pubertal growth spurt. *Am J Orthod* 1982; 82: 299–309.

24. Durka-Zajac M, Marcinkowska A, Mituś-Kenig M. Bone age assessment using cephalometric photographs. *Polish J Radiol* 2013; 78: 19-25.

25. Gupta G, Mogra S, Shetty VS, Shetty S, Goyal S, Garg S. Hand Wrist Radiographs-Are They Really Required As Maturation Indicators?????. *Indian J Dent Sci* 2013; 5: 30-33.

Tables and Charts:

Table 1: The genders and ages of the study population.

Age (year)	Boys	Girls	Total
8-9	6	5	11
9-10	4	14	18
10-11	6	7	13
11-12	5	7	12
12-13	6	5	11
13-14	3	6	9
14-15	10	7	17

15-16	8	11	19
16-17	6	10	16
17-18	16	8	24
Total	70	80	150

Table 2: Comparison between CS and MP3 maturation stages.

CS stages	MP3 stages	Pubertal growth
CS-1	MP3-F	Initiation
CS-2	MP3-FG	Acceleration
CS-3	MP3-G	Transition
CS-4	MP3-H	Deceleration
CS-5	MP3-HI	Maturation
CS-6	MP3-I	Completion

CS, cervical vertebral maturation stage; MP3, third middle phalanx maturation stage.

Table 3: Correlations between 2 methods for different age groups.

Age (year)	n	Correlation coefficient ^b	p
8-9	11	0.770	0.006**
9-10	18	0.558	0.016*
10-11	13	0.523	0.067
11-12	12	0.602	0.038*
12-13	11	0.948	<0.001**
13-14	9	0.932	<0.001**
14-15	17	0.908	<0.001**
15-16	19	0.725	<0.001**
16-17	16	0.856	<0.001**
17-18	24	0.722	<0.001**
Total	150	0.961	<0.001**

^bSpearman correlation coefficient

*p<0.05

**p<0.01

Table 4: Total correlation between 2 methods for each gender.

Gender	n	Correlation coefficient ^b	p
Boys	70	0,959	<0,001**
Girls	80	0,963	<0,001**

^bSpearman correlation coefficient

*p<0.05

**p<0.01

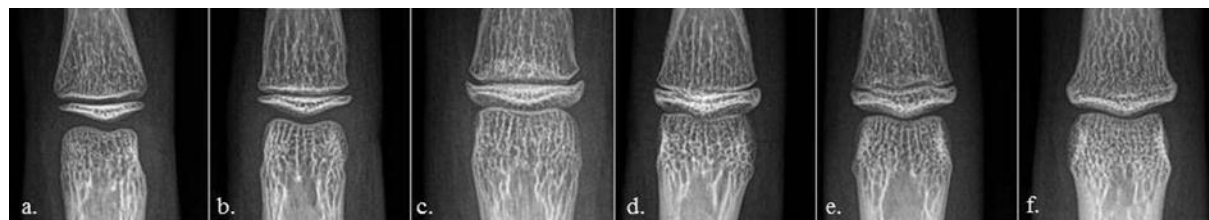
Figure 1: Positioning of the x-ray tube to obtain images of MP3 region.**Figure 2:** Six morphological stages of the MP3 during puberty according to Rajagopal and Kansal (8).

Figure 2. a. MP3-F stage: the epiphysis is as wide as the metaphysis. b. MP3-FG stage: the epiphysis is as wide as the metaphysis; a distinct medial and lateral border of the epiphysis forms a line of demarcation at a right angle to the distal border; the metaphysis begins to show a slight undulation. c. MP3-G stage: the sides of the epiphysis have thickened and cap its metaphysis, forming a sharp distal edge on at least 1 side. d. MP3-H stage: fusion of the epiphysis and the metaphysis begins; at least 1 side of the epiphysis forms an obtuse angle to the distal border. e. MP3-HI stage: the metaphysis shows a smooth, convex surface, almost fitting into the reciprocal concavity of the epiphysis. f. MP3-I stage: fusion of the epiphysis and the metaphysis is complete.