

Research Article

Comparison Of The Effect Of Clemestine And Placebo after Intravenous Corticosteroids In The Treatment Of Acute Optic Neuritis

Majdinasab Nastaran¹, Ghasemi Susan^{1*}, Kouchak Maryam²

1. Neurology department, Ahvaz Jundishapur University of Medical Sciences, Ahvaz, Iran.

2. Department of Pharmaceutics, School of Pharmacy, Ahvaz Jundishapur University of Medical Sciences, Ahvaz, Iran.

***Corresponding author: Ghasemi Susan.** Neurology department, Ahvaz Jundishapur University of Medical Sciences, Ahvaz, Iran. Email: sgh.ghasemi@gmail.com, <https://orcid.org/0000-0003-3256-2932>.

Abstract:

Introduction: Acute optic neuritis is a demyelinating disease of optic nerve and the most common optic neuropathy that affects young adults. Clemastine is a common antihistamine and it plays a main role in restoring the myelin membrane and increase the differentiation of oligodendrocytes.

Methods: In current clinical trial, 30 patients aged 15-50 years with acute optic neuritis were randomly divided into two groups of case and control. The case group was treated with Clemastine for three months and the control group was given a placebo for three months. Visual acuity, color vision, and p100 latency were examined and compared in both groups before and 3 months after the treatment.

Results: The mean color vision after treatment in the case (19.86 ± 0.51) and placebo (19.46 ± 1.12) groups showed no statistically significant differences ($p > 0.05$). Also, the mean visual acuity in the case (0.98 ± 0.056) and placebo (0.94 ± 0.091) groups after receiving medicine showed no statistically significant differences ($p > 0.05$). The mean of the p100 latency of evoked potential in the case (115.80 ± 13.25) and placebo groups (124.12 ± 7.88) after receiving treatments showed a meaningful difference statistically ($p < 0.05$).

Conclusion: The use of Clemastine for reduction of the chronic complications of the optic neuritis could be considered in the outline.

Keywords: acute optic neuritis, Clemastine, p100 latency

Submitted: 24 January 2022, Revised: 12 March 2022, Accepted: 19 March 2022

Background:

Acute optic neuritis is a demyelinating disease of optic nerve and the most common optic neuropathy that affects young adults. Acute optic neuritis is usually affected female between 20 to 45 years age and it is twice as common in females as in male (1, 2). Acute optic neuritis clinical symptoms include loss of vision, reduced color vision, decreased contrast sensitivity, and loss of visual field. The pain accompanied by eye movements before decreasing visual acuity is observed in 90% of

cases and loss of vision progresses in a few hours to a few days (3). In some patients, both optic nerves involve simultaneously or within a few days to several weeks. The most common impairment is in the Centrocecal area of the visual field. In the physical examination, the most observed signs include reduction in the contrast sensitivity and relative defect in the pupil responses (4, 5).

The patients with acute optic neuritis 50% developed multiple sclerosis within 5 to 15

years. Acute optic neuritis is the first presentation of about 25% of patients with multiple sclerosis. It is important to differentiate the cause of acute optic neuritis because of their different treatment and recurrence (4, 6-9).

Acute optic neuritis treatment based on a large randomized clinical trial is a venous corticosteroid. Spontaneous recovery occurs after a few weeks to several months (10). The normal vision returns in 65% of patients; however, dyschromatopsia and scotoma might persist and rarely, the patient remains blind (8, 10) Optic nerve damage occurs in some patients, which sometimes happens even after an episode. Patients occasionally report a decrease in the amount of light perception, contrast sensitivity and depth perception. Sometimes, the permanent vision lost to 20/30 or severe vision problems occur equal to 20/200 or even worse. The permanent scotoma that disrupts driving also is a complication of optic neuritis (11, 12).

Recently, many drugs are known as myelin-repairer remedies. Clemastine is a common antihistamine used to treat colds and allergies, recent studies have shown that it plays a role in the myelin membrane repair and induces the oligodendrocytes differentiation, although its exact mechanism is still unknown (13, 14).

A study conducted by Green et al. (2017) (15) prescribed oral Clemastine or an inactive placebo twice a day to 50 patients with MS and visual nerve damage for 150 days. The obtained results showed that visual impairment was reduced; but this was not statistically significant.

In addition, fatigue increases with Clemastine consumption.

Liu et al. (2016) (14) investigated the mice with social isolation; the mice also had myelin structure change, defects in performance of oligodendrocytes with cognitive and motor disorders and defective social behaviors. Clemastine was prescribed orally for two weeks, the experiments showed the differentiation of oligodendrocytes and increased myelination; also, successfully changed the avoidance behavior of mice.

Clemastine improved the differentiation of oligodendrocytes and myelin restoration in mice. The schizophrenia signs and evidence of myelin degradation in the brain cortex and corpus callosum were created in mice which exposed to cuprizone regimen for 6 weeks; after that, the mice were treated with Clemastine for 2 weeks. The results showed myelin regeneration and the increase of mature oligodendrocytes in myelin degradation regions (16). Based on findings and evidence, Clemastine plays a main role in myelin restoration, as well as the destructed myelin that occurs in optic neuritis, causing long-term and sometimes permanent complications. The aim of this study was to investigate the effect of Clemastine on the treatment of symptoms and the improvement of optic neuritis complications.

Methods

This research was carried out under the terms of a project license issued by ethical approval in Ahvaz Jondishapur University of Medical sciences, Iran

(code of ethics in research: IR.AJUMS.REC.1396.635).

Participants

This study was a clinical trial (clinical trial code: IRCT20181124041745N1) that involved 30 patients at 15 to 50-year-old with optic neuritis; the enrolled patients were referred to Golestan Hospital in Ahvaz, Khuzestan province, Iran. The patients were randomly divided into two groups of case and control. The case group was treated with Clemastine (1 mg/twice per day) for three months and the placebo was given to control group for three months.

Measures/Instruments

The visual acuity, color vision, and p100 latency of both groups were compared before and after 3 months' treatment. Snellen chart was used to study visual acuity and Ishihara book used to check the color vision; it consists of 20 pages that on these pages there are numbers consisting of colored points in a field composed of points with other colors. The enrolled people must identify the number within each page. The visual evoked potential was tested at the beginning and after the completion of the research to evaluate the p100 latency.

Statistical Analysis

The SPSS 22 was used to analyze the data and test the statistical assumptions. Firstly, descriptive information including means and standard deviations were extracted for

quantitative data; the frequency and percentage data was used for qualitative data using descriptive trends. The Kolmogorov-Smirnov test was used to analyze the normality's of the variables. The t-test was used to compare the dependent variables (including color vision, visual acuity, and p100 latency) between of the groups. The non-parametric equivalent Mann-Whitney test was used for independent or non-normal distribution of the data. Also, paired t-test or its non-parametric equivalent was used to analyze the changes of the variables during study period.

Results

Out of the 30 optic neuritis patients, 19 (63.3%) were female and 11 (36.7%) were male (Fig 1-A). The enrolled patients were divided into two groups of case and Placebo. Out of the 15 patients in the case group, 10 were female (66.7%) and 5 were male (33.3%) and of the 15 patients in the placebo group, 9 (60%) were female and 6 (40%) were men. The mean age of patients with optic neuritis was 29.303 ± 6.53 years. The youngest patient had 18 years and the oldest was 47 years. The mean age in the case group was 30.06 ± 7.33 and the mean age in the placebo group was 28 ± 5.68 . The youngest patient in the case group was 19 years old and the oldest was 47 years old; also, the youngest patient in the placebo group was 18 and the oldest was 40 years old (Fig 1-B).

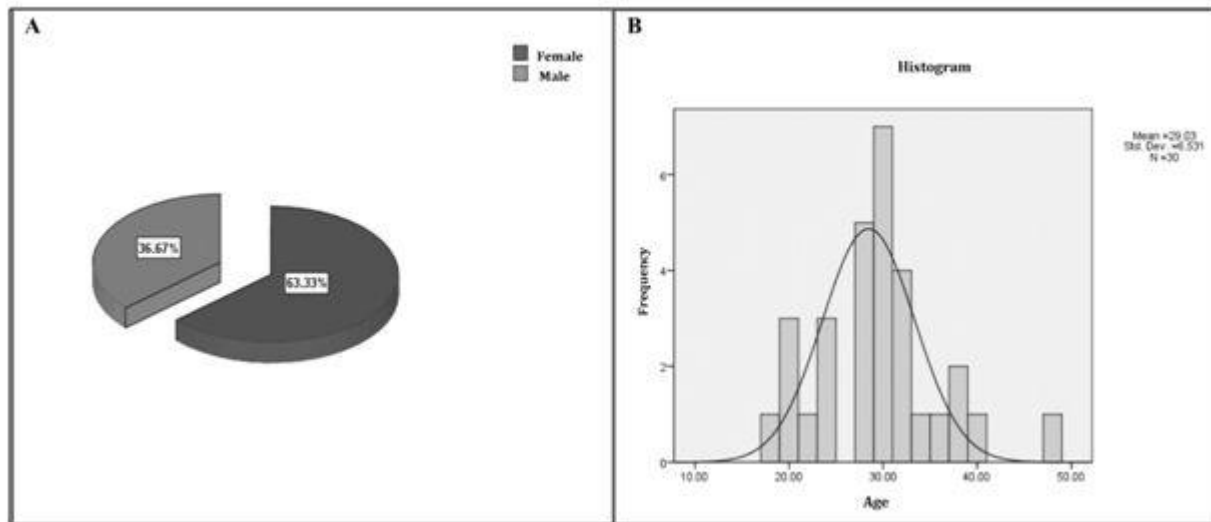


Figure 1. Pie chart in terms of frequency percentage of gender distribution of patients with optic neuritis (A). Histogram and normal age distribution curve of patients with optic neuritis (B).

The mean of color vision of all patients with optic neuritis before the treatment with Clemastine was 13.90 ± 6.64 . The lowest color vision was 0.00 and its maximum value was 20. The mean of color vision in the case group was 12.86 ± 7.56 before the treatment with Clemastine and the mean color vision in the placebo group was 14.93 ± 5.33 before taking the drug. The lowest amount of color vision in the case group before taking the Clemastine was 0.00 and its highest value was 20. The lowest amount of color vision in the placebo group before treatment was 4 and its highest value was 20 (Fig 2-A). The mean color vision of all patients with optic neuritis after treatment with Clemastine was 19.0 ± 66.88 . The lowest color vision was 17 and its maximum value was 20. The mean of color vision in the case group after treatment with Clemastine was 19.86 ± 0.51 and the mean of color vision in the placebo group after taking the drug was 19.46 ± 1.12 . The

lowest amount of color vision in the case group after taking the Clemastine was 18 and its highest amount was 20. The lowest amount of color vision in the placebo group after taking the drug was 17 and its highest amount was 20 (Fig 2-B). The mean visual acuity of all patients with optic neuritis before taking the Clemastine was $0/41 \pm 0/30$. The minimum amount of visual acuity was 0/10 and its maximum value was 0/90. The mean visual acuity in the case group before using Clemastine was 0.36 ± 0.28 and the mean visual acuity in the placebo group before the treatment was 0.46 ± 0.31 . The lowest visual acuity in the case group before treatment with Clemastine was 0.10 and its highest value was 0.90. The lowest visual acuity in the placebo group before the treatment was 0.10 and its highest value was 0.90 (Fig 3-A).

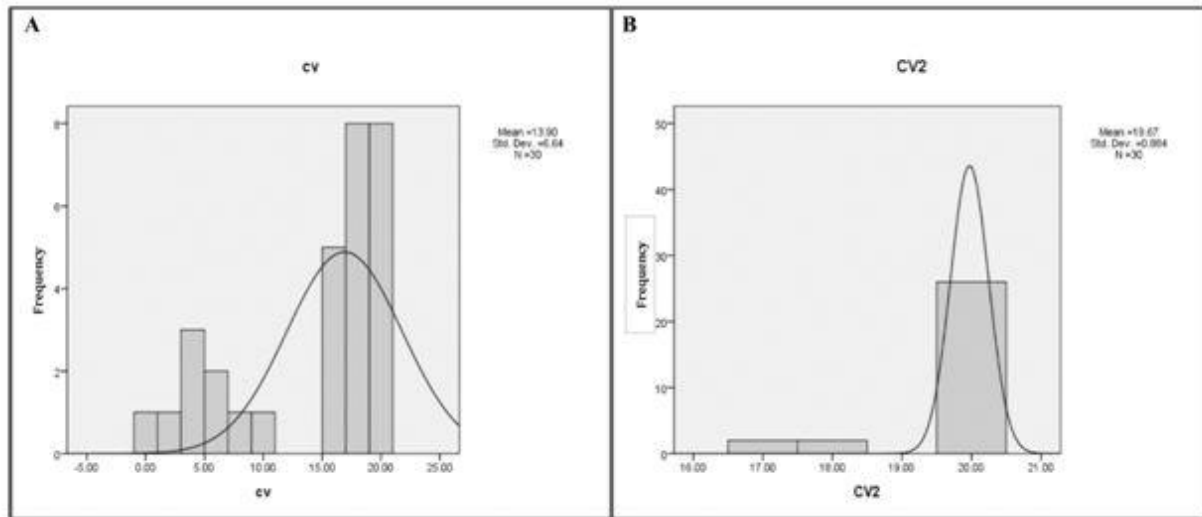


Figure 2. Histogram and normal curve of frequency distribution of color vision variables in patients with optic neuritis before (A) and after (B) of the study.

The visual acuity of all patients after treatment with Clemastine was 0.96 ± 0.076 . The minimum of that was 0.7 and its maximum value was 1. The mean visual acuity in the case group after treatment with Clemastine was 0.98 ± 0.056 and the mean visual acuity in the placebo group after the treatment was 0.94 ± 0.91 . The lowest visual acuity in the case group after receiving Clemastine was 0.80 and its highest value was 1. The lowest visual acuity in the placebo group

was 0.70 after treatment and its highest value was 1 (Fig 3-B).

The mean p100 latency of visual evoked potential of all the optic neuritis patients before treatment was 126.46 ± 12.99 .

The lowest amount of p100 latency of the visual evoked potential was 88 and its maximum value was 155.

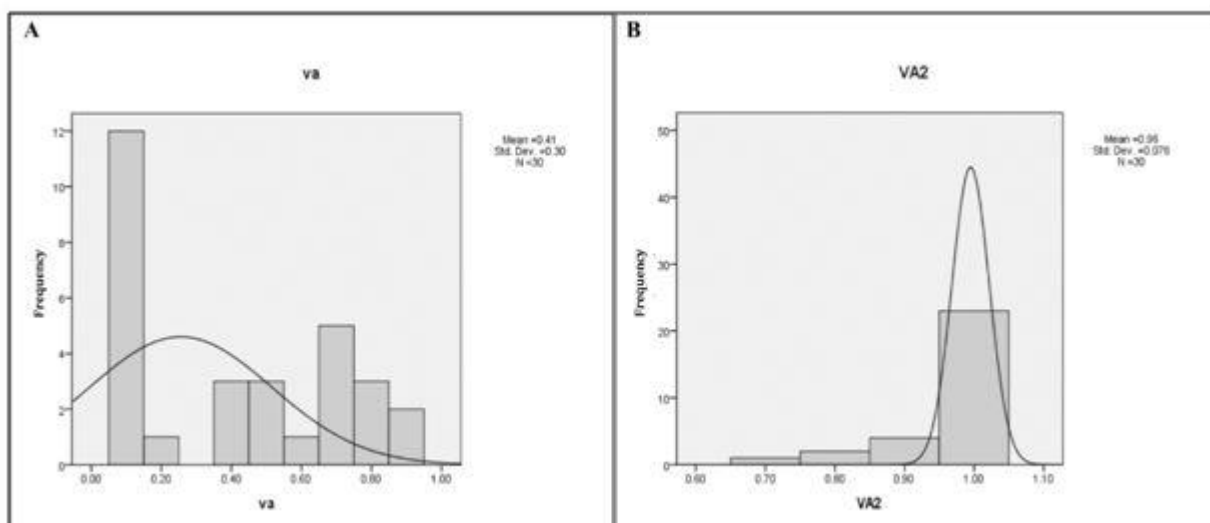


Figure 3. Histogram and normal curve of frequency distribution of visual acuity variables in patients with optic neuritis before (A) and after (B) of the study.

The mean of p100 latency of the visual evoked potential in the case group before the treatment with Clemastine was 125.66 ± 16.43 . The mean of p100 latency of visual evoked potential in the placebo group before using the drug was 127.26 ± 8.85 .

The lowest amount of p100 latency of the visual evoked potential in the case group before receiving Clemastine was 88 and its highest amount was 155. The lowest amount of p100 latency of visual evoked potential in the placebo group before receiving the drug was 114 and its highest amount was 141 (Fig 4-A).

The mean of p100 latency of visual evoked potential in all patients with optic neuritis after study period was 120.11 ± 10.57 . The lowest amount of p100 latency of visual evoked

potential was 80 and its maximum amount was 139. The mean of p100 latency of the visual evoked potential in the case group after the treatment with Clemastine was 115.80 ± 13.25 and mean of p100 latency of the visual evoked potential in the placebo group after receiving the drug was 124.40 ± 7.88 . The lowest amount of p100 latency of the visual evoked potential in the case group after using Clemastine was 80 and its maximum value was 138. The lowest amount of p100 latency of the visual evoked potential in the placebo group was 114 and its highest amount was 139 (Fig 4-B). Results of p100 latency of visual evoked potential of all the optic neuritis patients showed a significant difference in before and after receiving Clemastine and Placebo, respectively (Fig 5).

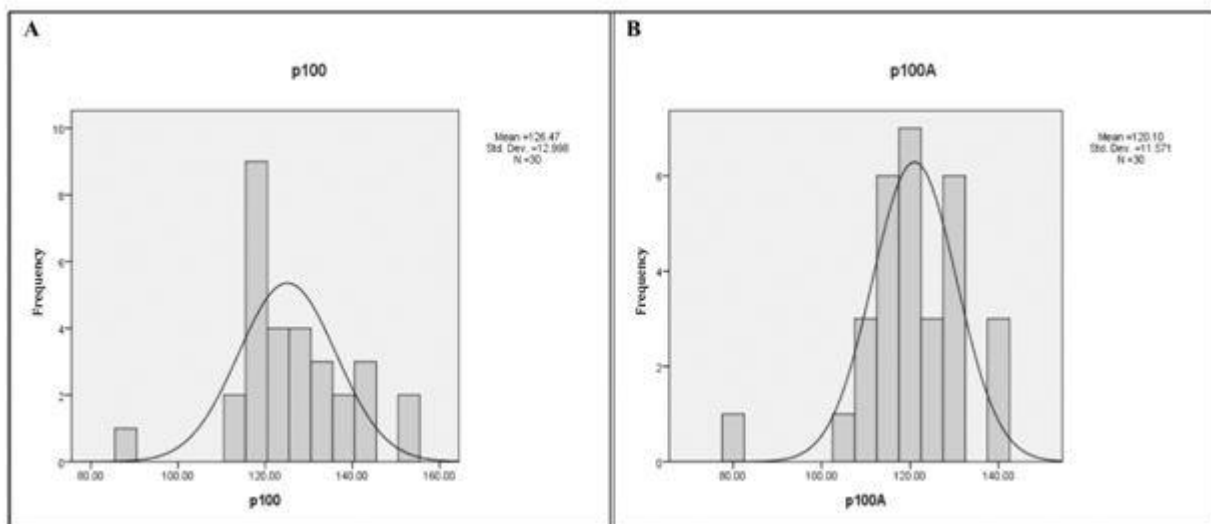


Figure 4. Histogram and normal curve of frequency distribution of p100 latency of visual evoked potential of all the optic neuritis patients before (A) and after (B) of the study.

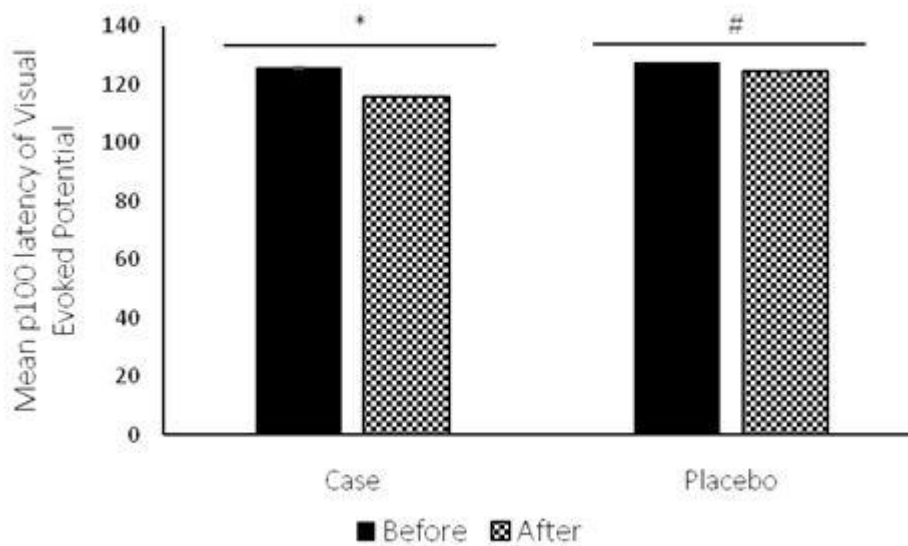


Figure 5. The mean p100 latency in patients with optic neuritis before receiving treatment in case and placebo groups. The case (*) and control (#) groups have significant difference after receiving Clemastine and Placebo, respectively ($p < 0.05$).

The results of the non-parametric Mann-Whitney test for comparing visual acuity before receiving treatment in both case and placebo groups did not show a significant difference ($p = 0.366$) ($p < 0.05$). Also, the same results was obtained after receiving Clemastine in both case and placebo groups ($p = 0.207$) ($p < 0.05$). (Table 1). The results of the non-parametric Mann-Whitney test for comparison of the color vision

before receiving treatment in the case and placebo groups did not show a significant difference ($p = 0.451$) ($p < 0.05$). Also, comparison of the visual acuity after receiving treatment in both case and placebo groups did not show a significant difference ($p = 0.261$) ($p < 0.05$) (Table 2).

Table 1. Non-parametric Mann-Whitney test for comparing visual acuity in patients with optic neuritis before and after receiving treatment in both case and placebo groups.

Visual Acuity	Before Receiving Clemastine	After Receiving Clemastine
Mann-Whitney test	91.50	90
Wilcoxon statistic	211.50	210
Z	-0.904	-1.262
p-value	0.366	0.207

Table 2. Non-parametric Mann-Whitney test to compare color vision in patients with optic neuritis before and after receiving treatment in both case and placebo groups.

Color Vision	Before Receiving Clemastine	After Receiving Clemastine
Mann-Whitney Test	94.50	96.50
Wilcoxon Statistic	214.50	216.50
Z	-0.754	-1.124
p-value	0.451	0.261

Discussion

Acute optic neuritis is the most common optic neuropathy that affects young adults. As previously reported by other researchers, (1, 2) our results indicate the same prevalence of the disease among the young adults. Atypical types of this neuropathy are more likely occurs over the 45 years age. The bilateral optic neuritis is not uncommon in childhood; there is a belief that the risk of subsequent multiple sclerosis is lower in these cases. The disease prevalence is approximately 2.8 per 100,000 people. In agreement with current research, other researchers reported that the disease occurs in female two times higher than in male.

The most common cause of acute optic neuritis is idiopathic, but it's most commonly known cause is multiple sclerosis. The current study unlikely to Green et al (2017) (15) involved all patients regardless of the disease causes. We assessed two main signs including color vision and visual acuity.

Clemastine as selective H1 receptor antagonists, inhibit histamine linkage and therefore restrain its constriction and dilatation effects. Depending on the administrated dose, H1 receptor antagonists can stimulate or inhibit the CNS activity; the most antihistamines inhibit the central or peripheral anticholinergic activities. Antihistamines block the H1 receptor sites, competitively. Antihistamines metabolized in the liver via mono and di-methylation (17 18). Clemastine especially at high doses affects non target organs; this event increases the side effects

risk (19). The Clemastine effects on central nervous system include CNS depression or over activation. In a phase II clinical trial, oral Clemastine significantly increased the transmission of electrical signals of the optic nerve in MS patients that had neurological damages (15). This improved status shows that neural myelin is recovered during the neurological pathway. The decreased levels of p100 latency in our study in agreement suggested improvement of the optic nerve signal transmission. The Clemastine effects on myelin repair have been proven in pre-clinical studies. In MS and optic neuritis the myelin sheath damage and nerve fiber occurred due to immune system responses. Current treatments are mainly focused on reduction in immune system responses. However, an especial treatment for the damaged myelin and nerves is necessary (20).

Clemastine reduces the p100 latency of visual evoked potential; but, determination of the other effect of oral Clemastine, especially in reducing the complications of acute optic neuritis, restoring the myelin membrane and increasing the differentiation of oligodendrocytes, requires more research (13). According to the benefits and limits, more research can be taken into consideration to increase the drug efficacy in patients with optic neuritis. The p100 latency showed a significant decrease in the group receiving Clemastine; it could suggest the role of this drug in the repair of myelin membrane and improvement of the transmission of neural signals (15). An accurate study on Clemastine's

clinical effects, require measurement of stereopsis, contrast sensitivity and the nerve fiber layer by optic coherence tomography (OCT).

Conclusions

In the next research steps, data collection from diagnostic and therapeutic centers could be conducted with larger sample size, as well as a longer period of time. In conclusion, the use of Clemastine for reduction of the chronic optic neuritis could be in the outline.

Acknowledgements

The authors thanks to Jondishapur University of Medical Sciences that supported this research.

Ethical Considerations

Compliance with ethical guidelines

Written informed consent was obtained from all participants, and the research protocol was approved by the Medical Ethics Committee of Jondishapur University of Medical Sciences, Ahvaz, Iran.

Funding

This study was financially supported by the Jondishapur University of Medical Sciences, Ahvaz, Iran.

Authors' contributions

All authors contributed to preparing this article.

Conflict of interest

The authors declared no conflict of interest.

References

1. Beck, R.W., Cleary, P.A., Anderson, M.M., Keltner, et al. A randomized, controlled trial of corticosteroids in the treatment of acute optic neuritis. *New England Journal of Medicine*. 1992; 326(9): 581-588. DOI: 10.1056/NEJM199202273260901.
2. Torres, R., Sanchez-Dalmau, B.F. Treatment of acute optic neuritis and vision complaints in Multiple Sclerosis. *Current treatment options in neurology*. 2015; 17(1): 1-11. DOI: 10.1007/s11940-014-0328z .
3. Wilhelm, H., Schabet, M. The diagnosis and treatment of optic neuritis. *Deutsches Ärzteblatt International*. 2015; 112(37): p.616. DOI: 10.3238/arztebl.2015.0616.
4. Monteiro, M.L., Borges, W.I., Ramos, C.D., et al. Bilateral optic neuritis in Wegener granulomatosis. *Journal of Neuro-ophthalmology*. 2005; 25(1): 25-28. DOI: 10.1097/00041327-200503000-00007.
5. Steed, D.L., Brown, L.R., inventors; Stemnion, L.L.C., assignee. Methods for preventing or treating optic neuritis. US patent application US 14/183,780. 2014 Aug 28.
6. Wakakura, M., Minei-Higa, R., Oono, S., et al. Baseline features of idiopathic optic neuritis as determined by a multicenter treatment trial in Japan. *Japanese journal of ophthalmology*. 1999; 43(2): 127-32. DOI: 10.1016/s0021-5155(98)00072-0.
7. Lee, S.B., Lee, E.K., Kim, J.Y. Bilateral optic neuritis in leprosy. *Canadian Journal of Ophthalmology*. 2009; 44(2): 219-220. DOI: 10.3129/i09-013.
8. Hoorbakht, H., Bagherkashi, F. Optic neuritis, its differential diagnosis and management. *The open ophthalmology journal*. 2012; 6: 65-72. DOI: 10.2174/1874364101206010065.
9. Malik, A., Ahmed, M., Golnik, K. Treatment options for atypical optic neuritis. *Indian journal of ophthalmology*. 2014; 62(10): 982-984. Doi: 10.4103/0301-4738.145986
10. Optic Neuritis Study Group. Multiple sclerosis risk after optic neuritis: final optic neuritis treatment trial follow-up. *Archives of neurology*. 2008; 65(6): 727-732. doi: 10.1001/archneur.65.6.727.
11. Sellebjerg, F., Nielsen, H.S., Frederiksen, J., et al. A randomized, controlled trial of oral high-dose methylprednisolone in acute optic neuritis. *Neurology*. 1999; 52(7): 1479 -1494. DOI: 10.1212/wnl.52.7.1479.

12. Gal, R.L., Vedula, S.S., Beck, R. Corticosteroids for treating optic neuritis. *Cochrane Database of Systematic Reviews*. 2015(8): CD001430. Doi: 10.1002/14651858.CD001430.pub3.
13. Mei, F., Fancy, S.P., Shen, Y.A., et al. Micropillar arrays as a high-throughput screening platform for therapeutics in multiple sclerosis. *Nature medicine*. 2014; 20(8): 954-960. DOI: 10.1038/nm.3618.
14. Liu, J., Dupree, J.L., Gacias, M., et al. Clemastine enhances myelination in the prefrontal cortex and rescues behavioral changes in socially isolated mice. *Journal of Neuroscience*. 2016; 36(3): 957-962. DOI: 10.1523/JNEUROSCI.3608-15.
15. Green, A.J., Gelfand, J.M., Cree, B.A., et al. Clemastine fumarate as a remyelinating therapy for multiple sclerosis (ReBUILD): a randomised, controlled, double-blind, crossover trial. *Lancet*, 2017; 390(10111): 2481-2489. DOI: 10.1016/S0140-6736(17)32346-2.
16. Li, Z., Yangtao, H., Shuangyi, F., et al. Clemastine rescues behavioral changes and enhances remyelination in the cuprizone mouse model of demyelination. *Neuroscience bull*. 2015; 31(5): 617-625. Doi: 10.1007/s12264-015-1555-3.
17. Woron, J., Porębski, G., Obtulowicz, K., et al. Drug safety in pharmacotherapy of allergic diseases. *Alergol. Immunol*. 2007; 4 (1-2): 22-24.
18. Minigh, J. Clemastine. *xPharm. The Comprehensive Pharmacology Reference*, 2008; 1-6. ISBN: 978-0-08-055232-3
19. Han, S., Karłowicz-Bodalska, K., Mićkiewicz, K. Safety of oral clemastine—analysis of data from spontaneous reporting system in poland. *Tropical Journal of Pharmaceutical Research*. 2014; 13(12); 2115-2118. DOI: 10.4314/tjpr.v13i12.24.
20. Mei, F., Lehmann-Horn, K., Shen, Y.A., et al. Accelerated remyelination during inflammatory demyelination prevents axonal loss and improves functional recovery. *Elife*. 2016; (27)5: e18246. DOI: 10.7554/eLife.18246