

Case report

Coinfected viral glossitis in an immunocompetent teenager

Andreea Liana Rachisan¹, Emanuela Floca¹, Bogdan Aldes², Dan Gheban³, Aurel Bizo¹, Gabriel Samasca⁴, Peter Makovicky⁵, Adrian Hrusca⁶

¹ Department of Pediatrics II, University of Medicine & Pharmacy "Iuliu Hatieganu" Cluj-Napoca, Romania

² Department of Plastic Surgery, University of Medicine & Pharmacy "Iuliu Hatieganu" Cluj-Napoca, Romania

³ Department of Pathology, University of Medicine & Pharmacy "Iuliu Hatieganu" Cluj-Napoca, Romania

⁴ Department of Immunology, University of Medicine & Pharmacy "Iuliu Hatieganu" Cluj-Napoca, Romania

⁵ Department of Transgenic Models of Diseases, Institute of Molecular Genetics, Czech Centre for Phenogenomics, Vestec, Czech Republic

⁶ Department of Medical Biophysics, University of Medicine & Pharmacy "Iuliu Hatieganu" Cluj-Napoca, Romania

Corresponding author: Andreea Liana Rachisan.

Email: rachisan_andreea@yahoo.com

Abstract

Viral glossitis is an uncommon condition in an immunocompetent patient. We reported a patient with developed painful pseudo-membranes on the tongue. The diagnosis showed multiple viral infections. The patient promptly responded to antiviral therapy. Multiple viral infections should no longer be considered as a diagnosis only in immunosuppressed patients, but in healthy persons as well.

Keywords: glossitis, Epstein-Barr virus, Cytomegalovirus, Coxsackie virus, Herpes Simplex virus

Introduction

Glossitis is a clinical condition in which the tongue is swollen and may suffer color changes. There were many causes described in the literature. The most common are bacterial and/or viral infections, mechanical irritations/injury, exposure to irritants, allergic reactions and disorders such as pernicious anemia, vitamin B deficiency, oral lichen planus etc. Viral glossitis is an uncommon condition in an immunocompetent patient. All published data have been in immunocompromised patients regarding only one viral etiology [1]. We report the case of a patient with viral glossitis, whose clinical aspect and course apparently resembled with *Candida albicans* as an etiological agent. The diagnosis was confirmed by both serological data and biopsy specimen, showing a multiple viral infection. The objective of this work is to describe a multiple viral glossitis in an immunocompetent teenager. The

work calls attention to possible existence of viral infections with primary tongue infection, but without previous viral history. This can be interesting in the diagnosis of similar viral infection also in other patients with the same signs.

Case report

Clinical data

A case report of 15-year-old girl who for the past 10 days before hospitalization experienced ongoing pain and tumefaction of the tongue is here reported. The clinical appearance consisted of multiple, raised, white-colored pseudo-membranes; most were on the anterior third and lateral site of the middle third of the tongue (*Figure 1*). The patient had no signs of atopy and any other important medication was referred. There was no history of any disease, deficiency or tongue trauma.

Our patient did not report stress or gastrointestinal complaints.

Laboratory investigations

Due to the clinical aspect Flow Cytometry Analysis (Figure 2) and Immunogram Analysis (IgG=1492mg/dl, IgA=272mg/dl, IgM=178 mg/dl) were performed but the results were in normal values. An inflammatory syndrome (ESR=45mm/h, PCR=3.6mg/dl) was found. The monocytes level was high (10.3%). No other significant changes in blood picture were observed. The clinical appearance suggested a candidiasis glossitis, but *Candida albicans* was negative in tongue secretions. The next hypothesis was a viral infection. We performed viral serologic testing (ELISA, ELFA) to monitor the immune system's antibody response to viral antigen exposure. Antibodies to Epstein-Barr virus (VCA) IgM and Cytomegalovirus IgM were negative but antibodies to Epstein-Barr virus (EBNA) IgG and Cytomegalovirus IgG were positive. Antibodies to the Coxsackie virus for IgM and IgG were found at borderline levels. Antibodies to Herpes Simplex

virus type 1 and 2 for IgM were positive and for IgG were negative.

Histopathological findings

Tongue biopsy due the viral coexistence was performed. The sample was from the ventral side in the middle third of the tongue. The result showed a viral attack resembling *Herpes Simplex virus infection*. Histological sample was part of the tongue which was covered by thickened multilayered epithelium, containing cells with pinkish polygonal cytoplasm and one darkness ovoid nucleus. The most of epithelial cells contained ovoid and pale vacuoles with some little differences in their caliber. Some epithelial cells were wrinkled with little vesicular blisters and a little part of cells was necrotic with fragmented nucleus. The adjacent interstitial part was composed from thin reticular fibers and on the basis there were some muscular fibers of the cross striated skeletal muscles visible. Please also kindly look to the Figure 3 (a, b, c).

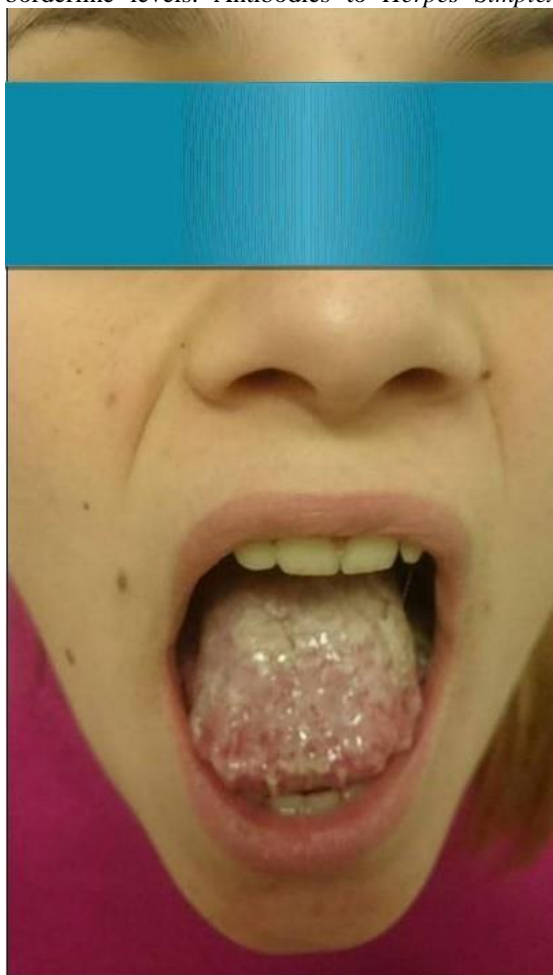


Figure 1. The clinical appearance

Result Name	%/Ratio	Abs Cnt (cells/ μ L)	Reference Range
T Lymphs % of Lymphs (CD3+/CD45+)	72.08		55% 84%
T Lymphs (CD3+) Abs Cnt		1759	690 2540
T Suppressor % of Lymphs (CD3+CD8+/CD45+)	26.97		13% 41%
T Suppressor Lymphs (CD3+CD8+) Abs Cnt		646	190 1140
T Helper % of Lymphs (CD3+CD4+/CD45+)	45.38		31% 60%
T Helper Lymphs (CD3+CD4+) Abs Cnt		1086	410 1590
CD3+CD4+CD8+ % of Lymphs (CD3+CD4+CD8+/CD45+)	0.42		
CD3+CD4+CD8+ Abs Cnt		10	
Lymphocyte (CD45+) Abs Cnt*		2440	
NK Lymphs % of Lymphs (CD16+56+/CD45+)	9.80		5% 27%
NK Lymphs (CD16+56+) Abs Cnt		244	90 590
B Lymphs % of Lymphs (CD19+/CD45+)	17.08		6% 25%
B Lymphs (CD19+) Abs Cnt		425	90 660
*For quality control purposes only			

Figure 2. Flow Cytometry Analysis

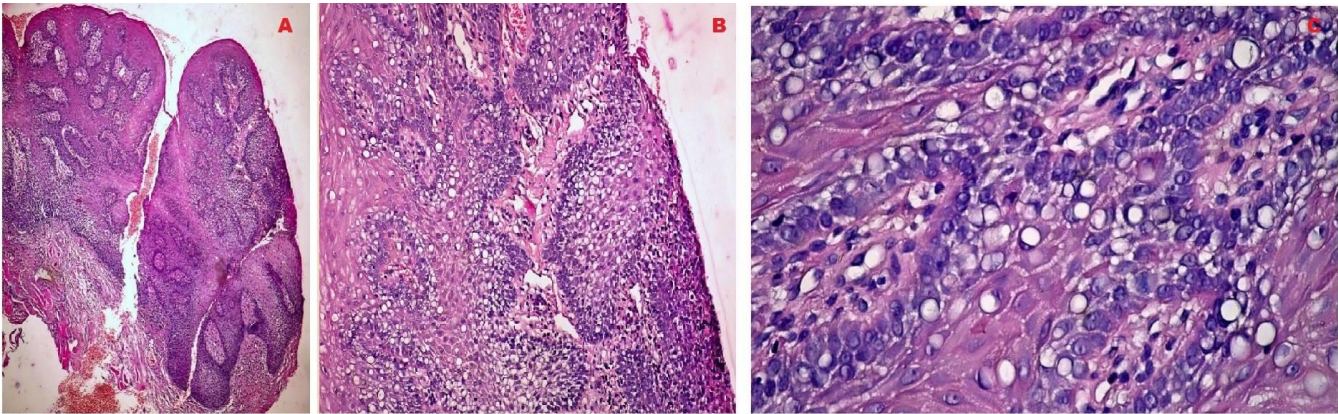


Figure 3. Histological examination

(A) The structure of a squamous mucosa, the corneous layer presents numerous koilocytes.

(B) The basal layer penetrates in the profound area and forms conjunctivo-vascular axes.

(C) There is an ulcerated area with abundant mixed inflammatory infiltrate composed of rotundonuclear and polymorphonuclear cells.

Discussion

Herpes simplex virus type 1 (HSV) gives rise to a variety of clinical disorders and is a major cause of morbidity and mortality worldwide. HSV infections are common in oral and perioral area. The typical characteristic of HSV lesions on the intraoral mucosa is a cluster of small (1mm in diameter), shallow, circular, red erosions [2]. Our case report showed that the lesions identified on the tongue are presented somewhat differently. Although the patient did not had a previous history of labial herpes, finally the herpes-glossitis was diagnosed. Differing from herpetic vesicles, discrete areas of ulceration are the typical presentation of herpetic glossitis. First HSV infection usually involves mucosae. Its typical clinical appearance can be differentiated from oral candidiasis and other oral ulcers. In our patient the clinical appearance resembled with *Candida albicans* infection but the serological and histopathological findings results are positive for herpetic glossitis. For an accurate diagnosis of intraoral local mucosal infection, the possibility of other mucosal diseases must be eliminated. The results of serology showed also the latent viral coinfections with Epstein-Barr virus (EBV) and Cytomegalovirus (CMV) and active viral infection with Coxsackie Virus (CXV) and Herpes Simplex Virus (HSV). It might that co-infection with EBV, CMV and CXV, HSV have a high tumorigenic potential.

Human papillomavirus (HPV) and HSV have been established in the recent years as causative agents of oral cancer. The prognostic significance of HPV in pre-cancerous oral lesion is not clear. A population-based study showed HSV to enhance the development of oral malignancy in HPV infected patients and individuals with a history of cigarette smoking. Epstein-Barr virus (EBV), human herpesvirus-8 and cytomegalovirus (CMV) have also been reported as risk factors of oral malignancies in different studies [3]. The EBV is a member of the herpes virus family and the influence of EBV in the pathogenesis of oral cancer remains elusive. The latent membrane protein-1 (LMP1), the principal protein of the virus, has been found in many EBV-positive patients with

malignancies, suggesting that this latent infection may play a role in the malignant transformation of the oral mucosa [4]. The oncogenic potential of EBV is related to expression of these latent genes, which are considered the viral oncogenes in EBV infection [5, 6]. Ectopic LMP1 or LMP2 expression has been shown to increase cellular invasion [7].

Systemic antiviral therapy has been widely accepted as effective for viral glossitis, by reducing the duration of symptoms of HSV infection. The optimal timing and dose of the treatment are uncertain [8]. Acyclovir may be of benefit in the acute treatment of severe HSV disease. There is also evidence that prophylactic oral Acyclovir may reduce the frequency and severity of recurrent attack of herpetic infection, but the optimal timing and duration of treatment is uncertain and can vary from patient to patient.

The objective of the present report was to critically describe a multiple viral glossitis in an immunocompetent teenager. As such, multiple viral infections should no longer be considered as a diagnosis only in immunosuppressed patients, but in healthy persons as well.

References

1. Reamy BV, Derby R, Bunt CW. Common Tongue Conditions in Primary Care. Am Fam Physician. 2010; 81: 627-34.
2. Cohen PR, Kazi S, Grossman ME. Herpetic geometric glossitis: a distinctive pattern of lingual herpes simplex virus infection. South Med J. 1995; 88:1231-5.
3. Nair U, Bartsch H, Nair J. Alert for an epidemic of oral cancer due to use of the betel quid substitutes gutkha and pan masala: A review of agents and causative mechanisms. Mutagenesis. 2004; 19: 251-62.
4. Vardendra Manvikar, Rama Kulkarni, Anila Koneru and M Vanishree. Role of human papillomavirus and tumor suppressor genes in oral cancer. J Oral Maxillofac Pathol. 2016 Jan-Apr; 20(1): 106-110.
5. Horikawa T, Yoshizaki T, Kondo S, Furukawa M, Kaizaki Y, Pagano JS. Epstein-Barr Virus latent membrane protein 1 induces Snail and epithelial-mesenchymal transition in metastatic nasopharyngeal carcinoma. Br J Cancer. 2011; 104:1160-7.
6. Dawson CW, Laverick L, Morris MA, Tramoutanis G, Young LS. Epstein-Barr virus-encoded LMP1 regulates epithelial cell motility and invasion via the ERK-MAPK pathway. J Virol. 2008; 82:3654-64.
7. Dawson CW, Laverick L, Morris MA, Tramoutanis G, Young LS. Epstein-Barr virus-encoded LMP1 regulates epithelial cell motility

and invasion via the ERK-MAPK pathway. J Virol. 2008; 82:3654–64.

8. Arduino PG, Porter SR. Oral and perioral herpes simplex virus type 1 (HSV-1) infection: review of its management. Oral Dis. 2006; 12:254-70.