

## Case Report

### Inferior Vena Cava Injury In An Elderly Man With Penetrating Abdominal Trauma

Reza Motalebi<sup>1</sup>, Mohammad Hadi Molseghi<sup>2</sup>, Arash Rezai Shahmirzadi<sup>3</sup>, Mahdi Babaei Hatkehlouei<sup>4</sup>, Sohrab Malek Mahmoudi<sup>2</sup>, Saeid Amirkhanlou<sup>5\*</sup>

1. Golestan University of Medical Sciences, Trauma Centre, 5 Azar Hospitals, Gorgan, Iran.

2. Clinical Research Development Unit (CRDU), Sayad Shirazi Hospital, Golestan University of Medical Sciences, Gorgan, Iran.

3. Student Research Committee, Golestan University of Medical Sciences, Gorgan, Iran.

4. Dentistry student, student research committee, Mazandaran University of medical science, Sari, Iran.

5. Department of Nephrology, Clinical Research Development Unit (CRDU), Sayad Shirazi Hospital, Golestan University of Medical Sciences, Gorgan, Iran.

#### Corresponding author:

Saeid Amirkhanlou

Department of Nephrology, Clinical Research Development Unit (CRDU), Sayad Shirazi hospital, Golestan University of Medical Sciences, Gorgan, Iran.

Phone: +989123965275

E-mail: [Arashrezaei198@yahoo.com](mailto:Arashrezaei198@yahoo.com)

#### Abstract:

Inferior vena cava injury in abdominal trauma is rare but it puts a big problem in front of trauma surgeon. Despite improvements in preoperative care, skills and surgical facilities, inferior vena cava injury mortality rate remains high. The most important factors that play a prominent role in mortality are presence of shock on admission, anatomic level of vena caval injury or other major vascular and visceral injuries. In this article we have reported successfully treated a case of the inferior vena cava injury after penetrating abdominal trauma in old age man with hemorrhagic shock, survived due to immediate laparotomy, successful surgical management with team approach and critical postoperative surgical management without any residual complication.

**Key Word:** Inferior Vena Cava, Massive haemoperitoneum, abdominal trauma, hemorrhagic shock

#### Introduction:

Injury to the inferior vena cava (IVC), is one of injuries in the abdomen, especially may be encountered in penetrating abdominal trauma. The possibility of damage to the

inferior vena cava in abdominal trauma was 3.2% (1) and mortality caused by this injury was 78% (2) and according to the progress achieved in the field of dealing with trauma patients, mortality rate has not been dramatically reduced. About one third of

patient's with inferior vena cava trauma would die on the way to hospital and the other one third would expire during 24 hours after the beginning of treatment due to massive hemorrhage and other abdominal injuries. The prevalence of abdominal vascular damage in patients with penetrating abdominal trauma is about 10 percent (3). Clinically, trauma to inferior vena cava may present with free intraperitoneal bleeding or retroperitoneal hematoma. (4) Retroperitoneal hematomas are classified in 3 areas, based on anatomic location. Region 1, in the central region of retroperitoneal, it lay over the diaphragmatic hiatus to the bifurcation of vena cava and aorta and on both sides is limited by the kidneys. Several factors (including blood pressure, anatomical level, damage or trauma to the other abdominal vessels) are predictors of survival in patients with vena caval penetrating trauma. Decrease in blood pressure on admission is seen in 56 % to 83 % of these patients as the main factor in determining the survival rate. (3-6).

The survival rate in these patients is also very dependent on the location of the damage to the inferior vena cava. Patient with injury to the infra renal part on inferior vena have a significantly higher survival rate than patients with damage to the adrenal and Para renal part. (7, 8) Easy access to the site of injury could partly explain the higher survival of patients with injuries to infer renal part of inferior vena cava. In this study, a case of inferior vena cava injury in a patient with penetrating abdominal Trauma and shock has been reported.

### Case Report:

A 51-year-old male patient with anterior abdominal wall laceration, 4 cm below the right costal edge with evisceration of small intestine was referred to the emergency room (Fig 1). In the initial physical examination of patient's vital signs, blood pressure (BP) 70/Pulse mmHg and pulse rate (PR) 136 beats/min, respiratory rate (RR) was 28 per minute and body temperature (T) 36.5C. The patient was lethargic with the spontaneous breathing and tachypnea. The neck veins were collapsed and lung auscultation was normal. Abdomen was guarded and tense, and there was no external bleeding. According to abdominal guarding and suspected hemorrhagic shock, patient immediately transferred to the operating room for emergency laparotomy. After the laparotomy, about 2 liters of haemoperitoneum was evacuated and peritoneum was packed by multiple loan gauzes. (Fig 1) After packing blood oozing from segment 6 of the liver and gallbladder damage was evident.

In the meantime, the patient's pulse pressure was reduced, with aggressive serum therapy blood pressure reached to 110/80 mmHg. Then blood transfusion was performed for patient with O<sup>+</sup>. Pringle maneuver was attempted by the presence of massive bleeding which led to slightly less bleeding and then liver Pack was performed. Further evaluation showed cystic artery damage which was also clamped.

At this stage to reduce pressure on the abdominal great vessels, the liver packs were removed, and bleeding was continued (despite performing Pringle maneuver), showing the possibility of damage to

retrohepatic vein or IVC. In order to explore IVC, right medial rotation of viscera and right colon and also release of major abdominal vein was performed. Through & through IVC damage was evident. After exploration of zone I hematoma, active bleeding was observed. The bleeding was controlled by applying pressure with the finger immediately. Right renal vein exploration was also done and the site of injury was superior to renal vein. Packing was also performed at the site of bleeding and the patient vital sign was stable. To repair IVC, the vein was taken at lengths by Sattinsky's clamp, which was not useful. Then we put pressure by finger on the site of laceration and finger removed frequently for restoration. The patient was receiving a transfusion of 4 units pack cell (P.C).in order to perform restoration, initial laceration was repaired on lateral part and then in order to repair IVC vein on aorta site, aorta isolation was done. Repair was done by 4-0 prolene. (Fig2)

At the end of the restoration of the patient's blood pressure reached 70/pulse mmHg and PR=130 beats/min. The final evaluation of patient was done and by ensuring about the rise of BP and good iliac vessels pulse, liver and small intestine laceration was restored with horizontal chromic suture. Ligation of cystic artery and cholecystectomy was performed, there was a slightly oozing and perihepatic packing was performed. At the end, abdominal wash with warm saline was performed. The injured area was packed by 10 loan gauzes and of abdominal wall and skin was repaired. Central venous (CV) line was taken from the right jugular vein. Along

with taking 10 units of P.C and 5 units of fresh frozen plasma (FFP), the patient was transferred to intensive care unit (ICU) and intubated. In order to avoid complications of massive transfusion, receiving FFP and platelets (9 units) was continued. The day after surgery, the patient was fully alert vital signs was stable and patient was intubated. The second day after surgery, the patient was depacked and the restoration of IVC vein was successful without any leak. Renal vein was intact and renal function was good. After securing the patient's condition and adequate liver hemostasis, abdominal wall and skin were completely restored, packs were evacuated and the patients transferred to ICU. Three days after the first surgery the patient became oral feeding (PO) with fluid and after 5 days, the diet was changed to smooth and soft food. Because of dyspnea and tachypnea, five days after surgery, chest study was performed by thoracic CT scan. Because of two-sided pleural effusion, Chest tube was inserted and blood splash was evacuated. At the sixth day the patient was transferred to the ward with good general condition. After 4 days left chest tube and a day later the right one was discharged. The patient was discharged with good general condition. In the after discharge period, patient was followed for 9 months and he was uneventful.

### Discussion:

Deaths from trauma to inferior vena cava, despite the progress made in the field of care for trauma patients such as the possibility of transfer of patients to medical centers, expansion and equipping health centers and progress on damage control surgery remains

high. Triad of acidosis, hypothermia and coagulopathy, is the leading cause of death in these patients. Penetrating trauma to inferior vena cava is almost always along with other major vascular injury or intra-abdominal viscera. At the same time damage to the liver, stomach, duodenum, pancreas are such common cases. Nearly 10 percent of patients with penetrating injuries to inferior vena cava suffered from damage to the aorta or portal vein in particular (the major vessels). Studies on this subject have shown that by increasing the number of injuries, the mortality rate of these patients' increases by steep (9, 10).

Patients with penetrating abdominal Trauma, presenting with shock, or positive findings on physical examination such as guarding, generalized tenderness or herniated viscera or positive peritoneal lavage, should be immediately undergo surgery. The first step in the surgery of patients with inferior vena cava injuries is bleeding control. Free intra-abdominal hemorrhage without retroperitoneal hematoma is the cause of decreased survival in these patients. In reported patient in this study, we prevented massive hemorrhage and hypotension by packing. In one of the studies on this subject, on patients who had bleeding from the inferior vena cava, limited by retroperitoneal hematoma, mortality rate was about 26 percent, while the survival rate in patients without retroperitoneal hematoma was in 74% of cases (11). In such patients with retroperitoneal hematoma causing the vein tampons, immediately after the exploration of hematoma and recognizing the site of injury bleeding control via direct

pressure or controlling the proximal and distal to the site of the laceration must be done. In other patients with similar conditions were treated by same surgical team, distal and proximal control was achieved on applying Sattinsky's vascular clamps (12), but in the present case, this action is not successful. So to control bleeding, direct pressure was used. Finally, the most important success factors in the treatment of these patients can be timely diagnosis and resuscitation of the patient and also surgery without wasting time. Selection of appropriate surgical procedure according to the patient's condition and absence of severe trauma, visceral and vascular noted at the same time.

### **Conclusion:**

We present a case of successful repair of IVC injury with massive haemoperitoneum by venorrhaphy. We conclude that this technique can be performed by surgeons and decrease the risks of subsequent venous occlusion and lower limb edema resulting from ligation of vein.

### **References:**

1. Navsaria P, Bruyn P, Nicol A. Penetrating abdominal vena cava injuries. *Eur J Vasc Endovasc Surg*. 2005; 30: 499-503.
2. Szabo KG, Csiszko A, Sasi L, et al. Successful treatment of retrohepatic inferior vena cava injury: a report of two cases. *Magy Seb*. 2011; 64: 242- 245.
3. Hampton M, Bew D, Edu S, Nicol A, Naidoo N, et al. An urban trauma center experience with abdominal vena cava

injuries. *S Afr J Surg.* 2016 Mar;54(1):36-41.

4. Shah P, Shah N. Penetrating abdominal trauma- a case of isolated vena cava injury. *Bombay Hospital J.* 2008; 50.

5. Thal ER, O'Keeffe T. Operative exposure of abdominal injuries and closure of the abdomen. In: Souba WW, Fink MP, Jurkovich GJ, et al. *ACS surgery principles and practice.* 6nd ed. New York: WebMD; 2007; 1294-1295.

6. Formisano V, Di Muria A, Muto G, Aveta A, Piscitiello F, Giglio D. Inferior vena cava gunshot injury: case report and a review of the literature. *Ann Ital Chir.* 2006; 77: 173-7.

7. Ozkokeli M, Ates M, Topaloglu U, Muftuoglu T. A case of successfully treated inferior vena cava injury. *Tohoku J Exp Med.* 2003; 200: 99-101.

8. Klein SR, Baumgartner FJ, Bongard FS. Contemporary management strategy for

major inferior vena caval injuries. *J Trauma.* 1994; 37: 35-41.

9. van Rooyen PL, Karusseit VO, Mokoena T. Inferior vena cava injuries: a case series and review of the South African experience. *Injury.* 2015 Jan; 46(1): 71-5.

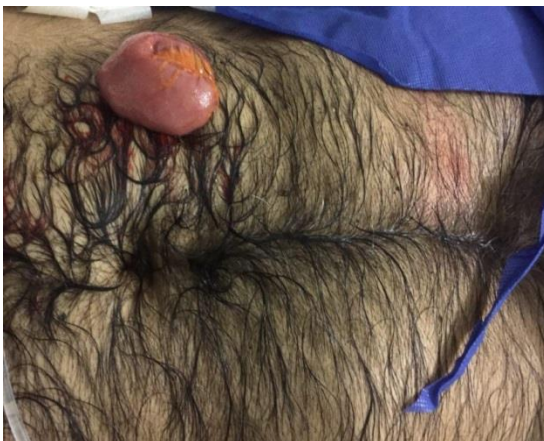10. Paul JS, Webb TP, Aprahamian C, Weigelt JA. Intraabdominal vascular injury: are we getting any better. *J Trauma.* 2010 Dec;69(6):1393-7.

11. Sullivan PS, Dente CJ, Patel S, Carmichael M, Srinivasan JK, et al. Outcome of ligation of the inferior vena cava in the modern era. *Am J Surg.* 2010 Apr; 199(4):500-6.

12. Hashempour MR, Motalebi R, Mosallami SM, Mortazavi N. A Successful Management of Juxta-Renal Inferior Vena Cava Injury after Penetrating Trauma: A Case Report. *J Trauma Treat* 2016, 5:4.

Fig1: A): anterior abdominal wall laceration and evisceration of small intestine. B): massive haemoperitoneum

A:



B:

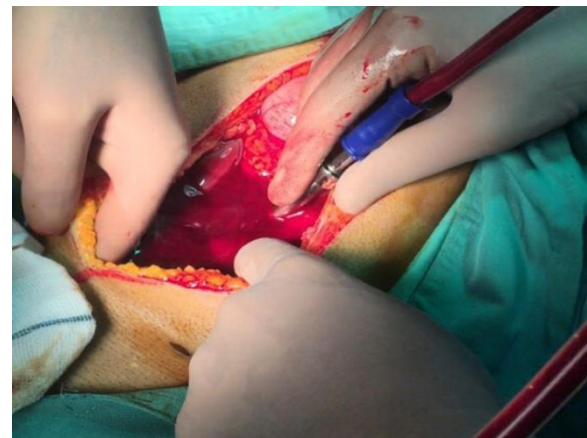
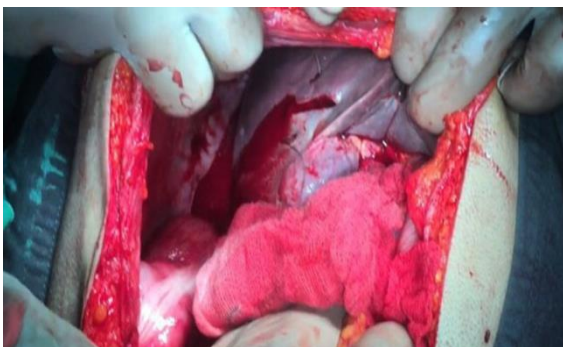




Fig2: A): right lobe of the liver perforation with oozing. B): Primary repair of IVC (Venorrhaphy)

A:



B:

