

Case Report

Femoral Neck Fracture in a Three-Year-Old Child; Case Report

Salman Ghaffari 1, Mehran Razavipour 2, Masoud Shayestehazar 3, Abolfazl Ghadiri 4*

1. Associate professor of orthopedic surgery, Orthopedic research center, Mazandaran university of medical science, Sari, Iran.
2. Assistant professor of orthopedic surgery, Orthopedic research center, Mazandaran university of medical science, Sari, Iran.
3. Associate professor of orthopedic surgery, Orthopedic research center, Mazandaran university of medical science, Sari, Iran.
4. Orthopedic Resident, Orthopedic Research center, Mazandaran university of medical science, Sari, Iran.

*correspondence: **Abolfazl Ghadiri**, Orthopedic Resident, Orthopedic Research center, Mazandaran university of medical science, Sari, Iran. Email: Saghadiri.70@gmail.com

Abstract:

Background: Femoral neck fracture is a rare complication that compromise less than 1% of the all children's fractures. There are different systems to classify it. The Delbet classification system is the most common system for describing femoral neck fractures in children, identifying its variants helps predict complications and make medical decisions. Our aim in this study is to introduce a rare form of femoral neck fractures associated with displacement in children that is not in any of the common categories.

Case Presentations: The patient is a 3-year-old girl with a right femoral neck fracture due to an accident. At first, a closed reduction was performed under General anesthesia, but because of failure, open surgery was performed. During the operation, a detached piece of the superior part of the femoral neck along with physis, was seen apart from other parts, which after reduction was fixed by two pins. at the end, a Spica cast was used and eventually, after two days, the child was discharged in a good general condition.

Conclusion: Since our report introduces a new type of femoral neck fracture in children that is not in the Delbet classification, it is suggested that this type of fracture be added to the classification.

Keywords: Femoral neck fracture, Delbet classification, Close reduction.

Introduction:

Femoral neck fracture is a rare that accounts for less than 1% of all childhood fractures (1, 2). Compared to the elderly who would have a hip fracture due to osteoporosis in a minor fall, 90% of children need to be exposed to severe trauma such as motor vehicle accidents and falling from high altitude crash a fracture due to their high bone mineral density(2, 3). The Delbet classification system (1907) is the most common system for describing femoral neck fractures in children, later modified by Colonna (1929)(1, 4). The type I is transphyseal fracture, the second type is transcervical fracture (the most common type), the third type is cervicotrochanteric fracture, and the fourth type is extracapsular, intertrochanteric fractures. These fractures are also divided into two types of with and without displacement(5).

In addition, the Delbet classification also recognizes that the fracture site is threat to AVN; the ArbeitsgemeinschaftfürOsteosynthesefragen (AO) classification system was published in 2007 that children's transphyseal fracture (DelbetI) from femoral neck fractures and intertrochanteric (Delbet II-IV)(6).

This type of fracture causes serious complications, including: avascular necrosis (AVN), pseudoarthrosis, coxavara, delayed union, non-union, premature physeal closure, and leg length discrepancy (LLD)(1, 7, 8).

AVN is the most common and severe complication of this fractures in children, accounting for 59% of the complications(9).

Therefore, a proper initial treatment for these patients is necessary to reduce complications (10). Since the pediatric hip anatomy is different from that of adults and cannot be treated as "young adults", a complete understanding of children's anatomy is important to ensure proper treatment and understanding the complications associated with it(7).

There are several treatments that are selected based on the child's age, type of fracture and displacement (8). In general, this type of fracture in children is treated by two methods: open reduction and internal fixation (ORIF) and Closed Reduction and Internal Fixation (CRIF)(7). However, the ORIF method provides a better reduction with fewer complications, including decreasing the risk of avascular necrosis compared to CRIF(11).

The purpose of this study is to introduce a rare type of femoral neck fracture with displacement in children, which is more complicated compared to the other types in terms of location and number of fractures line`, and is much more difficult in terms of the method used to fix and stabilize the fracture.

Case presentation:

The patient is a three-year-old girl who was transferred to our hospital due to a car accident. The radiographic findings showed right femoral neck fracture (figures 1 and 2). After the examinations, and rulling out any possible internal injuries, the patient was transmitted to the operation room to fix the fracture Initially under general anesthesia and guided by C-ARM closed reduction was

attempted but we failed to fix and stabilize the fragmented bone parts so the decision was made to do an open reduction (ORIF with Pin), so the fracture site was exposed after Prep and drape with a lateral Incision.

During the operation, a detached piece of the superior part of the femoral neck along with physis, was seen apart from other parts, which after reduction was fixed by two pins. (Figures 3 and 4) retrospectively we identified the detached fragment that included about half of the physis.(figure 2) at the end, a Spica cast was used and eventually, after two days, the child was discharged in a good general condition. The patient was revisited and the surgery site was examined regularly by means of radiographic imaging and finally, after 12 weeks, the pins were removed.

At the three-year follow up, there was no difference in limb length and no walking difficulty. A radiographic image was taken from the operation site before the child was discharged, ten days post-discharge, three months later and three years after the operation, (figures 6, 7 and 8). In the radiograph taken three years after the operation, the spherical head was preserved and no signs of avascular necrosis were observed. But the neck of the thigh was shorter than the opposite side and had a slight varus.

Discussion:

We present a case of femoral neck fracture that cannot be classified according to Delbet classification. Transcervical fracture with a second fracture line involving extending from primary fracture line to physis causing

separation of about half of the physis from epiphysis (figure 1).

Kumar et al. also reported a 10-year-old case following a road accident. that the hip has a fracture but However, this fracture, like our case, was not in any of the delbet classification groups and was in a new category of cervicotrochanteric with subtrochanteric extension fracture(9).

Paveon et al. (2008-2013) reviewed a study of 8 cases of femoral neck fractures in a case series study. All patients in this study were treated in a closed reduction method using two cannulated screws

The researchers concluded in this study that the age of the patients and delbet typing are important in choosing the type of treatment. Also reduction and stabilization during the first 6 hours after the trauma reduced the incidence of avascular necrosis (12).

Prakash et al. reported complete separation of proximal epiphysis of the femur in a 2-year-old girl who was then treated with open-reduction and internal fixation and a K-Wire. Three months after the surgery, the fracture was healed and eight months later the child could stand and walk without help(13).

Lee et al. Reported hip fracture and dislocation with complete transepiphysal detachment in a 14-year-old boy, who, had sustained anterior femoral head dislocation. Due to the emergent nature of the condition, the patient was transferred to the operating room in less than 6 hours(14).

According to the studies, femoral neck fracture in children is divided into four

types, which do not include the fracture described in this case report which is a rare femoral neck fracture. As the studies have noted, we also attempted C-ARM guided closed reduction initially, which proved ineffective and was immediately followed by open surgery and reduction and was fixed using two pins.

Conclusion

Since our report introduces a new type of femoral neck fracture in children that is not in the Delbet classification, it is suggested that this type of fracture be added to the classification.

Acknowledgments

The authors express their gratitude and appreciation to the parents of the above-mentioned child for their support and permission to publish this report.

References:

1. Akkari M, Santili C, Akel E, Angelim R. Femoral neck fracture in children: treatment and complications. *Revista da Associação Médica Brasileira*. 2015;61(1):5-7.
2. AlKhatib N, Younis MH, Hegazy A, Ibrahim T. Early versus late treatment of paediatric femoral neck fractures: a systematic review and meta-analysis. *International orthopaedics*. 2019;43(3):677-85.
3. Ratliff A. Fractures of the neck of the femur in children. *The Journal of bone and joint surgery British volume*. 1962;44(3):528-42.
4. Colonna PC. Fracture of the neck of the femur in children. *The American Journal of Surgery*. 1929;6(6):793-7.
5. Norton B, Mulligan R, Rush J, Kelly DM, Warner Jr WC, Sawyer JR. Proximal femoral fractures in children and adolescents: an update. *Current Orthopaedic Practice*. 2012;23(5):429-34.
6. Dial BL, Lark RK. Pediatric proximal femur fractures. *Journal of orthopaedics*. 2018;15(2):529-35.
7. Bali K, Sudesh P, Patel S, Kumar V, Saini U, Dhillon M. Pediatric femoral neck fractures: our 10 years of experience. *Clinics in orthopedic surgery*. 2011;3(4):302-8.
8. Boardman MJ, Herman MJ, Buck B, Pizzutillo PD. Hip fractures in children. *JAAOS-Journal of the American Academy of Orthopaedic Surgeons*. 2009;17(3):162-73.
9. Kumar M, Chandrabau K, Bhaskaran V, Jindal R. Unusual proximal femur fracture in children treated with PHILOS plate and review of literature. *Journal of Orthopaedics and Allied Sciences*. 2017;5(1):6-9.
10. Bukva B, Abramović D, Vrgoč G, Marinović M, Bakota B, Dučić S, et al. Femoral neck fractures in children and the role of early hip decompression in final outcome. *Injury*. 2015;46(6):44-7.
11. Song K-S. Displaced fracture of the femoral neck in children: open versus closed reduction. *The Journal of bone and joint surgery British volume*. 2010;92(8):1148-51.
12. Pavone V, Testa G, Riccioli M, Di Stefano A, Condorelli G, Sessa G. Surgical treatment with cannulated screws for

pediatric femoral neck fractures: A case series. *Injury*. 2019;50(2):40-4.

13. Pal CP, Kumar D, Singh P, Gaurav V. Complete Traumatic Separation of Proximal Femoral Epiphysis in A 2 Year Old Child. *Journal of orthopaedic case reports*. 2014;4(3):29-31.

14. Lee D-H, Park J-W, Lee S-H. A transepiphyseal fracture of the femoral neck in a child with 2 widely displaced Salter-Harris III fragments of the capital femoral epiphysis. *Journal of orthopaedic trauma*. 2010;24(2):1259.

Tables and Charts:

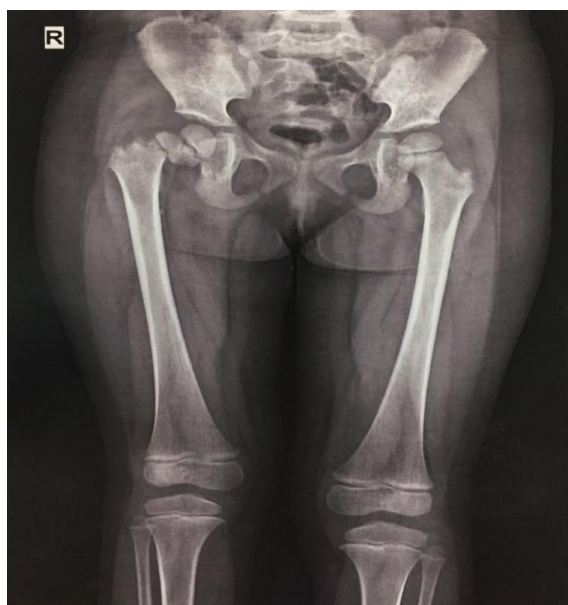

Figure 1: Initial radiography (before operation).

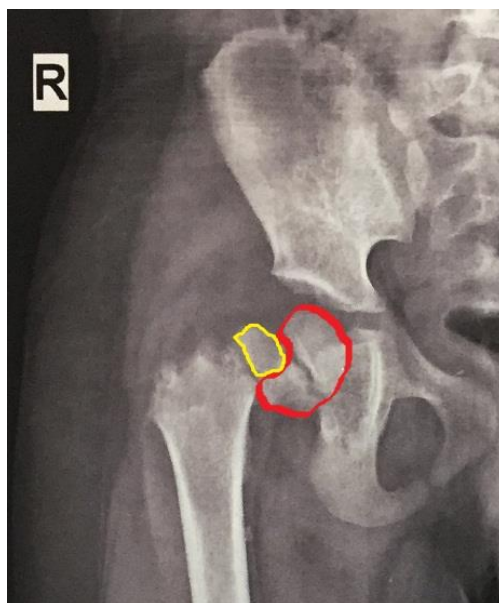


Figure 2: Radiograph focused on the fracture (red circle around the metaphysis and epiphysis)

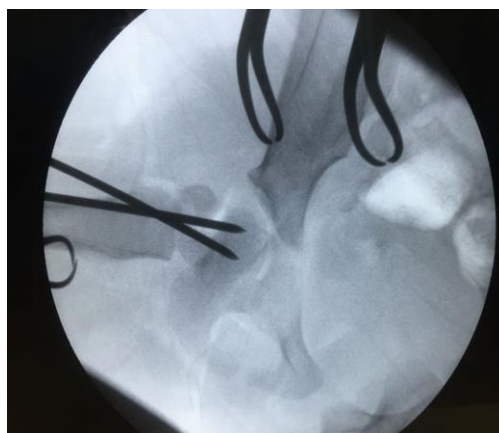


Figure 3: C-ARMLateral radiograph during the operation

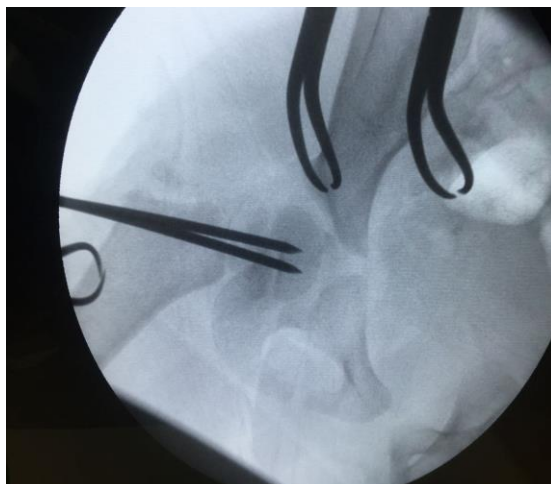


Figure 4: C-ARM anteroposteriorradiograph during the operation.

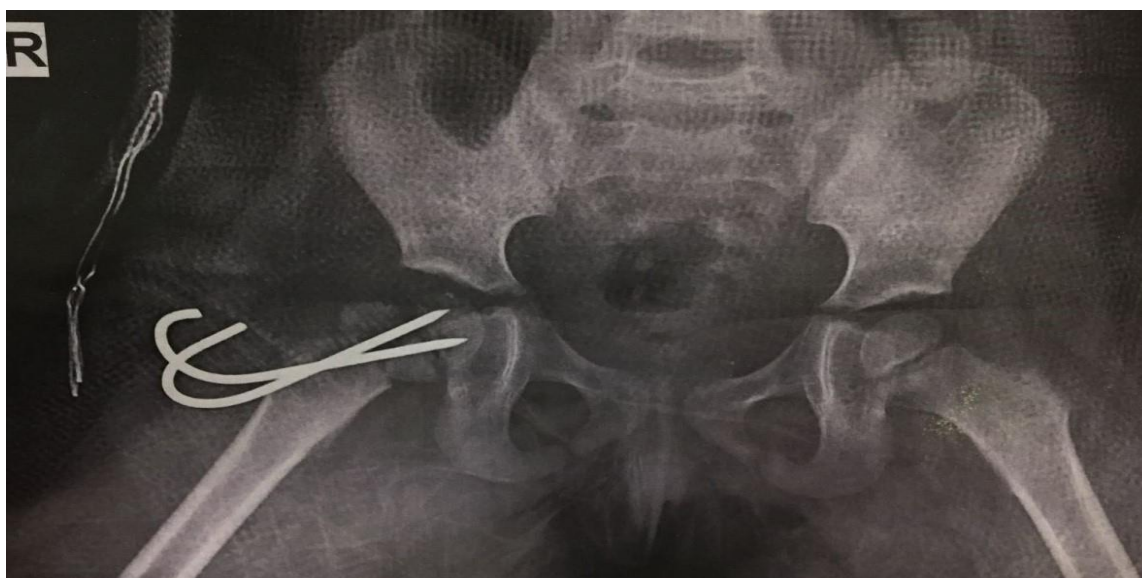

Figure 5: Initial post-op radiograph.

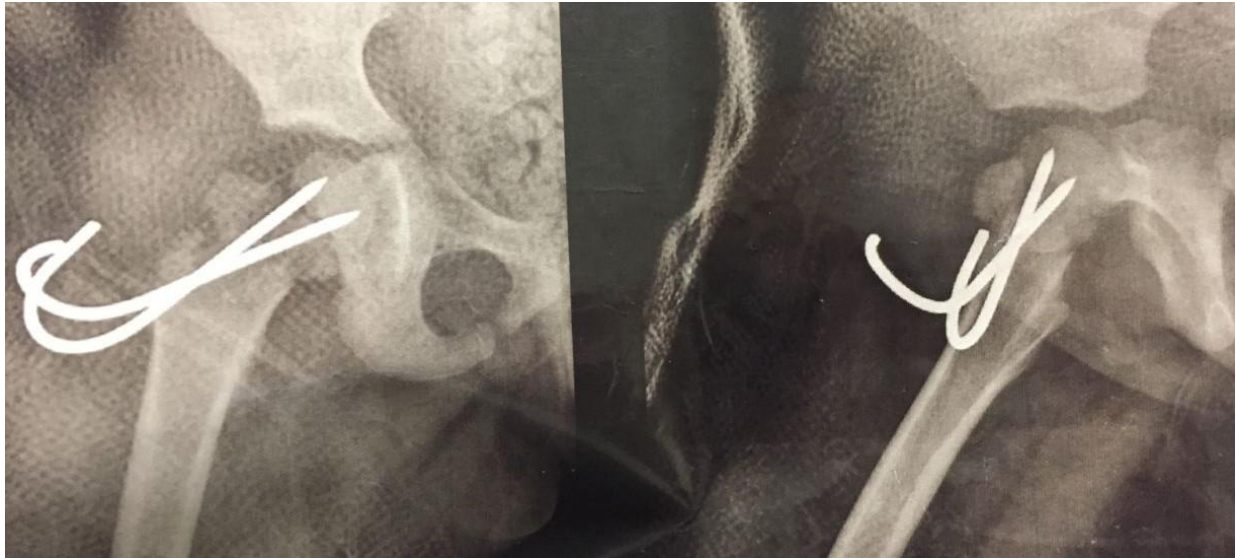


Figure 6: 10 day post-op radiograph.

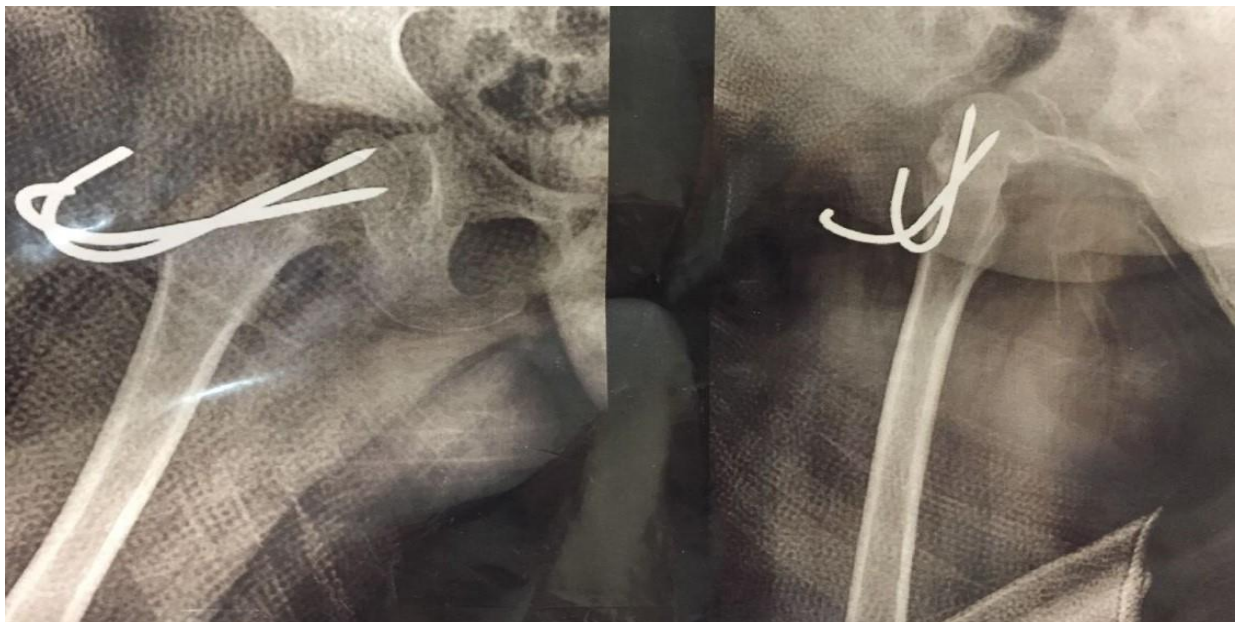


Figure 7: 3 month post-op radiograph.

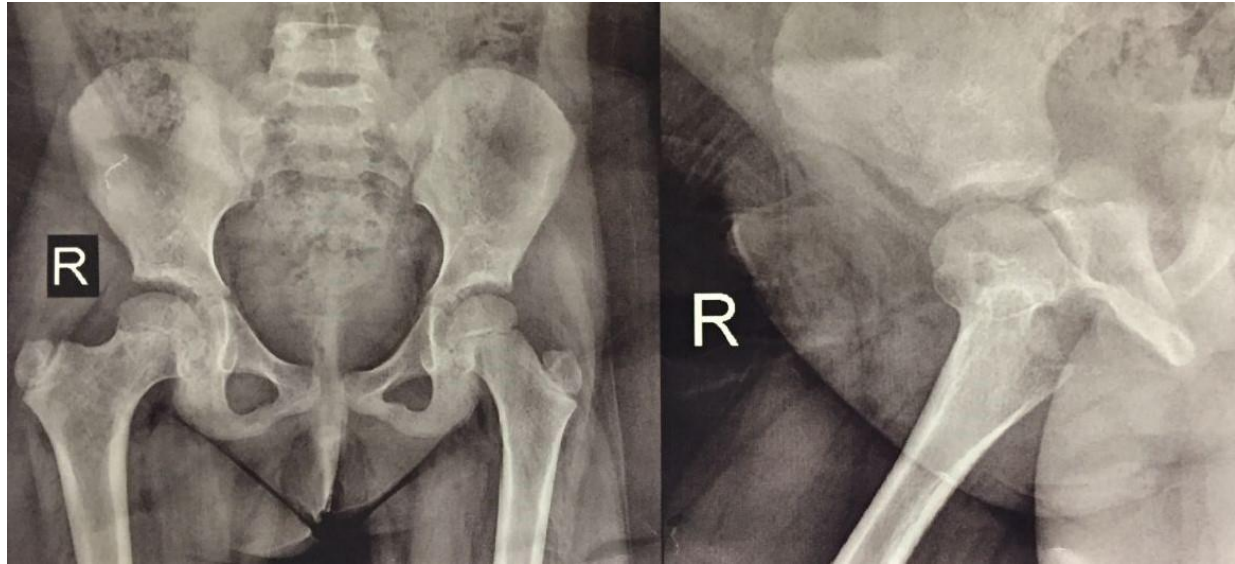


Figure 8: 3 year post-op radiograph.