

Brief Report

Management of Rolando and Bennett Fractures Treatment with Pin and Plaster (A New Technique)

Masoud Shayesteh Azar 1, Mohammad Hossein Kariminasab 1*, Salman Ghaffari 1, Mani Mahmoudi 2, Abolfazl Kazemi 3, Shadi Shayesteh Azar 4.

1. Associated Professor of orthopedic surgery, Orthopedic Research center, Mazandaran university of medical science, Sari, Iran .
2. Assistant professor of orthopedic surgery, Orthopedic Research center, Mazandaran university of medical science, Sari, Iran.
3. Orthopedic resident, Orthopedic Research center, Mazandaran university of medical science, Sari, Iran
4. Medical Student, Ramsar International University, Mazandaran, Iran.

*correspondence: **Mohammad Hossein Kariminasab**, Associated Professor of orthopedic surgery, Orthopedic Research center, Mazandaran university of medical science, Sari, Iran. Email: mhkariminasab@gmail.com

Abstract:

Intra-articular fractures of Thumb are the most common fractures occurred in children and elderly; divided into Bennett & Rolando fractures. The purpose of this article is to introduce new approach for these fractures. In this approach, after pre-surgery techniques; a 1.5-2 mm pin is placed in the proximal distal phalanx. Next, the best reduction is achieved by imposing pulling through the pin and rotating motion under C-Arm. Short forearm cast is then used after that cast changing to thumb Spica cast and the pin is incorporated in the cast, the position of thumb during casting in abduction and pronation depends on the reduction under C-Arm. After the operation, the reduction is controlled by radiography. Within 4-6 weeks, the cast is removed, the pin is taken out, and active and passive joint movements begin. In this study, we introduce our technique used in the management of 4 cases. The results were found to be promising, with an excellent range of motion. In spite of controversial choice of treatments, we recommend this method as a cost-benefited, acceptable and applicable method for patients and physicians.

Keywords: Rolando Fractures, Bennett, Treatment, Pin and Plaster.

Introduction:

Thumb fractures, the most common fractures occurs in children (age 0-16 years) and the elderly (age <65 years) (1). About 40% of the hand's function provided by the thumb. Total disability of the thumb decrease 22% of bodily function (1). Acute traumatic injuries of thumb are estimated to occur in 4% of the hand's fractures (2). Thumb metacarpal fractures because of its multiple complications, are unique.

malformation and Angular deformity and different movement problems caused by CMC fractures. Fractures of the first metacarpal can be divided into intra-articular and extra-articular fractures. Intra-articular fractures are subdivided into (1) Bennett, (2) Rolando(3).

Rolando fractures included 7-21% of all fractures of the first metacarpal. The mean age of the fracture between 20 and 40

years(4) . Male to female ratio is about 2: 1 (5) .

In Rolando fractures, there is usually a T- or Y-shaped intra-articular fracture of the base of the thumb metacarpal and trapeziometacarpal involved. Volar carpal ligament, prevent them from the volar displacement. But the dorsal parts displaced by abductor pollicis longus ligaments. in all first metacarpal fractures, The contribution of Rolando fractures is estimated to be between 7-21%(6) .

In Bennett fractures, fracture of the base of the first metacarpal bone which extends into the carpometacarpal (CMC) joint. That's always accompanied by some degree of subluxation or frank dislocation of the carpometacarpal joint(7) . Bennett fractures into 3 types, with type 1 representing a fracture with a large single ulnar fragment and subluxation of the metacarpal base. A type 2 fracture represents an impaction fracture without subluxation of the thumb metacarpal. Finally, a type 3 fracture represents an injury with a small ulnar avulsion fragment in association with metacarpal dislocation (8) .

Many methods of treatment were suggested as close reduction and casting , closed reduction and percutaneous intra-articular or extra-articular Kirschner wire (K-wire) fixation or external fixator , and open reduction and rigid internal fixation with K-wires or lag screws or plate .if there is severe comminution, the treatment of choice is controversial .because attempts at operative restoration of the articular surface

are frustrating , so new technique of pin and plaster was suggested.

Patient Demographics:

4 male patients experiencing intra-articular Fractures of the first metacarpal bone due to falling down were treated by our pin and plaster technique. The mean age of patients was 32 years (range, 21 to 80 years). The left thumb was affected in all 4 patients. All of them were operated under general anesthesia. The mean time of delay since injury until the operation was 3.5 days (range, 1 to 5 days). The mean operative time is 40 minutes. The patients were followed-up up to 6 months.

Surgical Technique:

In this technique, the patients, diagnosed with the comminuted fracture of first metacarpal proximal and first CMC joint enrolled, all patients undergo prep and drape from the fingertip to axilla and controlled with C-Arm after proper anesthesia. Then, a 1.5-2 mm pin is placed in the proximal distal phalanx. Next, the best reduction is achieved by imposing pulling through the pin and rotating motion under C-Arm. Short forearm cast is then used after that cast changing to thumb spica cast and the pin is incorporated in the cast. The position of thumb during casting in abduction and pronation depends on the reduction under C-Arm. After the operation, the reduction is controlled by radiography. Within 4-6 weeks, the cast is removed, the pin is taken out, and active and passive joint movements begin.

Results:

All patients were satisfied by the results. None of them had any pain after 1 months and the median VAS score was 0. The mean time of cast and K-wire removal was 35 days. There was no pin tract infection. They could all lift the thumb off the table with the palm of the hand resting on it (reposition). The average grip strength after 8 months was 88% of the contralateral side. Everybody could resume their normal activities. The range of motion of CMC was full. joints spaces were restored with no gap. No arthritic changes were seen during our short period of follow-up.

Discussion:

Extra-articular fractures and dislocations of thumb are often required treatment without surgery. But intra-articular fractures are often cured with surgery (9, 10).

Rolando fracture treatment depends on the severity of the thumb base crushing (crushing rate of the thumb's base) and the degree of displacement of the crack. Open reduction and internal fixation used in great fracture fragments (11) . Choice treatments into two categories: surgical and non-surgical treatments are divided. In the nonsurgical management is recommended that the dorsal and volar bands diachylon with massage for a month. Also, when the plaster used can be removed after 4-5 weeks and limited gestures and taps starts. There are different options for surgical treatments include: closed reduction, open reduction, internal and external fixation and skin kirschner wires(12) .

The use of oblique traction with kirschner wires that is used in fracturing Rolando and

bennett and is very common. The wires are inserted obliquely to the base of the thumb metacarpal. Open reduction and internal fixation of wires in kirschner and t-plate is used(13-15) . The crunch of bone, the treatment of choice is very controversial because articular surface reconstruction surgery with very frustrating and annoying or impossible. For this type of fracture external fixator is recommended. Including: quadrilateral, triangular, uniplanar use different pins(16) . In addition, in cases where the articular incongruity is more than 2mm surgical procedures is recommended(17) .In bennett fractures, closed-reduction and casting methods is common. In the closed reduction, can be cast if the fracture pieces movement is less than 1mm and anatomic position of bones are correct. Otherwise uses the K-wire fixation(18, 19) . Open reduction techniques is used for volar fracture displacement of more than 1 mm. In large volar fractures, herbert methods or screws AO (2.7mm) are used in small volar fractures use the K-wire. Cast should not be opened for 4 to 6 weeks(3) .

All methods of treatment have advantages and disadvantages. it is not always possible to restore articular surface because of comminution of the fracture. In our opinion, our pin and plaster technique offer an excellent solution for a comminuted fracture of the base of the first metacarpal. The new method is inexpensive and simple to use and also decrease the operative time ..this technique have no dissection or devascularization of soft tissue and bone and have the ability to reduce fracture fragments and realign joint surfaces by ligamentotaxis

The disadvantages are that it is bulky, may be caught on the patient's clothes, and may result in pin tract infection.

References:

1. Carlsen BT, Moran SL. Thumb trauma: Bennett fractures, Rolando fractures, and ulnar collateral ligament injuries. *J Hand Surg Am.* 2009;34(5):945-52.
2. Liverneaux P, Ichihara S, Hendriks S, Facca S, Bodin F. Fractures and dislocation of the base of the thumb metacarpal. *Journal of Hand Surgery (European Volume).* 2015;40(1):42-50.
3. Soyer AD. Fractures of the base of the first metacarpal: current treatment options. *The Journal of the American Academy of Orthopaedic Surgeons.* 1999;7(6):403-12.
4. Vichard P, Tropet Y, Nicolet F. Longitudinal pinning of fractures of the base of the first metacarpal. *Annales de chirurgie de la main: organe officiel des sociétés de chirurgie de la main.* 1981;1(4):301-6.
5. Griffiths J. Fractures at the base of the first metacarpal bone. *Bone & Joint Journal.* 1964;46(4):712-9.
6. Bruske J, Bednarski M, Niedziedz Z, Oyluk A, Grzeszewski S. The results of operative treatment of fractures of the thumb metacarpal base. *Acta orthopaedica belgica.* 2001;67(4):368-73.
7. Brownlie C, Anderson D. Bennett fracture dislocation - review and management. *Australian family physician.* 2011;40(6):394-6.
8. Gedda K-O. Studies on Bennett's fracture. *Acta Chir Scand.* 1954:5-114.
9. Diaz-Garcia R, Waljee JF. Current management of metacarpal fractures. *Hand clinics.* 2013;29(4):507-18.
10. Buchler U, McCollam SM, Oppikofer C. Comminuted fractures of the basilar joint of the thumb: combined treatment by external fixation, limited internal fixation, and bone grafting. *The Journal of hand surgery.* 1991;16(3):556-60.
11. Proubasta I. Rolando's fracture of the first metacarpal. Treatment by external fixation. *Bone & Joint Journal.* 1992;74(3):416-7.
12. Surzur P, Rigault M, Charissoux J, Mabit C, Arnaud J. Recent fractures of the base of the 1st metacarpal bone. A study of a series of 138 cases. *Annales de chirurgie de la main et du membre supérieur: organe officiel des sociétés de chirurgie de la main= Annals of hand and upper limb surgery.* 1993;13(2):122-34.
13. Gelberman RH, Vance RM, Zakaib GS. Fractures at the base of the thumb: treatment with oblique traction. *J Bone Joint Surg Am.* 1979;61(2):260-2.
14. Leibovic SJ. Treatment of Bennett's and Rolando's Fractures. *Techniques in hand & upper extremity surgery.* 1998;2(1):36-46.
15. Carlsen BT, Moran SL. Thumb trauma: Bennett fractures, Rolando fractures, and ulnar collateral ligament injuries. *The Journal of hand surgery.* 2009;34(5):945-52.
16. Niempoog S, Waitayawinyu T. Comminuted Rolando's fractures: treatment with modified wrist external fixator and transmetacarpal pinning. *JOURNAL-MEDICAL ASSOCIATION OF THAILAND.* 2007;90(1):182.

17. Thurston A, Dempsey S. BENNETT'S FRACTURE: A MEDIUM TO LONG-TERM REVIEW. Australian and New Zealand Journal of Surgery. 1993;63(2):120-3.

18. Bienfait JC, Chantraine A. [Continued traction and rehabilitation in

Bennett fractures (author's transl]. J Belge Rhumatol Med Phys. 1973;28(3):109-17.

19. Foster RJ, Hastings H, 2nd. Treatment of Bennett, Rolando, and vertical intraarticular trapezial fractures. Clin Orthop Relat Res. 1987(214):121-9.

Tables and Charts:

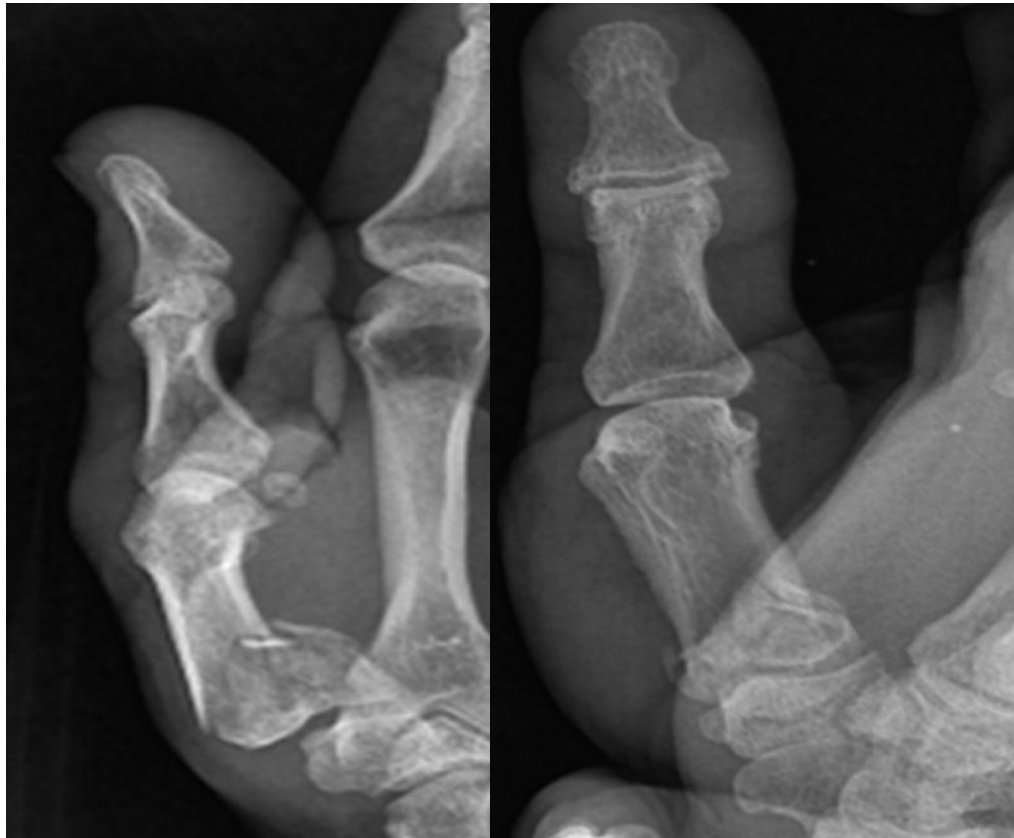


Figure 1: Rt rolando fx.

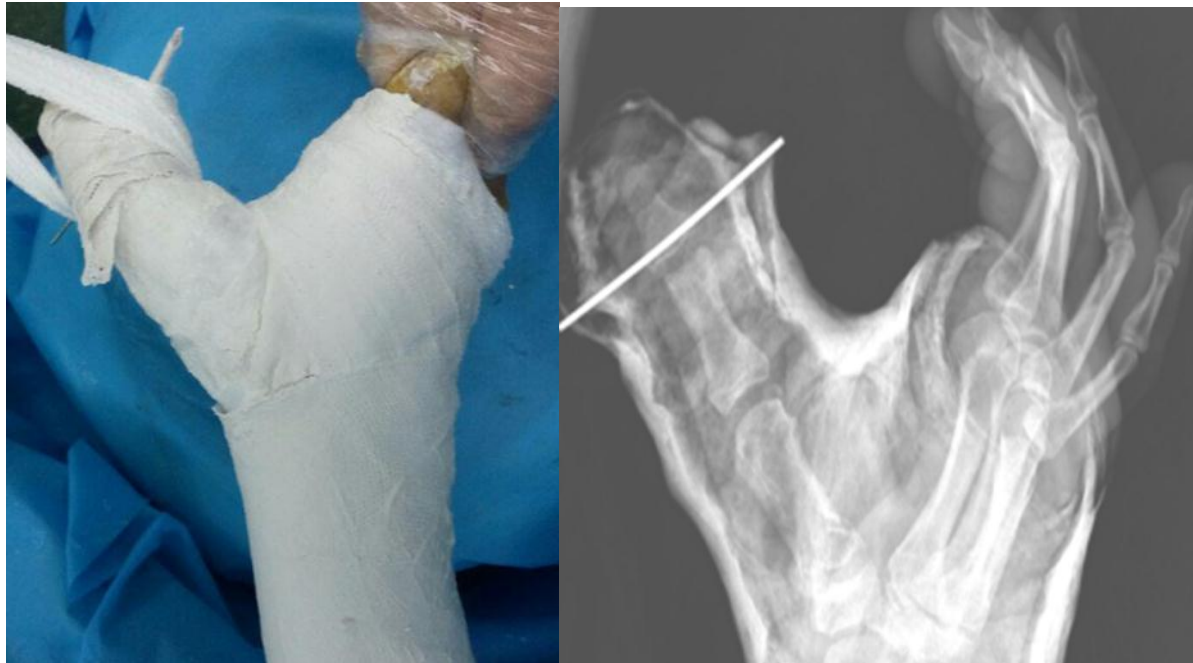

Figure 2: post optative x-ray.