

## Original Article

### Histological Effect Of Hydroalcoholic Extract Of Clover On Oxidative Stress And The Formation Of Ovarian Follicles In Wistar Rats

Ali Akbar Amiri<sup>1</sup>, Hanieh Bagheri<sup>1\*</sup>, Mahdiah Raeiszadeh<sup>1</sup>

1. Faculty of Veterinary Medicine, Islamic Azad University of Sanandaj, Sanandajm Iran.

**\*Corresponding author:** Hanieh Bagheri, Professor, Oral, and Maxillofacial Radiology Department, Dental School, Islamic Azad University of Medical Sciences, Tehran, Iran. . E-mail: ar\_talai@yahoo.com, <https://orcid.org/0000-0002-2271-1001>

#### Abstract:

**Introduction:** Nowadays, infertility problems such as lack of follicle formation with various follicle-stimulating compounds, antiestrogenic compounds such as clomiphene, tamoxifen, and gonadotropins such as FSH and LH have been treated. The aim of this study was the histological effect of hydroalcoholic clover extract on oxidative stress and the formation of ovarian follicles in female Wistar rats.

**Methods:** In this study, 24 adult Wistar female rats were divided into 4 separate groups (control group, hydroalcoholic extract of clover 25, 50, and 100 mg/kg intraperitoneally for 25 days). On the last day, tissue samples were evaluated by vaginal smear and Giemsa staining. the left ovary was used for pathological sections and hematoxylin-eosin staining for follicle counting. The right ovary was used to measure Methylenedioxyamphetamine (MDA) levels. Ferric Reducing Ability of Plasma was used to determine the total antioxidant capacity (TAC) of serum.

**Results:** A group receiving 100 mg/kg clover had higher mean ovarian weight, total antioxidant capacity, LH, FSH, Estradiol, and progesterone concentrations, and lower MDA compared to control and some other doses of clover ( $P < 0.05$ ). but, follicles count did not differ among study groups, except for atretic follicles that were significantly lower in the group receiving 100 mg/kg clover in comparison to control ( $P = 0.001$ ).

**Conclusion:** This study shows that clover could significantly justify oxidative stress, inhibiting the breakdown of the ovarian follicles to atretic follicles, and can modify hormonal responses of the rat body in a dose-dependent manner.

**Keywords:** Hydroalcoholic extract of clover, Oxidative stress, Ovarian follicles

Submitted: 3 November 2021, Revised: 7 November 2021, Accepted: 21 December 2021

## Introduction

Today, population growth and infertility treatment are particularly important in developing countries (1), with statistics showing that the infertility problem began in 1990 and in the last two decades the infertility problem in developing countries, especially in The regions of Africa and South Asia are increasing (2, 3). Various factors such as infections, genetics, environment, nutrition and community affect infertility in such a way that these factors can affect a woman or a man or both (2). Antiestrogens such as clomiphene, tamoxifen, and gonadotropins such as FSH and LH have been treated (4, 5). The use of herbal compounds in the treatment of infertility has been considered (6). Among these compounds are phytoestrogens. These compounds, which are structurally and functionally similar to 17-beta estradiol, bind to estrogen receptors in the bloodstream. This binding is less than that of the body androgen. However, these compounds are able to produce estrogenic effects (7-9).

Phytoestrogens include flavonoids, isoflavones, coumestrol, lignans and anthraquinones. Isoflavones have been studied more than other phytoestrogens and have estrogen-like properties in mammals (10). Isoflavones are found in large amounts in clover and its products, as well as in soybeans. Clover isoflavones include genistein, formononetin and biochanin. The role of isoflavones in the control and treatment of cancer, especially endocrine cancers such as

breast cancer, has been identified; But whether they act as anti-estrogens or at the same time contradict it (11, 12). In addition, phytoestrogens can act as antioxidants and protect the body from the damaging effects of free radicals. They also have an anti-proliferative effect on cancer cells and prevent tumor growth. Considering that clover is one of the useful, suitable and available plant compounds and considering its phytoestrogenic and antioxidant potentials, the study of the effect of different doses of its hydroalcoholic extract on the ovarian structure of rats is one of the objectives of this study.

## Methods:

This was an Experimental study that was performed on 24 adult female Wistar rats weighing 250-200 g. The animals were kept in standard conditions of 20-20°C and 12 hours of light and 12 hours of darkness in the boarding house of the faculty. Water and food were provided to the animals during the experimental period without any restrictions. During the experiment, all ethical principles of working with laboratory animals were observed. Mice were weighed before and after the experiment. The duration of the experiment was 25 days, which is equivalent to the completion of 5 sexual cycles (estrus) in rats. Rats were randomly divided into 4 separate groups and 6 heads in each group, which were grouped as follows: Control group: without treatment with extract and standard water and food intake. Experimental group 1:

Hydroalcoholic extract of clover 25 mg / kg intraperitoneally for 25 days. Experimental group 2: Hydroalcoholic extract of clover 50 mg / kg intraperitoneally for 25 days. Experimental group 3: Hydroalcoholic extract of clover 100 mg / kg intraperitoneally 25 days.

To prepare the hydroalcoholic extract of clover, clover was first prepared from the regions of Fars province in April, and after the approval of the Herbarium Center of Kurdistan University, it was dried in a place away from light and turned into a powder. Then 150 g of dry powder with 75% ethanol to a volume of one liter was filtered for 48 hours by immersion method and then centrifuged by 2500 rpm for 20 minutes. Then it was concentrated and dried, then diluted with 0.9% sodium chloride and different doses based on animal weight were calculated for peritoneal injection.

On the last day of the study before extermination, due to the importance of cyclicity of mice during the preparation of tissue samples, the cells were examined by preparing a vaginal smear and Giemsa staining. Four mice were exterminated and sampled with a delay of one or two days for cyclic synchronization. Blood samples were taken from the hearts of mice before extermination (intraperitoneal sodium thiopental injection) and then the serum was isolated by centrifugation at 3000 rpm for 15 minutes to measure antioxidant concentration. Ovary samples were isolated and weighed by digital scales after separating the excess fats and

surrounding tissues. Then the left ovary was immediately immersed in 10% formalin stabilization solution and after fixing for 7 days and performing the usual tissue passage steps and preparing Pathology sections. 5  $\mu$ m sections were prepared and was hematoxylin-eosin stained, and primordial follicles, unilaminar follicles, antral follicles, matured and atretic follicles, multilaminar follicles, and corpus luteums counts were counted by light microscopy. To avoid any counting errors, one follicle was first selected and the other follicles were counted clockwise. This was done in three microscope fields and then averaged.

The right ovary was freshly used to measure the concentration of malondialdehyde 1. Right ovarian tissue was used to determine the amount of malondialdehyde, which is the final product of lipid peroxidation, by thiobarbituric acid method.

Ferric Reducing Ability of Plasma was used to determine TCA of serum.

Concentrations of follicle-stimulating hormones, FSH (lutein), and LH were measured by ELISA. Data were presented as mean and standard deviation. In order to compare the means, ANOVA way-One and Tukey analysis tests were used. Statistical analysis of data was performed using SPSS software program and  $P < 0.05$  was considered significant.

### Results:

Using paired sample t-test there was no significant difference between the

experimental groups (control) and the groups receiving hydroalcoholic extract of clover with doses of 25, 50, and 100 mg/kg in case of body weight. Using ANOVA and LSD post hoc parametric tests, a significant difference was observed between the experimental groups (control) and groups receiving hydroalcoholic extract of clover at doses of 25, 50, and 100 mg/kg. Significantly higher mean ovarian weight was observed in the group receiving 100 mg/kg compared to the control group ( $p = 0.012$ ); while other comparisons were not statistically significant. In the study of Total antioxidant capacity (TAC), a significant increase in the mean concentration of TAC was observed in the group receiving a dose of 100 mg/kg compared to other groups ( $P < 0.05$ ). There was no significant difference between the other groups ( $p > 0.05$ ).

There was a significant decrease in the mean concentration of MDA in the group receiving 100 mg/kg compared to other groups ( $P < 0.05$ ). There was no significant difference between the other groups ( $p > 0.05$ ). The mean LH, FSH, Estradiol, and progesterone concentrations were observed to be higher in the 100 mg/kg group compared to the control group and the 25 mg / kg group. There was no significant difference between the other groups ( $p > 0.05$ ).

Count of primordial follicles, unilaminar follicles, antral follicles, matured, multilaminar follicles, and corpus luteums had no significant differences among study groups ( $p > 0.05$ ). mean count of atretic follicles was significantly

lower in the group receiving a dose of 100 mg/kg compared to control ( $p = 0.001$ ).

### Discussion:

Population growth and infertility treatment are particularly important in developing countries (1), with statistics showing that infertility began in 1990 and in the last two decades' infertility in developing countries, especially in the region. Africa and South Asia are on the rise (2, 3). Ruder et al. (3) investigated oxidative stress and the role of natural plant-derived antioxidants in animal reproduction. Antioxidant therapy plays an important role in preventing diseases caused by oxidative stress. Due to the advantages of low side effects of natural antioxidants over synthetic antioxidants, plants or their extracts have been widely used in animals. Although many advances have been made in the use of plant-derived antioxidants in reducing oxidative stress, there is still debate. Whereas many adverse effects were observed even in the use of plant extracts containing similar active substances in the same animal species; So plant antioxidants, like free radicals, are "double-edged swords" in animal reproduction. They may have beneficial or detrimental effects on animal reproduction. Including spermatogenesis, semen functions, estrous cycles, ovulation, ovarian function, endometrium, fetal growth and pregnancy.

The results of the present study showed that there was no significant difference between the mean body weight before the start of the

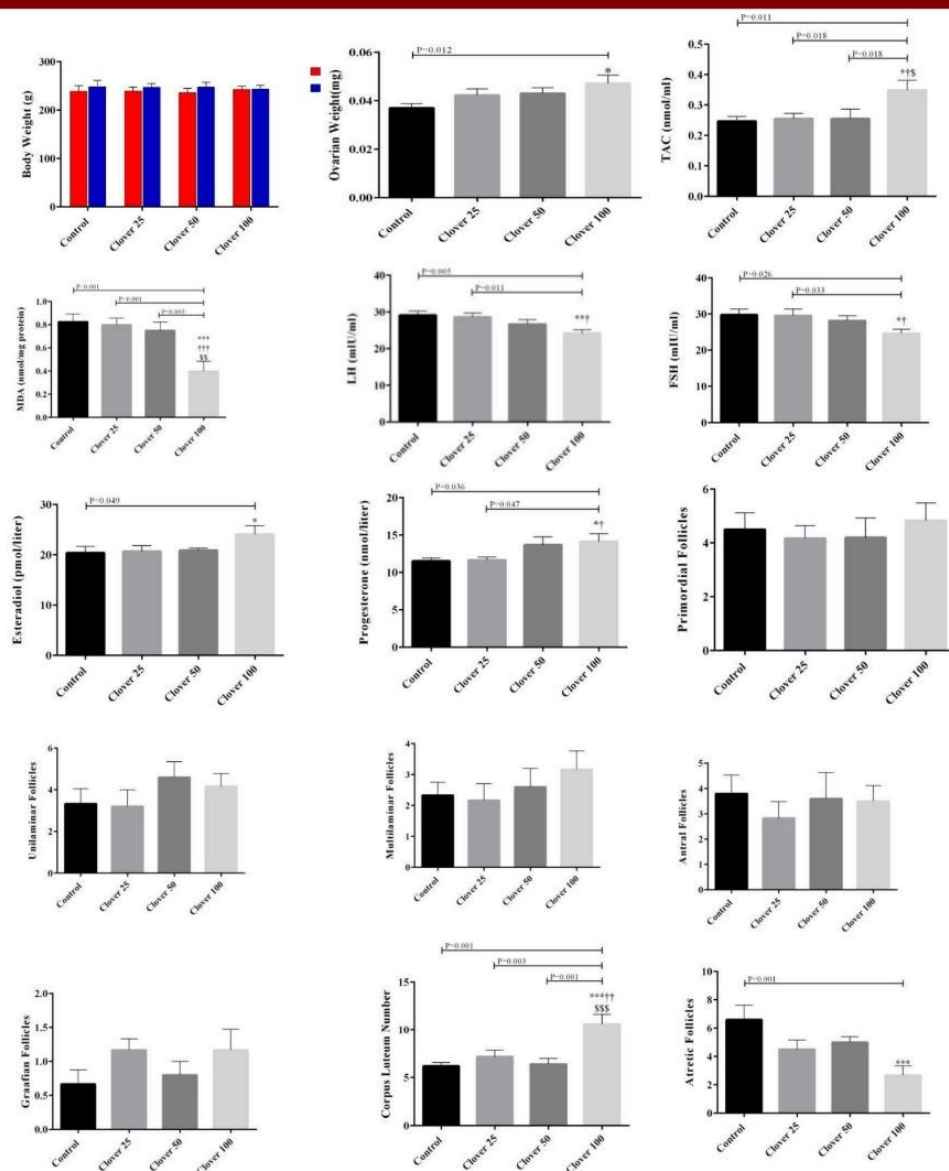


Figure 1. Mean Value Of Study Variables

experiment and at the end of the experiment between the groups. However, a significant increase in mean ovarian weight was observed in the group receiving 100 mg / kg compared to the control group at the level of  $p=0.012$ .

Muhammad (13) showed that Ladino clover phytoestrogens have two types of effects on the uterus of growing female mice. After 1 to 2 weeks of use, it causes an increase in the average weight of the uterus, as well as hypertrophy and hyperplasia, along with stretching of the epithelial lining of the uterine

cavity. The second effect is an inhibitory effect, and if phytoestrogen is continued for 3 to 4 weeks, it will flatten the lumen epithelial lining and destroy the uterine lining. This increase or decrease in uterine weight was not due to water blockage or dehydration and the water content of the limb did not show a significant change between the experimental and control mice. Abbasian et al. (14) showed that plant extracts containing phytoestrogens significantly reduce insulin resistance and ovarian weight, as well as increase ovulation; Therefore, these plants

can be partially effective in this syndrome by affecting the serum levels of various hormones and ovarian weight and morphology.

In another study, Abbasian et al. (15) showed that treatment with red clover reduced ovarian weight, ovarian volume and number of cysts, and increased the number of eggs. Kim et al. (16) showed that the combined effect of red clover and hops extract (RHEC) significantly prevents body weight gain and fat loss. On the other hand, Parandin et al. (17), in the study of the effects of formononetin from red clover during pregnancy, decreased ovarian weight and decreased corpus luteum in group 500 ( $p < 0.05$ ) and increased uterine weight ( $p < 0.05$ ) in groups 50 and 500. In another study by Abbasian et al. (18) showed that the total volume of ovaries in the red clover extract group was significantly reduced compared to the PCO model ( $p < 0.001$ ). Ovarian volume in treatment groups was significantly reduced compared to PCO model ( $p < 0.01$ ). These results may be due to hormonal imbalance in the present study. Evidence has shown that ovarian weight and corpus luteum depend on gonadotropin levels, especially LH and metabolism, and uterine weight and growth depend on estradiol (19, 20). LH and estradiol increase is consistent in the present study.

Also, the present study showed a significant decrease in the mean concentration of LH, FSH in the group receiving 100 mg/kg compared to the control group and the group receiving 25 mg/kg; However, a significant increase in the

mean concentrations of estradiol and progesterone was observed in the group receiving 100 mg/kg compared to the control group and the group receiving 25 mg/kg. Abdolghani et al. (21) showed hormone-treated mice with continuous digestion as well as ovaries containing cystic follicles. When treated with TAF 273, fewer animals showed irregular estrous cycles and less follicular morphological damage. The opposite effect may be due to the anti-estrogenic properties of plant coasinoids. Trisunuwati in 2017 showed that the effects of water clover on the histological characteristics of the uterus in the control group showed thicker endometrial coverage than in the control group. Histology of the uterus Endometrial thickening was also seen in the treatment groups (22). Bordet et al. (23) showed that red clover caused a dose-dependent increase in uterine weight and differentiation of vaginal cells at doses of 500 and 750 mg / (kg · d); But it did not stimulate cell proliferation in the mammary glands. Anti-estrogenic and estrogenic additive properties were not observed in any of the studied tissues

In the study of Parandin et al. (17), increasing the concentration of estradiol in groups 50 ( $p < 0.05$ ) and 500 ( $p < 0.001$ ) of formononetin and decreasing the concentration of LH and decreasing lordosis factor in group 500 (0.001)  $P < 0$  was observed in comparison with the control group. Abbasian et al. (14) showed that red clover extract and clomiphene citrate reduced testosterone levels and



significantly increased estradiol levels compared with the polycystic ovary group ( $p < 0.05$ ). Abbasian et al. (18) showed that red clover extract can reduce the volume and size of polycystic ovaries by balancing the serum levels of sex hormones. Clover has active medicinal compounds such as flavonoids that have cellular activities such as antioxidants and estrogenic activity.

In the present study, a significant increase in mean TAC concentration and a significant decrease in mean MDA concentration was observed in the group receiving 100 mg/kg compared to other groups. Kim et al. (16) showed that red clover and hops extract (RHEC) in menopausal symptoms, such as blood lipid profile (total cholesterol and lipoprotein cholesterol), bone metabolism (serum alkaline phosphatase, osteocalcin and telopeptide c type 1), Superoxide dismutase and malondialdehyde) and vasodilators (endothelin-1 and nitric oxide) improved significantly after RHEC administration; Also, Abbasian et al. (14) showed that red clover restored GSH, SOD and CAT levels ( $p < 0.05$ ) and reduced NO and MDA levels ( $p < 0.05$ ). The treatments did not significantly change the level of TG, TC and FBG factors ( $P > 0.05$ ).

The results of the present study showed that the number of primary, monolayer, multilayer, antral follicles and the number of mature follicles were not significantly different between the groups. However, a significant increase in the number of corpus luteum and a

significant decrease in the number of atretic follicles were observed in the group receiving 100 mg / kg compared to the control group at the level of  $p = 0.001$ . Parandin et al. (17) reported a significant decrease in the number of corpus luteum in the 500 group ( $p < 0.05$ ). Widhaningrum et al. (24) showed a significant increase in the mean diameter of antral follicles and egg diameter at a concentration of 43.2 WCE  $\mu\text{g ml}^{-1}$  compared to other groups ( $P \leq 0.05$ ). According to the results, the effect of ethanol clover extract after six days of culture has its effect on the growth of antral follicles and oocytes based on follicle and oocyte diameter in a dose-dependent manner, respectively. In another 2017 Triswonati study, the histological features of the uterus in the control group showed thicker endometrial lining than in the control group. Histology of the uterus Endometrial thickening was also seen in the treatment groups.

### Conclusion:

Clover can considerably reduce oxidative stress by slowing the degradation of ovarian follicles into atretic follicles and can affect hormonal responses in the rat body in a dose-dependent way, according to this study.

### References:

1. Aflatoonian A, Seyedhassani SM, Tabibnejad N. The epidemiological and etiological aspects of Infertility in Yazd province of Iran. *Jnt J Reprod Bio Med*. 2009 Summer;7(3):117-122.
2. Duleba AJ. Medical management of metabolic dysfunction in pcos. *Steroids* 2012; 77(4): 306-11.

3. Ruder EH, Hartman TJ, Blumberg J & Goldman M. Oxidative stress and antioxidants: Exposure and impact on female fertility. *Hum Reprod Update* 2008; 14(4): 345-57.
4. Liu J, Liu M, Ye X, Liu K, Huang J, Wang L, et al. Delay in oocyte aging in mice by the antioxidant n-acetyl-l-cysteine (nac). *Human Reproduction* 2012; 27(5): 1411-20.
5. Herbison AE. Physiology of the gonadotropin-releasing hormone neuronal network. In: Neill JD, Plant TM, editors. *Knobil and Neil's Physiology of Reproduction*, 3rd ed. NewYork: Raven Press, 2006:1415–1482.
6. Ahmad N, Rahman Z, Akhtar N et al. Effect of madicago sativa on some serum biochemical metabolites in rats. *Int J AgricBiol*. 2013; 15(2):297-300
7. Monsefi, M., Masoudi, M., Hosseini, E., Gramifar, F., and Miri, R., 2012. Anti-fertility effects of different fractions of *Anethum graveolens* L. extracts on female rats. *African Journal Traditional, Complementary, and Alternative Medicine*, 9(3), PP:336-341
8. Ososki, A.L., and Kennelly, E.J., 2003. Phytoestrogens: a review of the present state of research. *Phytotherapy Research*, 17, PP: 845-869.
9. Zhao, E., and Qing, M.U., 2010. Phytoestrogen Biological Actions on Mammalian Reproductive System and Cancer Growth. *Scientia Pharmaceutica*, 79(1), PP: 1-20.
10. Tundis R, Marrelli M, Conforti F, Tenuta M, Bonesi M, Menichini F, Loizzo M. *Trifolium pratense* and *T. repens* (Leguminosae): Edible flower extracts as functional ingredients. *Foods*. 2015 ;4(3):338-48.
11. Schütz K, Carle R, Schieber A. *Taraxacum*—a review on its phytochemical and pharmacological profile. *Journal of ethnopharmacology*. 2006;107(3): 313-23.
12. Azad Bakht M. Phytoestrogens. *Journal of Medical Plants*. 2006; 6(21):1–10
13. Muhammad N, Saeed M, Khan H. Antipyretic, analgesic and antiinflammatory activity of *Viola betonicifolia* whole plant. *BMC complementary and alternative medicine*. 2012 ;12(1):59.
14. Abasian, Z., Rostamzadeh, A., Mohammadi, M., Hosseini, M., & Rafieian-Kopaei, M. (2018). A review on role of medicinal plants in polycystic ovarian syndrome: Pathophysiology, neuroendocrine signaling, therapeutic status and future prospects. *Middle East Fertility Society Journal*, 23(4), 255-262.
15. Abbasian, Z., Barmak, M. J., Barazesh, F., Ghavamizadeh, M., & Mirzaei, A. (2020). Therapeutic efficacy of *Trifolium pratense* L. on letrozole induced polycystic ovary syndrome in rats. *Plant Science Today*, 7(3), 501-507.
16. Kim, M. R., Kim, H. J., Yu, S. H., Lee, B. S., Jeon, S. Y., Lee, J. J., & Lee, Y. C. (2020). Combination of red clover and hops extract improved menopause symptoms in an ovariectomized rat model. *Evidence-Based Complementary and Alternative Medicine*, 2020.
17. Parandin, R., & Mohammadi, L. (2019). The effects of Formononetin Derived from Red Clover During Pregnancy on Puberty, Some Reproductive Parameters and Lordosis Behavior of Female Mice. *Armaghane danesh*, 24(2), 199-213.
18. ABBASIAN Z, GHANBARI A. HYDROALCOHOLIC EXTRACT OF RED CLOVER (*TRIFOLIUM PRETENSE*) IMPROVES HORMONAL BALANCES AFTER INDUCTION OF POLYCYSTIC OVARY SYNDROME IN RATS.
19. Kim, H. S., Shin, J. H., Moon, H. J., Kim, T. S., Kang, I. H., Seok, J. H., ... & Han, S. Y. (2002). Evaluation of the 20-day pubertal female assay in Sprague-Dawley rats treated with DES, tamoxifen, testosterone, and flutamide. *Toxicological Sciences*, 67(1), 52-62.



- 
20. Chattopadhyay, S., Pal, S., Ghosh, D., & Debnath, J. (2003). Effect of dietary co-administration of sodium selenite on sodium arsenite-induced ovarian and uterine disorders in mature albino rats. *Toxicological Sciences*, 75(2), 412-422.
  21. Abdulghani, M., Hussin, A. H., Sulaiman, S. A., & Chan, K. L. (2012). The ameliorative effects of *Eurycoma longifolia* Jack on testosterone-induced reproductive disorders in female rats. *Reproductive biology*, 12(2), 247-255.
  22. Trisunuwati, P. (2017). The role of leaf water clover (*Marsilia Crenata*) squeeze towards estrogen blood level and uterine histology in rats (*Rattus norvegicus*). *TERNAK TROPIKA Journal of Tropical Animal Production*, 17(2), 1-7.
  23. Burdette, J. E., Liu, J., Lantvit, D., Lim, E., Booth, N., Bhat, K. P., ... & Bolton, J. L. (2002). *Trifolium pratense* (red clover) exhibits estrogenic effects in vivo in ovariectomized Sprague-Dawley rats. *The Journal of nutrition*, 132(1), 27-30.
  24. Widhaningrum, S. N., Rahayu, S., & Ciptadi, G. (2021). Effect of Water Clover (*Marsilea crenata*) Ethanol Extracts on Follicle and Oocyte Diameter of Goat: In Vitro Study. *The Journal of Experimental Life Science*, 10(2), 113-118.