

**Original Research** ↑**Successful Treatment of *Trichosporon asahii* Infection with Combination Therapy of Voriconazole and Liposomal Amphotericin B in a Child with Acute Lymphoblastic Leukemia: A Case Report**Maha Jassim Bourusly<sup>1</sup>, Mohammed Adel Obaid<sup>2</sup>, Muna Burahma<sup>3</sup>

1. Department of Hematology, Oncology and Stem Cells Transplant, NBK Children's Specialty Hospital, MOH. Kuwait.
2. Department of Hematology, Oncology and Stem Cells Transplant, NBK Children's Specialty Hospital, MOH. Kuwait.
3. Department of Hematology, Oncology and Stem Cells Transplant, NBK Children's Specialty Hospital, MOH. Kuwait.

**\*Corresponding Author: Maha Jassim Bourusly**, Department of Hematology, Oncology and Stem Cells Transplant, NBK Children's Specialty Hospital, MOH. Kuwait. Telephone No.: 0096599400120. E-mail: mboursuly@moh.gov.kw. ORCID ID: <https://orcid.org/0000-0002-7390-1235>

**Abstract:****Background:**

*Trichosporon* species (particularly *T. asahii*) is regarded as one of the prevalent fungal species responsible for causing invasive fungal infection in patients with hematological malignancies and/or immunocompromised patients. Trichosporonosis can often be life-threatening; therefore, an early diagnosis followed by prompt treatment is crucial for the patient's survival. However, an ideal antifungal treatment for *T. asahii* infection is not yet established.

**Case Presentation:**

This report presented a case of *T. asahii* fungemia in a male child of age 5-year 5 months with acute lymphoblastic leukemia. The patient developed febrile neutropenia towards the end of induction chemotherapy, and his blood culture indicated the presence of *T. asahii* and *E. coli*. He was treated with broad-spectrum antibiotics and antifungal monotherapy (either liposomal amphotericin B or voriconazole) without an effective outcome. Subsequently, the patient further underwent combination therapy with voriconazole and liposomal amphotericin B.

**Conclusion:**

Combination therapy with voriconazole and liposomal amphotericin B was found to improve the condition of the patient. He is currently reported to be fine while undergoing maintenance chemotherapy along with voriconazole monotherapy.

**Keywords:** Amphotericin B, Antifungal Agents, Chemotherapy, Febrile Neutropenia, *T. asahii*, voriconazole.

Submitted: 4 April 2022, Revised: 19 May 2022, Accepted: 14 June 2022

## Introduction

*Trichosporon* species is an emerging, fatal, opportunistic pathogen found to be responsible for both superficial and invasive fungal infection (IFI) (1, 2), particularly among patients with hematological malignancies and immunocompromised patients (1, 3, 4). Invasive trichosporonosis can be subdivided into localized and disseminated forms, the latter being more prevalent; usually presented with acute fever, skin lesions, pulmonary infiltrates, and subsequent multi-organ failure (5, 6). Among *Trichosporon* species, *T. asahii* infection has been reported to be one of the common systemic fungal infections (4, 7-10) prevalent among neutropenic adults, cancer patients, and recipients of hematopoietic stem cell transplant (9, 10). Disseminated *T. asahii* infection is claimed to be rare among the pediatric population (5, 8); however, few cases of *T. asahii* infection have been reported among children suffering from hematologic malignancies and undergoing immunosuppressive therapy (cytotoxic chemotherapy) (2, 5-8, 11, 12). Treatment of disseminated trichosporonosis is a major challenge due to delay in diagnosis and multi-drug resistance (6). Moreover, treatment outcome is found to be poor, with an estimated mortality rate of 77-80% (1, 7). Therefore, an early diagnosis followed by quick implementation of therapy with an appropriate antifungal agent can diminish the mortality rate among critically ill patients (8, 10). An ideal antifungal agent for treating *T. asahii* infection has not yet been established. However, several *in vitro* studies have exhibited promising benefits of voriconazole (a second-generation triazole) as first-line antifungal therapy (1, 3, 4, 12).

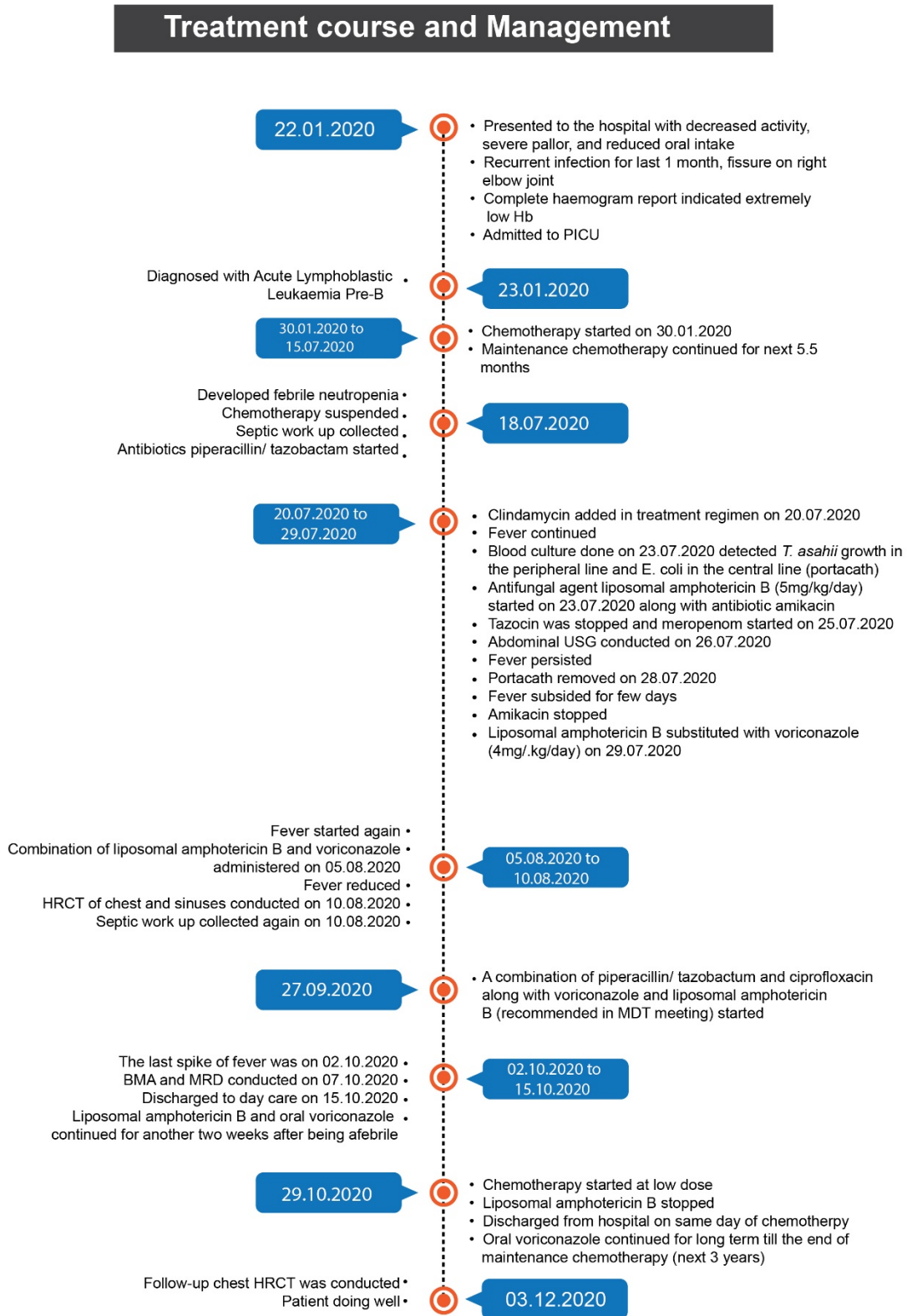
With the changing fungal landscape in the Middle East (ME), IFIs have been found to contribute a significant burden to the healthcare system. Challenges associated with IFI include suboptimal application of rapid diagnostic tests

and antifungal therapy, which might be responsible for an increased mortality rate and prolonged hospitalization of patients in the ME (13). Here, we reported a case of *T. asahii* fungemia in a pediatric patient with acute lymphoblastic leukemia (ALL), who was successfully treated with combination therapy of voriconazole and liposomal amphotericin B.

## Case Presentation

A 5 year-5-month-old male child, previously healthy, was admitted to NBK Children's Cancer hospital on 22<sup>nd</sup> January 2020 with decreased activity, reduced oral intake, severe pallor, and recurrent infection for one month, along with a fissure in his right elbow joint. His complete hemogram report indicated a low hemoglobin (Hb) level of 2.5 g/L. He was immediately hospitalized in the pediatric intensive care unit (PICU) to avoid the chances of impending heart failure and to undergo urgent blood transfusion and further investigations. The patient's complete blood count (CBC) report showed white blood cell (WBC) count as  $7.6 \times 10^9/L$  and 55% of blast cells in the blood film. Based on the clinical diagnosis and investigations, the patient was diagnosed with ALL-Pre-B with cerebrospinal fluid (CSF) negative of blast cells on the first day of hospitalization. The timeline of key events for this case is depicted in Figure 1. Chemotherapy was initiated as per UK-MRC-ALL 2011 regimen A protocol (standard risk) on 30<sup>th</sup> January 2020. At the end of induction, the patient was in remission, and minimal residual disease (MRD) was detected low. Hence, chemotherapy was continued on the same protocol, and his scheduled consolidation and interim maintenance courses were completed uneventfully in approximately the next five and half months. However, at the end of delayed intensification, three days after receiving scheduled chemotherapy treatment, the patient developed febrile neutropenia along with cellulitis of the right big toe, anal fissure, and small lower lip aphthous ulcer on 18<sup>th</sup> July 2020. Therefore, chemotherapy was suspended on the same day, and clinical investigations

were conducted to analyze the underlying cause of the conditions (Figure 1).

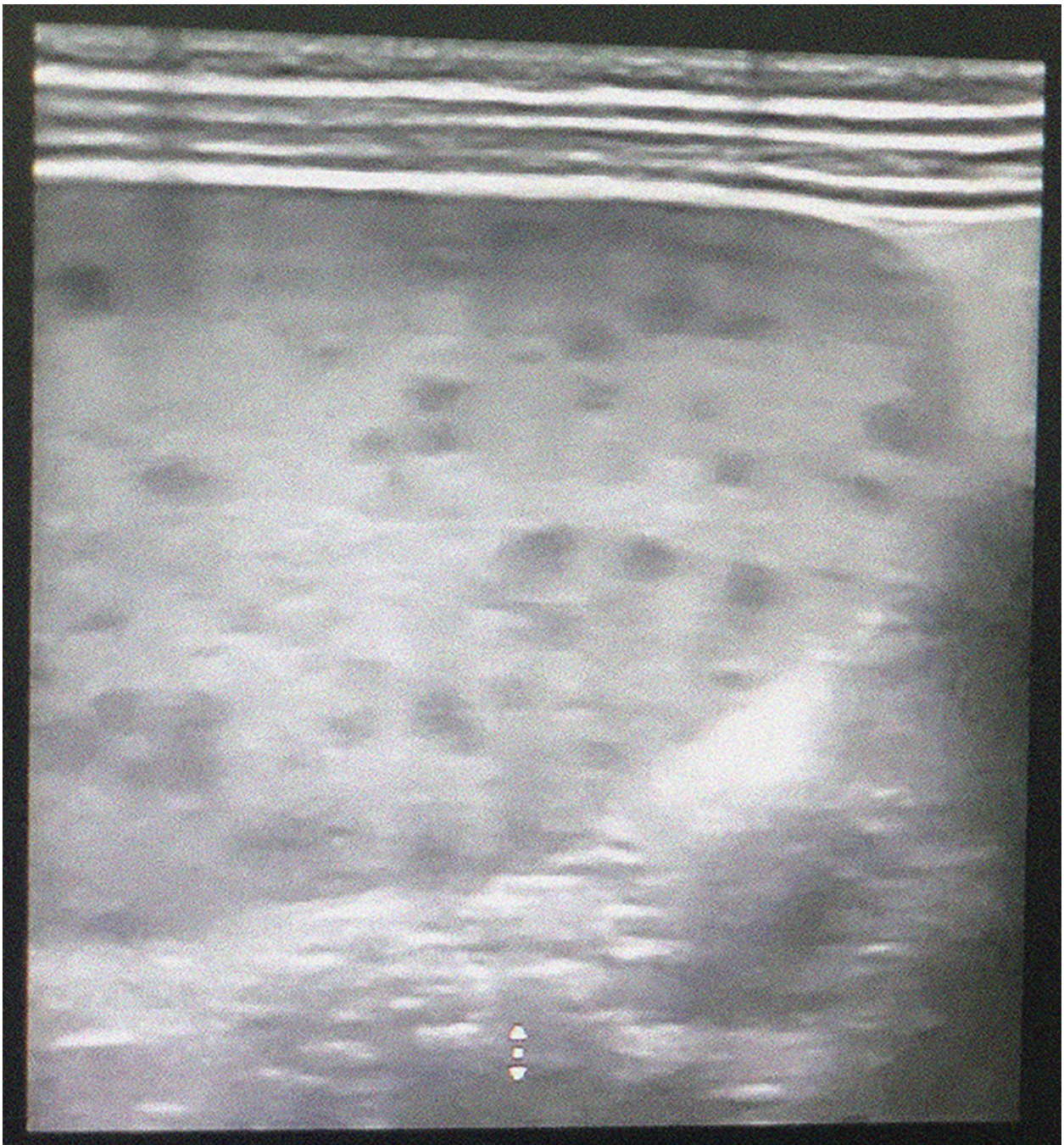


**Figure 1: Timeline of the key events of this case report**

Abbreviations: BMA: Bone marrow aspiration, Hb: Hemoglobin, HRCT: High resolution computed tomography, MDT: Multidisciplinary team, MRD: Minimal residual disease, PICU: Pediatric intensive care unit, USG: Ultrasonography

On the first day (day 1) of the development of febrile neutropenia, a septic workup was collected, followed by a blood culture on day 6. The culture report revealed the growth of *E. coli* in the central line (portacath) and *T. asahii* in the peripheral line. Abdominal ultrasonography (USG) was conducted, followed by high-resolution computed tomography (HRCT) of chest and sinuses and repeat septic workup. In addition, bronchoalveolar lavage (BAL) was performed on day

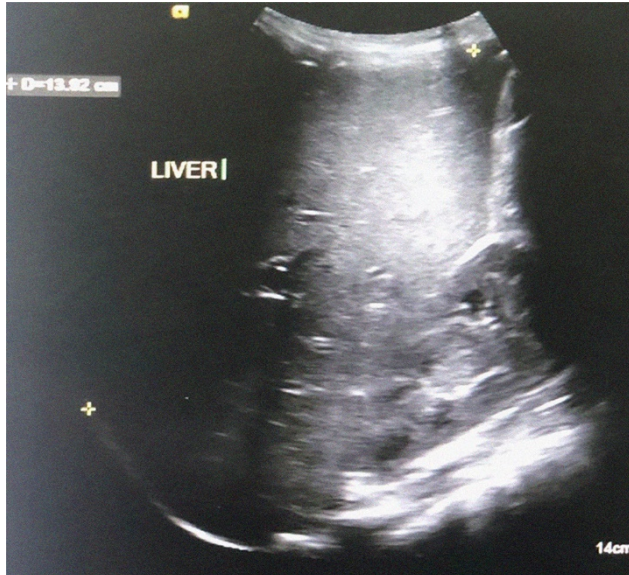50, and samples were sent for fungal and bacterial cultures (like *Pneumocystis jirovecii*, acid-fast bacillus for atypical mycobacteria), virology, and malignancy tests. Furthermore, a liver biopsy from the largest hypoechoic lesion was performed and sent for bacterial and fungal cultures, tuberculosis analysis, and histopathology; repeat blood cultures and galactomannan assay were also conducted for further investigations.



**Figure 2: Hepatosplenomegaly with innumerable focal lesions.**

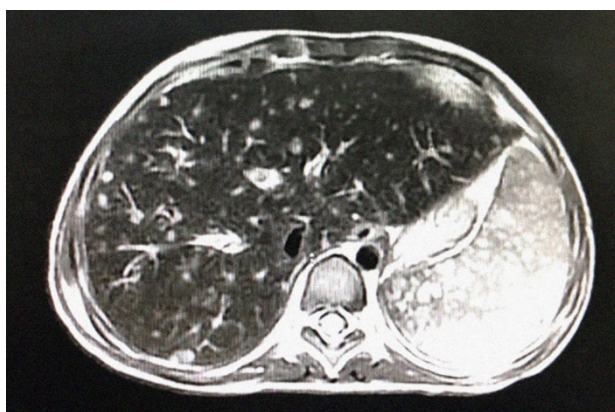
Most of the lesions are sub-centimetric, the largest reaching about a maximum length of 10 mm, presence of smooth hepatic borders.

The abdominal USG of the patient revealed multiple hypoechoic lesions in the liver, spleen, and kidneys (Figures 2, 3, and 4).



**Figure 3: Ultrasonography of abdomen showed hepatosplenomegaly with innumerable focal lesions.**

Most lesions are sub-centimetric, largest reaching about 10 mm in length, otherwise smooth hepatic borders, and no intrahepatic biliary radicle dilatation observed. Additionally, enlarged kidneys with parenchymal changes as well as scattered tiny focal lesions were seen.



**Figure 4: MRI of the abdomen showed an enlarged spleen.**

Spleen was studded with innumerable tiny focal lesions (average size 0.5X0.7 mm); most of these nodules exhibited hyperintense signal at T2 WI but faintly hyperintense signals at T1WI. The liver was

mildly enlarged with diffusely scattered, minutely altered signal intensity or focal lesions (average size around 0.5 cm) with nearly the same signal intensity as splenic lesions, some are peripheral sub-capsular, and all showed diffusion restriction.

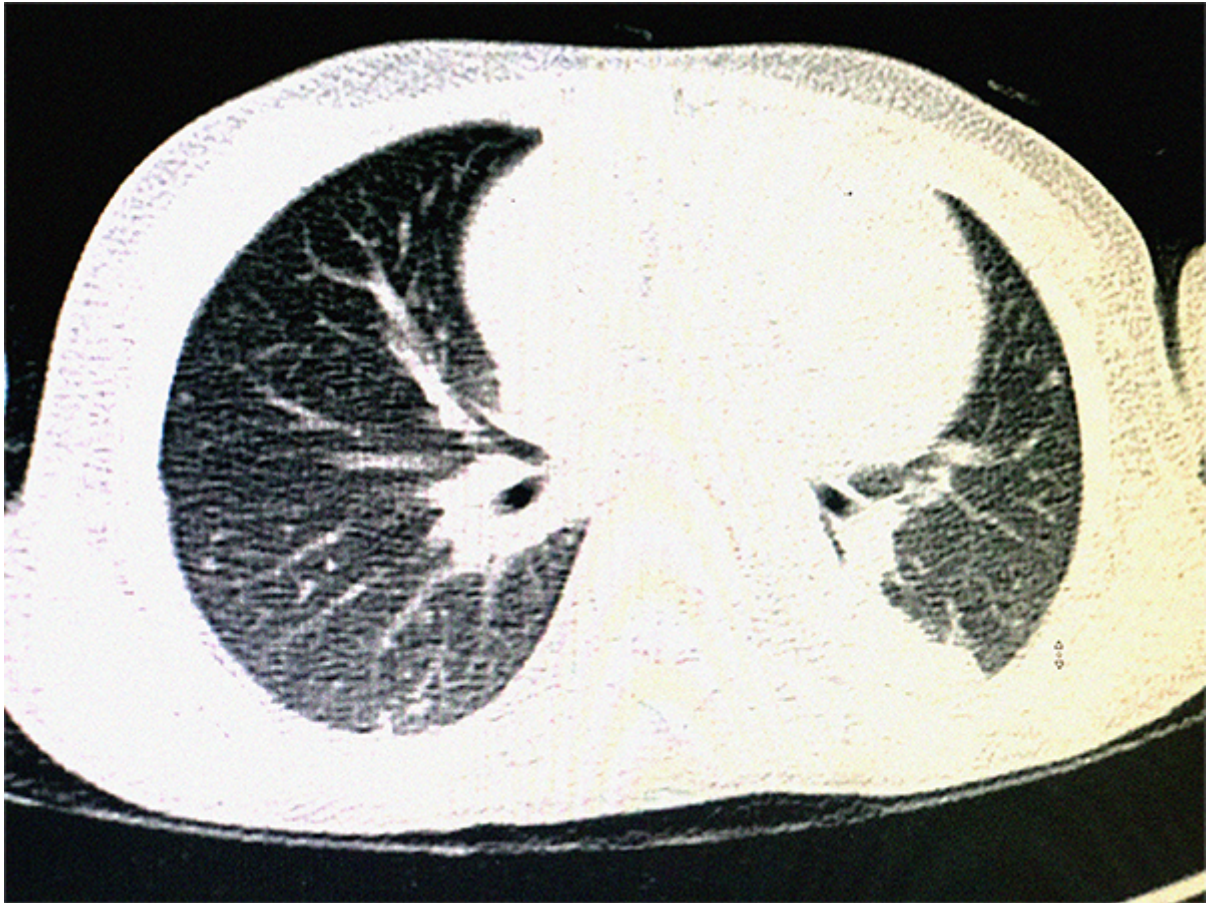
Abbreviations: MRI: Magnetic resonance imaging, T2WI: T2 weighted image, T1WI: T1 weighted image

Computed tomography (CT) scans of the chest and sinuses indicated the presence of bilaterally scattered pulmonary nodules (Figure 5). However, BAL test reports were negative, the galactomannan was repeatedly negative, the reports of liver biopsy and cultures were inconclusive, and the repeat blood cultures were found to be negative on five different occasions. The blood culture report and the combined diagnostic reports (USG and CT scans) confirmed the presence of *T. asahii* fungemia in the patient (Figure2-5).

The patient was treated with broad-spectrum antibiotics, such as piperacillin/ tazobactam (as per the febrile neutropenia protocol) on day 1 of febrile neutropenia clindamycin was also introduced in the treatment regime after two days; however, the fever didn't subside. Based on the first blood culture report (on day 6), he was further treated with amikacin and liposomal amphotericin B (5mg/kg/day), and after two days, tazocin was stopped, and meropenem was initiated. Since fever continued, the portacath was removed on day 11 of fever. Subsequently, the fever subsided for a few days, and amikacin was withdrawn. At the same time, liposomal amphotericin B was substituted with voriconazole (4mg/kg/day) since voriconazole revealed the lowest minimum inhibitory concentrations (MICs) among other antifungal agents (MIC-microgram/ml- voriconazole- 0.032, amphotericin B- 0.5, caspofungin- resistant).

Nonetheless, the patient again developed fever and received a combination of voriconazole and liposomal amphotericin B on day 19. Since

his fever was not subsiding, the voriconazole trough level was measured, and the dose was escalated from 4 mg/ kg/day to 8 mg/ kg/day.

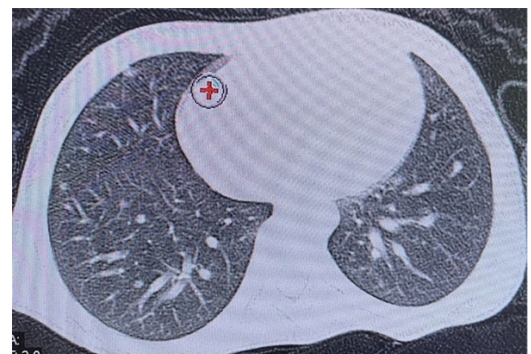


**Figure 5: CT scan of the chest without contrast.**

Patches of consolidation in the posterior right and left lower lobes along with multiple bilaterally scattered small sub-pleural pulmonary nodules of ground-glass attenuation were seen.

Abbreviations: CT: Computed tomography

On day 72, meropenem was substituted with piperacillin/tazobactam. This case was further discussed in a multidisciplinary team meeting (MDT). As per the meeting's decision, the patient was recommended to continue the combination of antifungal drugs (liposomal amphotericin B and voriconazole) along with an antibiotic (ciprofloxacin). The patient's last spike of fever was observed on day 77.



**Figure 6: Follow-up chest CT scan image.** Reduced number and size of the previously noted sub-centimetric pulmonary nodules were observed. In addition, some of the nodules showed decreased attenuation density, and some showed ground-glass

attenuation. Red (+) indicates minimal peripheral fluid collection.

Abbreviations: CT: Computed tomography

Bone marrow aspirates (BMA) and MRD performed on day 82 indicated the patient was in remission. On 15th October 2020 (day 90), he was discharged to daycare after being afebrile.

Despite being afebrile, the patient continued to receive a combination therapy of liposomal amphotericin B and oral voriconazole for the next 14 days. Further, his chemotherapy was reinitiated at a low dose, followed by gradual dose escalation to avoid neutropenia. He was performing well after receiving chemotherapy and was discharged from the hospital on the same day. Liposomal amphotericin B was then discontinued, and only voriconazole monotherapy was continued. The patient's future treatment strategy included continuing maintenance chemotherapy for the next three years and voriconazole. Furthermore, follow-up HRCT of the chest revealed a regressive course of fungal infection in terms of decreased number, diminished size, and attenuation of pulmonary nodules (Figure 6). Currently, the patient is doing well with no reported episode of fungal infection.

## Discussion

Invasive fungal infection has been regarded as one of the leading causes of morbidity and mortality in patients with hematological malignancies (especially leukemia) (14, 15). A drastic increase in the incidence of IFI has been reported in patients with acute leukemia (16). Cytotoxic chemotherapy in malignant patients results in severe neutropenia and mucosal barrier damage, leading to increased chances of bloodstream infections (17, 18). In cancer patients, *Trichosporon* species are found to be the second most prevalent yeast species (after *Candida*) responsible for fungal infection (11). *Trichosporon* species is a ubiquitous,

opportunistic fungus that typically colonizes the normal flora of the skin, respiratory and gastrointestinal (GI) tracts (2, 11). *T. asahii* has been reported to have an elevated infection incidence in the last two decades (9). Predisposing risk factors for *T. asahii* infection include hematologic malignancies, neutropenia, usage of broad-spectrum antibiotics, corticosteroids, and invasive medical devices (such as central venous catheters [CVCs]), organ transplantation, peritoneal dialysis, and long-term ICU hospitalization (1, 9, 11, 19). The present case described a pediatric patient diagnosed with ALL, who developed severe febrile neutropenia during his chemotherapy and was immediately treated with broad-spectrum antibiotics. The patient's blood culture, chest radiograph, and abdominal USG report confirmed *T. asahii* fungemia.

*T. asahii* can be isolated from the cultures of blood, urine, sputum, CSF, and even postmortem tissue. However, it is usually difficult to confirm this infection during the initial stage. Therefore, early detection followed by immediate intervention can be beneficial in reducing this infection-mediated mortality (5, 11). Conventional culture and histology-based methods are usually considered less sensitive during the initial stage of infection when the fungal load is low (5, 20). Moreover, the presentation of non-specific symptoms is regarded as an additional challenge for early definitive diagnosis (20). Common manifestations of *T. asahii* infection include cutaneous involvement with papulonodular lesions, pulmonary involvement with respiratory symptoms, alveolar and interstitial infiltrates appearing in chest radiographs (5, 8). Besides, hepatic and splenic abscesses have also been reported infrequently (8, 21). In our case, CT images of the chest revealed faint consolidations in the lungs that developed into tiny nodules, which further increased in size with the progression of time,

indicating pulmonary involvement. Additionally, multiple hyperintense lesions were observed in the spleen, liver, and kidneys (abdominal USG). These findings were indicative of an invasive *T. asahii* infection in the patient and are in agreement with other previously reported similar cases (2, 8).

Specified treatment guidelines for managing invasive *T. asahii* infections are currently unavailable (4, 22). Recent studies revealed that *T. asahii* exhibits low sensitivity towards common antifungal agents *in vitro* and in most immunocompromised patients (1, 22). The occurrence of breakthrough trichosporonosis was found even during treatment with various antifungal agents. Moreover, the efficacy of the antifungal drugs may vary between *in vivo* and *in vitro* studies (8, 21). *Trichosporon* species are found to be resistant to flucytosine or echinocandins with varied susceptibilities *in vitro*, whereas sensitivity towards amphotericin B is reported to be limited or inconsistent *in vivo* (1, 4, 22). Although amphotericin B has been reported to exhibit positive efficacy towards *Trichosporon* species *in vitro*, it has been found to be ineffective in patients with breakthrough infections, especially with severe neutropenia. Furthermore, echinocandins are found to be ineffective in treating trichosporonosis (5). The joint guidelines published by the European Society of Clinical Microbiology and Infectious Diseases and the European Confederation of Medical Mycology in 2014 recommended triazoles as superior to other antifungal agents in prophylaxis and treatment. Further, voriconazole is claimed to be the preferred drug as it exhibited high efficacy both *in vitro* and *in vivo* against *Trichosporon* species (19, 23) and was also found to be a sensitive drug against *T. asahii* -mediated breakthrough infections (1). The probable treatment options for *T. asahii* infection include voriconazole (first-line therapy), fluconazole, amphotericin B, and itraconazole (9).

With the recent trend of increasing incidence of *T. asahii* mediated infection and the development of newer antifungal drugs, the antifungal combination therapy (ACT) is currently gaining more attention to achieve better clinical outcomes and antifungal drug doses reduction (1). Furthermore, several clinical studies have also claimed ACT is more effective compared to monotherapy (24). Clinical efficacy of voriconazole monotherapy or combination therapy with amphotericin B has been reported and also recommended as a prolonged treatment for trichosporonosis (5, 6).

The successful management of *T. asahii* infection might depend on various factors like early diagnosis, effective therapy with antifungal drugs, neutrophil count recovery, the immunological status, and dose adjustments of immunosuppressants combined with azole therapy (6, 10). Moreover, recovered patients (especially those receiving immunosuppressive treatment) are recommended to undergo a chronic antifungal suppressive therapy (with oral voriconazole) to avoid chances of late relapses of fungal infection (5). In the present report, the patient developed febrile neutropenia during maintenance chemotherapy, and a blood culture detected the presence of *T. asahii* in the peripheral line. Initially, the patient received monotherapy with liposomal amphotericin B; however, the fever didn't subside. Therefore, he was switched to voriconazole monotherapy, but no remission of fever was observed. To achieve a better clinical outcome, he was then treated with an ACT of voriconazole and amphotericin B for a few weeks, which resulted in the abatement of fever. Subsequently, he was subjected to prolonged voriconazole monotherapy with concomitant chemotherapy. Further, the patient is recommended to continue with voriconazole during his maintenance chemotherapy for the next three years.

## Conclusion

This case report indicated a successful treatment outcome of *T. asahii* fungemia with an ACT of voriconazole and amphotericin B in a pediatric ALL patient. Early diagnosis of *T. asahii* followed by appropriate antifungal therapy and a prolonged maintenance dose of voriconazole are considered responsible for this positive therapeutic outcome. However, future studies involving a large number of pediatric ALL patient population with *T. asahii* fungemia can warrant more clarity on the benefit of ACT (voriconazole + amphotericin B) in these patients.

## Ethical Approval

Informed consent was obtained from the patient to publish this report.

## Contributors

MJB conceived the manuscript and is responsible for obtaining patient consent. MB and MO contributed to data acquisition, confirmation of results, and setting the timeline of illness and dates of each antibiotic. All authors were responsible for interpreting data critically reviewing and revising the manuscript for important intellectual content.

## Acknowledgments

Medical writing, editing, and publication support were provided by TuracoZ Healthcare Solutions (www.turacoZ.com).

## Conflict of Interest Declaration

None declared

## References

- 1.Chen J, Chen F, Wang Y, Yang LY, Miao M, Han Y, Wu DP. Use of combination therapy to successfully treat breakthrough *Trichosporon asahii* infection in an acute

leukemia patient receiving voriconazole. *Med Mycol Case Rep.* 2014;6:55-7.

- 2.Foster CE, Edwards MS, Brackett J, Schady DA, Healy CM, Baker CJ. *Trichosporonosis in Pediatric Patients With a Hematologic Disorder.* *J Pediatric Infect Dis Soc.* 2018;7(3):199-204.
- 3.Antachopoulos C, Papakonstantinou E, Dotis J, Bibashi E, Tamiolaki M, Kolioukas D, Roilides E. *Fungemia due to Trichosporon asahii in a neutropenic child refractory to amphotericin B: clearance with voriconazole.* *J Pediatr Hematol Oncol.* 2005;27(5):283-5.
- 4.Feugray G, Krzisch D, Dehais M, Razakandrainibe R, Gargala G, Favennec L, Lepretre S, Camus V, Costa D. *Successful treatment of Trichosporon asahii fungemia with isavuconazole in a patient with hematologic malignancies.* *Infect Drug Resist.* 2019;12:2015-8.
- 5.Maxfield L, Matthews JJ, Ambrosetti DR, Ephtimios IE. *Trichosporon fungemia in a pediatric patient with acute lymphoblastic leukemia.* *IDCases.* 2015;2(4):106-8.
- 6.Nguyen JK, Schlichte MJ, Schady D, Pourciau CY. *Fatal disseminated Trichosporon asahii fungemia in a child with acute lymphoblastic leukemia and a morbilliform eruption.* *Pediatr Dermatol.* 2018;35(1):e86-e7.
- 7.Kudo K, Terui K, Sasaki S, Kamio T, Sato T, Ito E. *Voriconazole for both successful treatment of disseminated Trichosporon asahii infection and subsequent cord blood transplantation in an infant with acute myelogenous leukemia.* *Bone Marrow Transplant.* 2011;46(2):310-1.
- 8.Thibeault R, Champagne M, de Repentigny L, Fournet JC, Tapiero B, Moghrabi A, Ovetckine P. *Fatal disseminated Trichosporon asahii infection in a child with acute lymphoblastic leukemia.* *Can J Infect Dis Med Microbiol.* 2008;19(2):203-5.

9. Li H, Guo M, Wang C, Li Y, Fernandez AM, Ferraro TN, Yang R, Chen Y. Epidemiological study of *Trichosporon asahii* infections over the past 23 years. *Epidemiol Infect.* 2020;148:e169.
10. Sah R, Soin AS, Chawla S, Wadhwa T, Gupta N. Disseminated *Trichosporon asahii* infection in a combined liver-kidney transplant recipient successfully treated with voriconazole. *Immun Inflamm Dis.* 2019;7(3):125-9.
11. Tanyildiz HG, Yesil S, Toprak S, Candir MO, Sahin G. Two Case Presentations Infected by *Trichosporon asahii* and Treated with Voriconazole Successfully. *Case Rep Infect Dis.* 2015;2015:651315.
12. Yilmaz Karapinar D, Karadas N, Onder Sivas Z, Yazici P, Duyu M, Metin D, Karapinar B, Aydinok Y. Rare severe mycotic infections in children receiving empirical caspofungin treatment for febrile neutropenia. *Braz J Infect Dis.* 2015;19(5):549-52.
13. Alothman AF, Althaqafi AO, Matar MJ, Moghnieh R, Alenazi TH, Farahat FM, Corman S, Solem CT, Raghubir N, Macahilig C, Charbonneau C, Stephens JM. Burden and treatment patterns of invasive fungal infections in hospitalized patients in the Middle East: real-world data from Saudi Arabia and Lebanon. *Infect Drug Resist.* 2017;10:35-41.
14. Armstrong-James D, Koh M, Ostermann M, Cockwell P. Optimal management of acute kidney injury in critically ill patients with invasive fungal infections being treated with liposomal amphotericin B. *BMJ Case Rep.* 2020;13(5).
15. Mishra P, Agrawal N, Bhurani D, Agarwal NB. Invasive Fungal Infections in Patients with Acute Myeloid Leukemia Undergoing Intensive Chemotherapy. *Indian J Hematol Blood Transfus.* 2020;36(1):64-70.
16. Bhatt VR, Viola GM, Ferrajoli A. Invasive fungal infections in acute leukemia. *Therapeutic advances in hematology.* 2011;2(4):231-47.
17. Apostolopoulou E, Raftopoulos V, Terzis K, Elefsiniotis I. Infection Probability Score, APACHE II and KARNOFSKY scoring systems as predictors of bloodstream infection onset in hematology-oncology patients. *BMC Infect Dis.* 2010;10:135.
18. Yao JF, Li N, Jiang J. Clinical Characteristics of Bloodstream Infections in Pediatric Acute Leukemia: A Single-center Experience with 231 Patients. *Chin Med J (Engl).* 2017;130(17):2076-81.
19. Arendrup MC, Boekhout T, Akova M, Meis JF, Cornely OA, Lortholary O, European Society of Clinical M, Infectious Diseases Fungal Infection Study G, European Confederation of Medical M. ESCMID and ECMM joint clinical guidelines for the diagnosis and management of rare invasive yeast infections. *Clin Microbiol Infect.* 2014;20 Suppl 3:76-98.
20. Chandrasekar P. Diagnostic challenges and recent advances in the early management of invasive fungal infections. *Eur J Haematol.* 2010;84(4):281-90.
21. Fournier S, Pavageau W, Feuillhade M, Deplus S, Zagdanski AM, Verola O, Dombret H, Molina JM. Use of voriconazole to successfully treat disseminated *Trichosporon asahii* infection in a patient with acute myeloid leukaemia. *Eur J Clin Microbiol Infect Dis.* 2002;21(12):892-6.
22. Go SE, Lee KJ, Kim Y, Choi JK, Kim YJ, Lee DG. Catheter-Related *Trichosporon asahii* Bloodstream Infection in a Neutropenic Patient with Myelodysplastic Syndrome. *Infect Chemother.* 2018;50(2):138-43.
23. Karigane D, Sakurai M, Matsuyama E, Ide K, Yamamoto-Takeuchi S, Inazumi T, Kohashi S. Successful treatment of

---

breakthrough disseminated *Trichosporon asahii* fungemia in a patient with acute myeloid leukemia receiving itraconazole prophylaxis. *Med Mycol Case Rep.* 2018;20:1-3.

24.Lee KH, Lim YT, Hah JO, Kim YK, Lee CH, Lee JM. Voriconazole plus caspofungin

for treatment of invasive fungal infection in children with acute leukemia. *Blood Res.* 2017;52(3):167-73.