Ectopic Adrenocortical Tissue in the Spermatic Cord in Association with Testicular Torsion in a One-Month-Old infant:Case report

Alireza Rastgoo[1], Nastaran Mahmoudnejad[2], Mohammad Amin Fereiduni[3], Mehrdad Taghipour[4*], Lotfollah Davoudi[5], Reza Maleki Gorji[5]

1Assistant professor of pathology, Hamadan University of Medical Sciences, Hamadan, Iran

2Urologist, Hamadan University of Medical Sciences, Hamadan, Iran

3Student Research Committee, Hamadan University of Medical Sciences, Hamadan, Iran

4Cancer research center, Student Research Committee, Mazandaran University of Medical Sciences, Sari, Iran

5Resident of infectious disease, Mazandaran University of Medical Sciences, Sari, Iran

Corresponding author
Mehrdad Taghipour, Student Research Committee, Mazandaran University of Medical Sciences, Sari, Iran
Email: mehrdadtaghipour@gmail.com

Abstract: Ectopic adrenocortical tissue is a clinical finding which has been reported in various locations, such as kidney, female genital tract and supradiaphragmatic region. It is occasionally seen in spermatic cord of pediatrics specially. The simultaneous occurrence with testicular torsion has not been reported. Here we describe a one-month old infant with ectopic adrenocortical tissue in spermatic cord in association with testicular torsion.
Keywords: : Adrenal glands, Ectopic tissue, spermatic cord, Testicular Torsion

1. Introduction

Ectopic adrenal tissue along the spermatic cord is a rare diagnosis in childhood. Morgagni´s first described in 1740, overall incidence in different studies varies from 1% to 9.3% of the patients who underwent groin surgical explorations and most of them in pediatric patients [1, 2]. Adrenal cortex rests may undergo hyperplasia in patients with increased adrenocorticotropic hormone ACTH production and potentially malignant neoplasm [3, 4, 5].

In this study we present an incidental finding of ectopic adrenal tissue in a one month old boy who underwent inguinal region exploration due to cryptorchidism and severe tenderness at the same site**.**

2. Case Report

A one month old baby boy was referred to our medical center complaining of a tender, right inguinal mass. On physical examination, the right testis was not palpated in its proper place Right undescended testis and there was a severely tender mass located at a right inguinal region. An ultrasound study revealed a 10x15 mm hypoechoic mass with decreased blood flow consistent with testicular torsion. The patient underwent surgical exploration of the right inguinal region through an oblique inguinal incision. Unfortunately the undescended testis was necrotic and we could not save it, so a standard inguinal orchiectomy was performed. An incidental finding at the time of surgery was a tiny yellowish soft nodule lying at the anterior aspect of the spermatic cord. The lesion was excised totally along with the spermatic cord and sent for pathologic evaluation.

3.Pathologic Findings:

Pathologic examination of the orchiectomy specimen revealed a bright-yellowish soft nodule located along the spermatic cord. Histological sections of the excised nodule showed adrenal cortical tissue consisting of three layers of the adrenal cortex glomerulosa, fasciculata and reticularis. There was no clearly defined medullary tissue in the specimen. A histologic section of testicular tissue revealed seminiferous tubules with immature appearance and massive hemorrhagic areas in the interstitium

4. Discussions

The ectopic adrenal tissue is generally identified along the pathway of descent of the testis at the time of surgical exploration in the treatment of cryptorchidism [6, 7]. Ectopic adrenal has also been observed rarely at distant sites such as the lung, liver, brain, ovary, and placenta, colon, pancreas and retroperitoneum [8, 9, 10]. In 1740, Morgagni´s first described yellowish nodules resembling adrenal tissue adjacent to the main glands 1. The incidence of the disease is lower in girls [11, 12]. It is generally accepted that these adrenal rests were due to mechanical separation and displacement of portions of cortical tissue during migration and descent of the

sex glands in the male embryonic development [12, 13, 14]. Microscopically, they are comprised of adrenal cortical tissue, predominate the fasciculate and glomerulosa without adrenal medullary tissue. There have been some reports of ectopic adrenal tissues in autopsies usually located underneath the capsule of the kidney [15, 16, 17]. Adrenal heterotopias are benign non-neoplastic lesion. There have been reports of development of malignant disease in the ectopic adrenal cells [18, 19, 20].

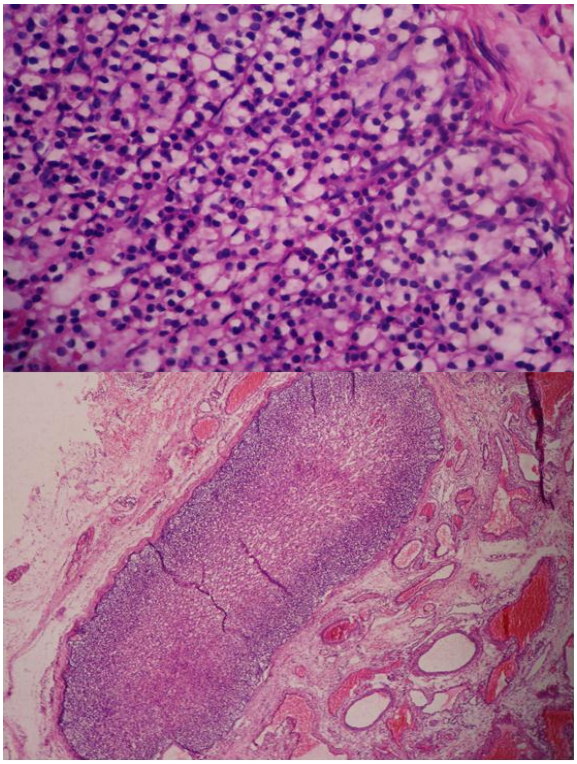

Figure1: seminiferous tubules with immature appearance and massive hemorrhagic areas in the interstitium

5.Conclusion

We believe that it is important for all urologists to keep in mind the possibility that a nodule around the spermatic cord may be ectopic adrenal tissue and it is reasonable to excise this nodule without jeopardizing the viability of the spermatic cord structures. Pathologic evaluation of any suspicious lesion is highly recommended.

References

1. Ren PT, Fu H, He XW. Ectopic adrenal cortical adenoma in the gastric wall: case report. World J Gastroenterol. 2013 Feb 7; 19 (5):778-80

2. Moore KL, Persaud TVN. The Urogenital System. Before we are born. Essentials of Embryology and Birth Defects 1998; 289-327.

3. Mares AJ, Shkolnik A, Sacks M, Feuchtwanger MM. Aberrant ectopic adrenocortical tissue along the spermatic cord. J Pediatric Surg 1980; 15:289-292.

4. Mauro Mari, Eugenio Cagnazzi, Enrico Bollito, et al. Ectopic adrenal cortex tissue
In the spermatic cord in association with testicular cancer. Urol Int 2004; 73:191-192

5. Jonathan G. Sullivan, Manj Gohel, Richard B. Kinder. Ectopic adrenocortical
Tissue found at groin exploration in children: incidence in relation to diagnosis, age and sex. BJU Int 2005; 95, 407-410

6. Altın MA, Hülya Gündoğdu Z, Aksoy.Adrenal rests in the inguinal region in
Children. Pediatric Surg Int 1992; 7: 446-8

7. Okur H, Küçükaydın M, Kazez A, Konta O.Ectopic adrenal tissue in the inguinal region in children. Pediatr Pathol Lab Med 1995;15: 763-67**.**

8. Roberto Mendez, Manuel G. Tellado, Ivan Somoza. Ectopic Adrenal Tissue in the Spermatic Cord in Pediatric Patients. Pediatric urology 2006;32:202-207

9.Mari M, Cagnazzi E, Bollito E, Bellina M: Ectopic adrenal cortex tissue in the spermatic cord in association with testicular cancer. Urol Int. 2004; 73: 191-2.

10.Sullivan JG, Gohel M, Kinder RB: Ectopic adrenocortical tissue found at groin exploration in children: incidence in relation to diagnosis, age and sex. BJU Int.
2005; 95: 407-10.

11. Anderson JR, Ross AH: Ectopic adrenal tissue in adults. Postgrad Med J. 1980; 56: 806-8.

12. O´Crowley CR, Martland HS: Adrenal heterotopia rests and so-called Grawitz tumors. J Urol. 1943; 50: 756-68.

13**.** Vaos G, Zavras N, Boukouvalea I. Ectopic adrenocortical tissue along the inguinoscrotal path of children. Int Surg. 2006 May-Jun; 91(3):125-8.

14. Nelson AA: Accessory adrenal cortical tissue. Arch Pathol 1939; 27: 955-9.

15. Delmas V, Dauge MC: Accessory adrenals in the spermatic cord. Apropos of 2 cases. Ann Urol Paris. 1986;20: 261-4.

16.Benvenuti S, Sepich CA, Cecchi M, Castagna M,Viacava P, Fiorentini L: Peri-deferential ectopic adrenal gland. Apropos of a case. J Urol Paris. 1991; 97:107-8.

17. Roggia A, Marandola P, Broggini P, Bono P, de Francesco O, Rovati L: Ectopic adrenal cortex tissue in the spermatic cord: clinico-surgical implications. Arch Esp Urol. 1991; 44: 1165-6.
18. Gualtieri T, Segal AD: Case of adrenal type tumor of spermatic cord. J Urol.1949; 61: 949-5.
19. Ventura L, Leocata P, Hind A, Greco I, Ventura T:Ectopic adrenal tissue in the spermatic cord. Case report and review of the literature. Arch Ital Urol Androl.
1998; 70: 15-8.
20. Vela Navarrete R, Barat A, Berrocal A, Lopez de Alda A, Quezada F: Testicular adrenal rests tumor: a difficult diagnosis. Actas Urol Esp. 1990; 14: 146-8.