

Case Report

Morgagni Herniation Tion In A 73-Year-Old Woman: A Case Report

Reza Afghani¹, Saeed Amirkhanlu², Hamed Jafarpour³, Arash Rezaei Shahmirzadi⁴, Tahere Bakhshi⁵

1. Professor of thoracic, Faculty of Medicine, Golestan University of Medical Sciences, Golestan, Iran.
2. Department of Nephrology, Clinical Research Development Unit (CRDU), Sayad Shirazi hospital, Golestan University of Medical Sciences, Gorgan, Iran
3. Medical Student, Student Research Committee, Faculty of Medicine, Mazandaran University of Medical Sciences, Sari, Iran.
4. Medical Student, Student Research Committee, Faculty of Medicine, Golestan University of Medical Sciences, Golestan, Iran.
5. . Student Research Committee, Faculty of ParaMedicine, Golestan University of Medical Sciences, Golestan, Iran.

Correspondence: **Tahere Bakhshi**, Student Research Committee, Faculty of ParaMedicine, Golestan University of Medical Sciences, Golestan, Iran. Taherebakhshi73@gmail.com

ABSTRACT

Introduction: The majority of adult diaphragmatic herniation s is due to a chronic hiatal hernia or caused by a diaphragmatic herniation. Compared to other different forms of congenital herniation s, Morgagni herniation s are relatively rare. Here we introduce a case of a 73-year-old woman diagnosed with Morgagni Herniation and the choice of treatment used for the patient.

Case report: The patient, a 73-year-old woman, presented with abdominal pain with the onset of 10 days prior to her visit. In the chest x-ray silhouette sign on the right side border of the heart was seen that suggested a Morgagni herniation as our primary differential diagnosis. The patient was discharged 3 days after the operation.

Conclusion: Studies show that a Morgagni herniation should be a differential diagnosis for any patient that presents with unspecific abdominal pain or respiratory symptoms.

Keywords: Morgagni Herniation, Diaphragmatic Herniation, Hiatal hernia

Introduction

Any disturbance in the fusion point or muscularization of the anterior pleuroperitoneal fascia results in an anatomical defect in the costosternal trigone also known as the foramina of Morgagni (1).A Morgagni herniation is the rarest of the four possible forms of a congenital diaphragmatic herniation, including 2% to 3% of all the reported cases (2). Adults usually do not show any specific clinical manifestations and, most commonly present

with dyspepsia and excessive flatus (3).The sac formed in a Morgagni herniation is a true sac and, most commonly consists of the omentum alone; although colon and rarely even the intestines can be involved (4).

The diagnostic imaging of choice in these patients is a standing chest x-ray and for a definite diagnosis a CT-Scan. Here we introduce a case of a 73-year-old woman diagnosed with Morgagni Herniation and the choice of treatment used for the patient. A

laparotomy was the surgical procedure of choice for the patient. After separation of the adhesions, the contents of the herniation were relocated in the abdomen through the defect and then the defect itself was repaired.

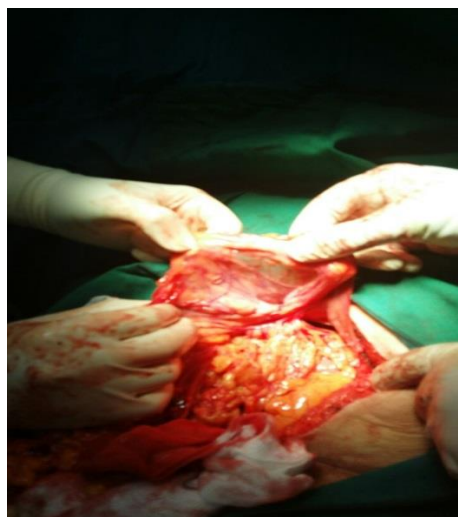
Case report:

The patient, a 73-year-old woman, presented with abdominal pain with the onset of 10 days prior to her visit. In her past medical records, a history of asthma and hypertension were noticeable, which was being treated with appropriate medication.

10 days before the patient's visit, she had also visited a private clinical center in which an ultrasound showing a Morgagni herniation was obtained, also the ultrasound had shown a defect in the anterior and middle region of the diaphragm that included fat and the transverse colon.

In the chest x-ray silhouette sign on the right side border of the heart was seen that suggested a Morgagni herniation as our primary differential diagnosis. The CT-Scan results supported our diagnosis.

Herniation sac and contents (during surgery)



The patient consented to be transferred from the private institution to the medical education center of Sayyad-Shirazi, Gorgan, to undergo surgery.

A laparotomy was the surgical procedure of choice for the patient. Using an under mid-line incision, we entered the abdominal cavity where the defect in the right anterior and midsection of the diaphragm was visible; which was in accordance with a Morgagni herniation in which the sac was filled with the omentum, fat, and part of the transverse colon. After separation of the adhesions, the contents of the herniation were relocated in the abdomen through the defect and then the defect itself was repaired and sutured with nylon 1.0 suture following dissection of the herniation sac.

The patient went through an uneventful postoperative recovery and was admitted to the ward. The patient was discharged 3 days after the operation.

Discussion

The majority of adult diaphragmatic herniations is due to a chronic hiatal hernia or caused by a diaphragmatic herniation. Compared to other different forms of congenital herniations, Morgagni herniations are relatively rare (2).

A Morgagni herniation was first defined by an Italian anatomist-pathologist who worked on expired patients whose cause of death was trauma to the head (3).

The exact mechanism of the herniation is an abnormal, congenital diaphragmatic opening caused by a fusion of the transverse septum and the curve of the ribs, which is quite rare (5). The formed opening is often small and includes a sac that usually contains the omentum, part of the transverse colon and,

less commonly, the liver, intestines and the stomach (6). In the presented case the sac contained the omentum and part of the transverse colon.

A great number of adult herniations are asymptomatic and are only discovered via x-ray imaging (7). Symptoms associated with a Morgagni herniation can be varied. Respiratory symptoms such as dyspnea, with or without a cough, are most commonly seen in these patients (8). In this case, the patient had a history of asthma for which she was taking medication. As mentioned previously, a definite diagnosis in these patients is only made using x-ray imaging and a CT-Scan; although should the results show an empty sac, making the diagnosis would become problematic. The treatment of choice for a Morgagni herniation is surgery and all patients should have an operation to repair the diaphragmatic defect; unless the patient has no symptoms, the sac only contains the omentum or the patients suffer from another underlying disease that can make an operation high-risk (9).

The surgical procedure includes the closure of the diaphragmatic opening either directly, using a trans-abdominal or a transthoracic approach (3). Or laparoscopically. The sac is visualized after pushing the abdominal organs aside. The opening can be closed using a non-absorbable suture. Following the operation using either surgical approach (Laparotomy or Laparoscopy) the patient will have a long recovery and will need extensive rehabilitation (1-3). In the presented case, nylon sutures were used and the patient was transferred to the post-op recovery room and was sent to the ward 3-hour post-surgery.

Conclusion:

Studies show that a Morgagni herniation should be a differential diagnosis for any patient that presents with unspecific abdominal pain or respiratory symptoms. Timely imaging can play an important role in early diagnosis of this condition. A successful treatment relies on making a correct diagnosis and choosing the appropriate surgical approach and technique.

References:

1. Shields TW. General thoracic surgery: Lippincott Williams & Wilkins; 2005.
2. Loong T, Kocher H. Clinical presentation and operative repair of hernia of Morgagni. *Postgraduate medical journal*. 2005;81(951):41-4.
3. Horton JD, Hofmann LJ, Hetz SP. Presentation and management of Morgagni hernias in adults: a review of 298 cases. *Surgical endoscopy*. 2008;22(6):1413-20.
4. Morgagni G. The seats and causes of diseases investigated by anatomy; in five books, containing a great variety of dissections, with remarks. To which are added very accurate and copious indexes of the principal things and names therein contained. Vol. 2: London, Printed for A. Millar, and T. Cadell, his successor [etc.]; 1769.
5. Angrisani L, Lorenzo M, Santoro T, Sodano A, Tesaro B. Hernia of foramen of Morgagni in adult: case report of laparoscopic repair. *JSLS: Journal of the Society of Laparoendoscopic Surgeons*. 2000;4(2):177.
6. Berman L, Stringer D, Ein SH, Shandling B. The late-presenting pediatric Morgagni hernia: a benign condition. *Journal of pediatric surgery*. 1989;24(10):970-2.
7. Groff DB. Diagnosis of a Morgagni hernia complicated by a previous normal chest X-ray. *Journal of pediatric surgery*. 1990;25(5):556-7.

8. Pfannschmidt J, Hoffmann H, Dienemann H. Morgagni hernia in adults: results in 7 patients. *Scandinavian Journal of Surgery*. 2004;93(1):77-81.
9. Kuster GG, Kline LE, Garzo G. Diaphragmatic hernia through the foramen

of Morgagni: laparoscopic repair case report. *Journal of laparoendoscopic surgery*. 1992;2(2):93-100.