

Original Research**Ovarian Ectopic Pregnancy in a Woman with a History of Frequent Abortions and Low β -hCG Levels**

Raheleh Baradaran^{1*}, Azamsadat Mahmoudian², Fereshteh Mohammadi³, Abbas Sadeghian¹

1. Operating Room Department, Allameh Bohlool Gonabadi Hospital, Gonabad University of Medical Sciences, Gonabad, Iran.

2. Department of Obstetrics and Gynecology, Faculty of Medicine, Gonabad University of Medical Sciences, Gonabad, Iran.

3. Pathology Department, Allameh Bohlool Gonabadi Hospital, Gonabad University of Medical Sciences, Gonabad, Iran.

***Corresponding Author: Raheleh Baradaran**, Operating Room Department, Allameh Bohlool Gonabadi Hospital, Gonabad University of Medical Sciences, Gonabad, Iran. E-mail: baradaranr941@mums.ac.ir, Number phone: 09153752044

Abstract:**Background:**

The ovarian ectopic pregnancy (OEP) is a rare complication in which the gestational sac is implanted inside the ovary tissue. There are few reports in the literature on OEPs following abortions. The present study aimed to report a case of OEP with frequent abortions and low β -hCG levels.

Case Presentation:

The patient in this study was a 29-year-old woman referred to a hospital with the complaint of abdominal pain and vomiting, and she had a history of five abortions. The patient's β -hCG level was low, and the results of the pelvic ultrasound showed a right adnexal mass with a dimension of 7×6 cm. Moreover, the uterus was seen with normal dimensions and there was no clear image of the pregnancy sac. Hemorrhagic fluid was also observed in the pelvic cavity, especially in the around right adnexa. Thereafter, the patient underwent a laparotomy, and after the suction of abdomen and pelvis blood, the surgeon noticed that the right ovary was torn with bleeding. During the surgery process, wedge resection and blood homeostasis were done. Thereafter, the samples of wedge resection were sent for histology assessments, and finally, the existence of placenta tissue in the adjacency of the ovary tissue confirmed OEP. The patient was discharged on day 3 after the surgery.

Conclusions:

This report aimed to inform surgeons of a rare complication, namely OEP happening with low β -hCG levels and following frequent abortions.

Keywords: Ovarian Ectopic Pregnancy, Miscarriage, Beta Human Chorionic Gonadotropin.

Introduction

The ovarian ectopic pregnancy (OEP) is one of the most critical gynecologic emergencies, in which the gestational sac is implanted inside the ovary tissue. Moreover, it is one of the rarest types of ectopic pregnancy (1), indicating 1–3% of all EP and the incidence rate of 1/7000–1/70000 from all the pregnancies (2, 3). However, the real incidence may be more than this because many cases of EP are treated without any known site while it may reveal an OEP. These are classified into primary and secondary OEP. Ovulation does not occur in the primary OEP, but fertilization and implantation occur into ovarian tissue. In secondary OEP after ovulation, fertilization occurs in the fallopian tube and the fetus then returns and is implanted into ovarian tissue (4, 5). Another dividing for OEP included intra-follicular and extra-follicular OEPs. In the intra-follicular, ovum is fertilized within an ovary follicle, while in the extra-follicular, ovum is fertilized within ovary tissue (6). The risk factors of OEP similar to tubal pregnancy include prior EP, pelvic infectious diseases (PIDs), salpingitis, endometriosis, infertility, spontaneous or induced abortion, assisted reproductive techniques (ARTs), use of intrauterine contraceptive devices (IUCDs) (1, 7–11).

The maximum duration of OEP lasts for 4–6 weeks. In this situation, 75% of cases are ruptured in the first trimester and consequently cause internal bleeding and hypovolemic shock due to the excessive ovarian perfusion (12–14). The signs and symptoms of OEP are similar to tubal pregnancies and ruptured corpus luteal cysts, so it is difficult to diagnose regarding preoperative findings. In addition, its clinical symptoms include abdominal pain, amenorrhea, and vaginal hemorrhage. As well, definitive diagnoses are based on surgical and histopathological observations (15). The

purpose of this report was to inform surgeons and physicians about a rare case of OEP happening with low β -hCG levels and following frequent abortions.

Case Presentation

The patient in this study was a 29-year-old woman referred to the hospital with abdominal pain and vomiting. The patient's abdominal pain is persistent, which extends from the right flank to the hypogastric region. She has a history of five cases of abortion and infertility. The patient's β -hCG level was measured twice for the final confirmation of the pregnancy that showed (β -hCG = 503, 356 IU/L respectively) (β -hCG <1000 IU/L: not pregnant). The results of abdominal and pelvic ultrasound rejected acute appendicitis and the uterus were observed with normal dimensions and there was no clear image in favor of pregnancy. A right adnexal mass was seen with a dimension of 7×6 cm. As well, Hemorrhagic fluid was seen in the pelvic cavity with a medium volume, preferably in the right adnexa, especially around the ovary. Therefore, the patient underwent general anesthesia and laparotomy with a Pfannenstiel incision. After the suction of abdomen and pelvis blood, the surgeon noticed that the right ovary was torn with bleeding. However, she was suspected between hemorrhagic corpus luteum and OEP. The total amount of blood obtained from the suction indicated by the weight of bloody pads was 800 cc. During the surgery process, in order to maintain fertility and normal anatomy, wedge resection, cystectomy, curettage, and blood homeostasis were done by cauterization and suture. Afterward, the samples of wedge resection and intra-pelvic clots were sent for pathology and histology assessments. Histologically, the existence of placenta and trophoblast tissues in the adjacency of the ovary tissue confirmed OEP (Figure 1.). The postoperative course was uneventful in the follow-ups and the

patient was discharged on day 3 after the surgery.

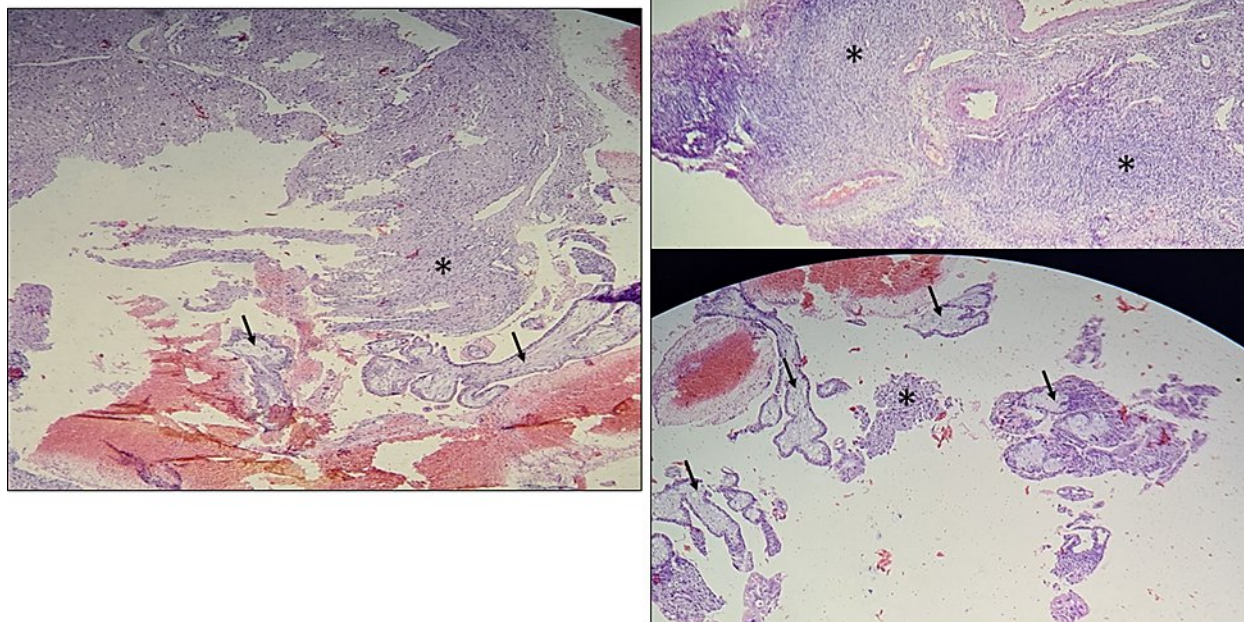


Fig 1. Histologic images of OEP. It shows placenta villi (arrows) adjacent to the ovarian tissue (*). Staining H&E.

Discussion

In this report, a case with ovarian ectopic pregnancy was presented who was a woman with frequent abortions and low β -hCG levels. To the best of our knowledge, only an alike case was reported in the literature who was a case of OEP with low β -hCG levels. Recently, it is reported that the OEPs incidence rate increased due to the increased risk factors, including sexually transmitted diseases, pelvic surgery, PIDs, endometriosis, infertility, spontaneous or induced abortions, ARTs, and IUCDs (8, 10, 16, 17). It is suggested that these risk factors can change tubal motility, thereby leading to the implantation in the ovary (18). The fallopian tubes provide the perfect environment for fertilization and oocyte or embryo transportation (19). Therefore, any disruption in the fallopian tubes can consequently lead to OEP. For example, inflammation can disturb

the endosalpinx ciliary activity, damage fallopian tube epithelial, delay ovum transport, and induce ectopic implantation (20, 21). Besides disturbing uterine tubal, several hypotheses are proposed for the causes of OEPs, including delay of the ovulation, thickened tunica albuginea, and damaged tubal epithelial (12).

In line with our case, several studies have previously shown that a history of spontaneous or induced abortion can induce OEP (9-11). Infection in the fallopian tube may occur following the endometrial curettage leading tube biological function to be seriously destroyed by inflammatory processes (22). Tsechoeva et al. in their prospective study have assessed reproductive disorders in patients with a history of infected abortion. Accordingly, they have stated that 76.7% female cases had reproductive disorders, 37.9% of them suffered from tubal

infertility, 41.4% from chronic endometritis, and 22.4% from thin endometrium (23). Based on our patient's history, recurrent miscarriages and curettage may have caused an ectopic pregnancy.

The signs and symptoms of OEP include pelvic and abdominal pain, vaginal hemorrhaging, and menstrual disorders. In examination, it was shown that the difference between OEP and tubal pregnancy is that OEP moves with the ovary, vice versa tubal pregnancy. However, it can be confused with ovarian tumors, chocolate cysts, and corpus luteal hemorrhage (24). For these cases, Sonography must be done to detect the precise position of an intraovarian mass. If ultrasound findings were accompanied by the increased β -hCG level, this can be considered as a good index for the OEP diagnosis. The characteristics OEPs in sonography/transvaginal ultrasonography (TV-US) include a vacant uterine; a gestational sac attached to ovarian tissue containing a fetal pole and yolk sac, occasionally with cardiac movements; an echogenic loop with an inner lucent region that the echogenicity of the loop is usually more than ovarian tissue; and an ovarian cortex consisting of the follicles or corpus luteum near the mass (10, 25, 26). In this regard, MRI can be known as an exact technique used for diagnosing pregnancy site and differentiating the position of rupture from non-rupture (27). During surgery, only 28 percent of OEPs are diagnosed, because they are confused with a hemorrhagic corpus luteum (28). However, the final diagnosis is determined by conducting histological assessments. The ovary can be adapted to developing pregnancy better than the tubes; however, 75 percent of OEPs are ruptured in the 1st trimester (29). While only 5.3 and 3.7 percent develop to the 2nd and 3rd trimesters, respectively (30). This rupture can lead to hemoperitoneum and then cause hypovolemia,

which is finally considered as a gynecological emergency.

Based on the latest criteria and by considering laboratory and TV-US results, preoperative diagnosis of OEP includes serum β -hCG concentration >1000 IU/L, lack of gestational sac by TV-US, the presence of chorionic villi and abnormal cysts on the ovary, ovarian involvement in the examination, healthy fallopian tubes, and the decreased serum β -hCG level after the treatment (31). These criteria are very important because this case is rare, and the late diagnosis and treatment cause the consequent complications and even lead to death.

In agreement with our study, Resta et al. in their study have reported a case of ruptured OEP and despite low levels of β -hCG (32), they acknowledged that low β -hCG levels may mislead the diagnosis of OEP.

Additionally, cases with decreased β -hCG levels have been reported in tubal rupture (33). In another study, Tehrani et al. have reported an OEP case with no rupture and slowly raised level of β -hCG (18). The low level of beta-HCG in our patient may probably be due to OEP rupture and the separation of the placenta from the ovarian tissue.

Conclusion

It is suggested that the surgeon should perform exact examinations and techniques such as MRI and TV-US, in order to detect the OEP in a timely manner. Only an ultrasound or β -hCG alone cannot show the OEP, because it may sometimes decrease due to ovarian rupture and placental separation.

Conflict of interest

There is no potential conflict of interest relevant to this article.

Ethical approval

The study was explained to the patient and performed in accordance with the principles of

the Declaration of Helsinki. Written informed consent was obtained.

Patient consent

The patient provided written informed consent for the publication and the use of her images.

References

1. Joseph R, Irvine L. Ovarian ectopic pregnancy: aetiology, diagnosis, and challenges in surgical management. *J Obstet Gynaecol.* 2012;32(5):472-4.
2. Raziel A, Schachter M, Mordechai E, Friedler S, Panski M, Ron-El R. Ovarian pregnancy-a 12-year experience of 19 cases in one institution. *EUR J OBSTET GYN R B.* 2004;114(1):92-6.
3. Gaudoin M, Coulter K, Robins A, Verghese A, Hanretty K. Is the incidence of ovarian ectopic pregnancy increasing? *EUR J OBSTET GYN R B.* 1996;70(2):141-3.
4. BeGum J, Pallavee P, Samal S. Diagnostic dilemma in ovarian pregnancy: a case series. *Journal of clinical and diagnostic research: JCDR.* 2015;9(4):QR01.
5. Lin EP, Bhatt S, Dogra VS. Diagnostic clues to ectopic pregnancy. *Radiographics.* 2008;28(6):1661-71.
6. Conner E, Huber 3rd W, Matteson K. Ovarian ectopic pregnancy contralateral to unicornuate uterus. *Clin Obstet Gynecol Reprod Med.* 2015;1(3):66-7.
7. Reichman J, Goldman J, Feldberg D. Ovarian Pregnancy: Association with IUD, Pelvic pathology and recurrent abortion. *EUR J OBSTET GYN R B.* 1981;12(6):333-7.
8. Dursun P, Gultekin M, Zeyneloglu HB. Ovarian ectopic pregnancy after ICSI-ET: a case report and literature review. *ARCH GYNECOL OBSTET.* 2008;278(2):191-3.
9. Goyal LD, Tondon R, Goel P, Sehgal A. Ovarian ectopic pregnancy: A 10 years' experience and review of literature. *IRAN J REPROD MED.* 2014;12(12):825.
10. Comstock C, Huston K, Lee W. The ultrasonographic appearance of ovarian ectopic pregnancies. *OBSTET GYNECOL.* 2005;105(1):42-5.
11. Ghi T, Banfi A, Marconi R, Iaco P, Pilu G, Aloysio D, et al. Three-dimensional sonographic diagnosis of ovarian pregnancy. *Ultrasound in Obstetrics and Gynecology: Journal of the International Society of Ultrasound in Obstetrics and Gynecology.* 2005;26(1):102-4.
12. Birge O, Erkan MM, Ozbey EG, Arslan D. Medical management of an ovarian ectopic pregnancy: a case report. *Journal of Medical Case Reports.* 2015;9(1):1-4.
13. Shrestha A, Chawla C, Shrestha R. Ruptured primary ovarian pregnancy: a rare case report. *Kathmandu University Medical Journal.* 2012;10(3):76-7.
14. Szadok P, Kubiacyk F, Bajorek A, Suchocki S. Ovarian ectopic pregnancy. *Ginekologia polska.* 2019;90(12):728-.
15. Scutiero G, Di Gioia P, Spada A, Greco P. Primary ovarian pregnancy and its management. *JSLS: Journal of the Society of Laparoendoscopic Surgeons.* 2012;16(3):492.
16. Roy J, Babu AS. Ovarian pregnancy: Two case reports. *The Australasian medical journal.* 2013;6(8):406.
17. Melcer Y, Smorgick N, Vaknin Z, Mendlovic S, Raziel A, Maymon R. Primary Ovarian Pregnancy: 43 Years Experience in a Single Institute and still a Medical Challenge. *The Israel Medical Association Journal: IMAJ.* 2015;17(11):687-90.
18. Tehrani HG, Hamoush Z, Ghasemi M, Hashemi L. Ovarian ectopic pregnancy: A rare case. *IRAN J REPROD MED.* 2014;12(4):281.
19. Ezzati M, Djahanbakhch O, Arian S, Carr BR. Tubal transport of gametes and embryos: a review of physiology and pathophysiology. *J ASSIST REPROD GEN.* 2014;31(10):1337-47.
20. Herbertsson G, Magnusson SS, Benediktsdottir K. Ovarian pregnancy and

- IUCD use in a defined complete population. *Acta obstetricia et gynecologica Scandinavica*. 1987;66(7):607-10.
21. Berger B, Blechner JN. Ovarian pregnancy associated with copper-7 intrauterine device. *ACTA OBSTET GYN SCAN*. 1978;52(5):597-600.
22. Wheeler JE. Pathology of the fallopian tube. *Pathology of the female genital tract*: Springer; 1982. p. 393-415.
23. TSECHOEVA LS, RUKHLIADA NN. Reproductive health in patients with history of infected abortion. *Global Reproduction*. 2019(1):22-7.
24. C C. Ectopic pregnancy: a pictorial review. *Clinical Imaging*. 2008;32(6):468-73.
25. Chang FW CC, Liu JY. Early diagnosis of ovarian pregnancy by ultrasound. *INT J GYNECOL OBSTET*. 2004;85(2):186-7.
26. Roy J BA. Ovarian pregnancy: Two case reports. *The Australasian medical journal*. 2013;6(8):406.
27. Srisajjakul S PP, Bangchokdee S. Magnetic resonance imaging in tubal and non-tubal ectopic pregnancy. *European journal of radiology*. 2017;93:76-89.
28. Ciortea R CN, Chiroiu B, Mălutan A, Mocan R, Hudacsko A, et al. Ovarian pregnancy associated with pelvic adhesions. *Clujul Medical*. 2013;86(1):77.
29. JG H. Primary ovarian pregnancy: a report of twenty-five cases. *AM J OBSTET GYNECOL*. 1982;143(1):55-60.
30. Mathur SK PP, Gupta P, Kumar M, Gilotra M, Bhatia Y. Ruptured primary ovarian ectopic pregnancy: Case report and review of the literature. *J GYNECOL SURG*. 2015;31(6):354-6.
31. Sergent F M-TF, Gravier A, Verspyck E, Marpeau L. Ovarian pregnancies: revaluation of diagnostic criteria. *J GYNECOL OBST BIO R*. 2002;31(8):741-6.
32. Resta S FE, D'Itri F, Evangelista S, Ticino A, Porpora MG. Rupture of ovarian pregnancy in a woman with low beta-HCG levels. *Case reports in obstetrics and gynecology*. 2012.
33. Brennan DF KS, Kelly M, Dunn M. Chronic ectopic pregnancy—two cases of acute rupture despite negative β hCG. *J EMERG MED*. 2000;19(3):249-54.